

Cat-Transmitted Sporotrichosis Epidemic in Rio de Janeiro, Brazil: Description of a Series of Cases

Mônica Bastos de Lima Barros,¹ Armando de Oliveira Schubach,² Antônio Carlos Francesconi do Valle,¹ Maria Clara Gutierrez Galhardo,¹ Fátima Conceição-Silva,⁴ Tânia Maria Pacheco Schubach,² Rosani Santos Reis,³ Bodo Wanke,³ Keyla Belizia Feldman Marzochi,¹ and Maria José Conceição⁵

¹Serviço de Infectologia, ²Serviço de Zoonoses, and ³Serviço de Micologia, Instituto de Pesquisa Clínica Evandro Chagas, Fundação Oswaldo Cruz (Fiocruz), and ⁴Departamento de Imunologia, Instituto Oswaldo Cruz, Fiocruz, and ⁵Serviço de Doenças Infecciosas do Hospital Universitário Clementino Fraga Filho, Universidade Federal do Rio de Janeiro and Departamento de Medicina Tropical, Instituto Oswaldo Cruz, Rio de Janeiro, Brazil

Sporotrichosis is the most common subcutaneous mycosis in South America. Classic infection is associated with traumatic inoculation of soil, vegetables, and organic matter contaminated with *Sporothrix schenckii*. Zoonotic transmission has been described in isolated cases or in small outbreaks. Since 1998, we have been observing an increasing number of cases of sporotrichosis in persons from the city of Rio de Janeiro, Brazil, and surroundings. From 1998 to 2001, 178 cases of culture-proven sporotrichosis had been diagnosed. Female patients predominated, and the median age was 39 years. The most frequent clinical presentation was lymphocutaneous disease. Of the 178 patients, 156 reported domiciliary or professional contact with cats with sporotrichosis, and 97 of these patients had a history of receipt of cat scratch or bite. The patients received itraconazole as first-line treatment. This study suggests that feline transmission of sporotrichosis was associated with a large and long-lasting outbreak of the disease in Rio de Janeiro.

Sporotrichosis, caused by the dimorphic fungus *Sporothrix schenckii*, is currently distributed all over the world, especially in tropical and subtropical zones. It is the most common subcutaneous mycosis in South America [1]. Soon after it was first described by Schenck in the United States in 1898 [2], the disease was reported more frequently in the United States, the Far East, and Europe, especially in France. The major known areas of current endemicity are in Japan and in North and South America, especially Mexico, Brazil, Uruguay, Peru, and Colombia [1, 3–5]. Outbreaks of infection related to forest work and gardening have been reported in the United States [6].

The largest epidemic described occurred in Witwatersrand, South Africa, in the 1940s, when ~3000 miners were infected during their occupational activities [7]. Large epidemics, when they occur, are related to a single source of infection [8, 9]. Classic infection is associated with traumatic inoculation of soil, vegetables, or organic matter contaminated with the fungus. Zoonotic transmission has been reported in isolated cases or in small outbreaks in which armadillos and cats are the animals most frequently involved [10–15]. A large number of cases in humans related to armadillo hunting (especially cases associated with manipulation of the burrows of these animals and scratches inflicted by them) have been reported in Uruguay [1, 16, 17]. Cats with sporotrichosis usually develop lesions rich in parasites, often with severe signs and symptoms and progression to death [18]. Other animals have been reported to be possible transmitters of the disease, although without a significant zoonotic potential.

In Brazil, Lutz and Splendore [19] described the first cases of naturally acquired sporotrichosis in men and rats. Since then, isolated cases, small outbreaks, and

Received 3 July 2003; accepted 16 October 2003; electronically published 29 January 2004.

Reprints or correspondence: Dr. Mônica Bastos de Lima Barros, Instituto de Pesquisa Clínica Evandro Chagas, Fundação Oswaldo Cruz, Av. Brasil 4365, Mangueiras, Rio de Janeiro, Brazil, CEP 21045-900 (monica@ipecc.fiocruz.br).

Clinical Infectious Diseases 2004;38:529–35

© 2004 by the Infectious Diseases Society of America. All rights reserved.
1058-4838/2004/3804-0010\$15.00

case series have been sporadically reported [11, 20–27].

Since 1998, the sector of Infectious Diseases in Dermatology and the Zoonosis Service of the Instituto de Pesquisa Clínica Evandro Chagas (IPEC), Fundação Oswaldo Cruz (Fiocruz), Rio de Janeiro, Brazil, have been following up an increasing number of human and feline cases coming from the city of Rio de Janeiro and surroundings [18, 28–31]. In this report, we present the clinical and epidemiological data for 178 patients with culture-proven sporotrichosis treated during the period of 1998–2001, which thus far represents the largest epidemic of this mycosis in the form of a zoonosis.

PATIENTS, MATERIALS, AND METHODS

Appropriate informed consent was obtained for all patients, and the guidelines for human experimentation of the National Health Council (Brasília, Brazil) were followed in the conduct of clinical research. The study was approved by the Research Ethics Committee of Fiocruz. Fiocruz is linked to the Brazilian Ministry of Health and develops actions in the area of science and technology in health. All patients were treated at the Infectious Diseases Outpatient Clinic of IPEC. IPEC is a research center affiliated with Fiocruz that is active in the area of infectious and parasitic diseases, including research, teaching, and assistance. It acts as a national, state, and local reference center for diagnosis of mycoses.

After signing an informed consent form, the patients underwent clinical evaluation, and material from the lesions was obtained for mycological examination. Routinely performed laboratory tests were fasting serum chemistry (i.e., determination of glucose, cholesterol, triglyceride, creatinine, urea, aspartate aminotransferase, alanine aminotransferase, γ -glutamyl transferase, alkaline phosphatase, and lipase levels) and hematological tests. Other examinations, such as chest and joint radiography and serological testing, were performed when indicated. The isolation of *S. schenckii* from exudates or from fragments of lesions obtained from the patients was used as the criterion for inclusion in the study.

The following biological samples were obtained on the basis of clinical condition, type of lesion, and availability at the time of the study: surface secretion, which was obtained with a swab from exudative lesions or draining tracts; purulent or seropurulent content, which was aspirated from nonulcerated gummy lesions; and biopsy specimens, which were obtained from the borders of active lesions. The biopsy specimens were divided into 2 fragments: one was fixed in 10% buffered formalin, embedded in paraffin, and stained with hematoxylin-eosin, Wade, periodic acid–Schiff, and Grocott stains for histopathological examination; and the other was kept in sterile saline, triturated, and then submitted for mycological examination.

All samples underwent routine mycological examination, which involved direct microscopy of wet mount preparations with 4% sodium hydroxide and seeding onto Sabouraud dextrose agar and mycobiotic agar (Difco), incubation at 25°C, and observation for 4 weeks for fungal growth. Suspected isolates were subcultivated on potato dextrose agar medium (Difco) at 25°C for macroscopic and microscopic morphological studies, and dimorphism was demonstrated by conversion to the yeast-like form on BHI agar medium (Difco) at 37°C.

Itraconazole, administered orally at a dosage of 100 mg/day for a period of 90 days, was the first-choice treatment schedule for all patients [14].

All the data were collected by review of medical charts and were recorded on a standardized case report form. These data included information concerning residence, demographic characteristics, duration of symptoms, occupational and other exposure risk factors, history of trauma, clinical findings, associated diseases, laboratory diagnosis and complementary test results, treatment schedule, response to therapy, and any other pertinent data.

RESULTS

Patient series. One hundred seventy-eight cases of sporotrichosis were diagnosed during the period of 1998–2001. Figure 1 illustrates the increase in the number of cases per year, starting in 1998.

Most of these cases came from the municipalities of Rio de Janeiro (74 cases [42%]), Duque de Caxias (47 cases [26%]), and São João de Meriti (18 cases [10%]). In the municipality of Rio de Janeiro, the highest percentage of cases occurred in neighborhoods that bordered other municipalities (figure 2).

One hundred forty-one patients were from 141 distinct addresses. The remaining 37 patients were from 18 distinct ad-

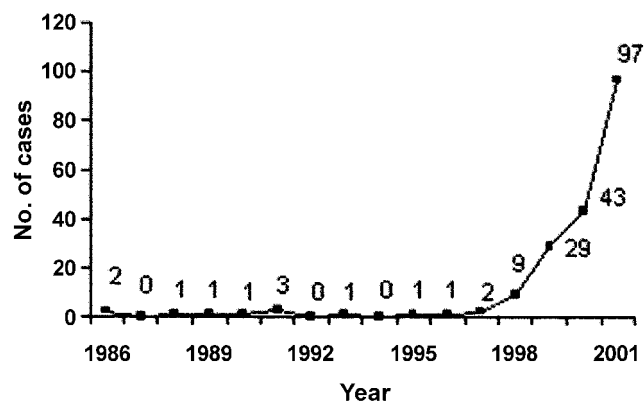


Figure 1. Number of cases of sporotrichosis diagnosed at Instituto de Pesquisa Clínica Evandro Chagas (Rio de Janeiro), 1998–2001.

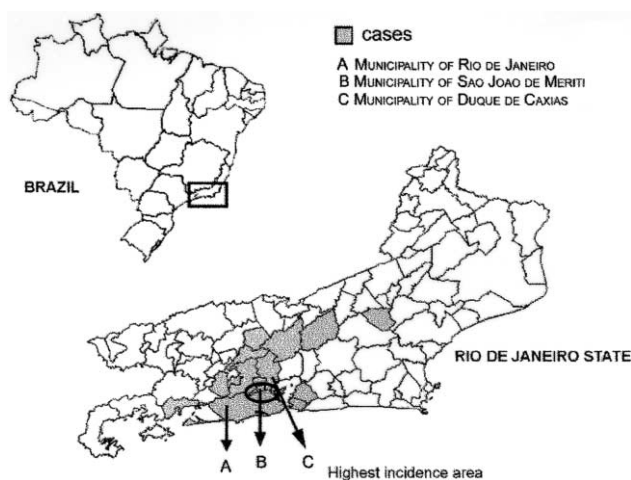


Figure 2. Map of the state of Rio de Janeiro. The municipalities with human cases of sporotrichosis are highlighted.

dresses (2 patients each in the same household for 17 addresses, and 3 patients each in the same household for 1 address).

Case distribution by age range and sex. The age range was 5–89 years, with a median of 39 years. Most patients (70.8%) were adults, followed in proportion by children and adolescents and patients aged >60 years (15.7% and 13.5%, respectively). Except among children aged <10 years, there was a predominance of women (68%) in all patients groups, especially among those aged >40 years, with a ratio of male to female patients of 1:2.9 (figure 3).

Occupation. Domestic activities constituted the most common occupation (30%); the second-largest occupation group was students (18%), most of whom were adults. The remaining categories (administrative assistant, sales person, seamstress, driver, general service provider, lawyer, and other) each constituted <7% of the cohort. Five percent of the patients were veterinarians, and 2% were rural workers.

Transmission. Of the 178 patients studied, 6 did not report any condition or risk factor to explain the transmission of disease. One hundred fifty-six (90.7%) of 172 patients were in domiciliary or professional contact with cats with sporotrichosis, and 111 (64.5%) reported experiencing a traumatic injury that preceded the symptoms, consisting of receipt of scratches or bites from cats with sporotrichosis for 97 (87.4%) of the 111 patients (figure 4). Sixty-one (35.5%) of 172 patients denied experiencing a traumatic injury before the onset of the disease, but 51 (83.6%) of these 61 patients had been in close contact with cats with sporotrichosis. A small proportion of patients (14 [8.2%] of 172) who had contact with sick cats also reported other possible risk factors for the acquisition of sporotrichosis (figure 5).

These cats are part of a feline sporotrichosis epidemic, and all of them were treated at the Evandro Chagas Clinical Research

Institute. Diagnoses were made by isolation of *S. schenckii* on culture [18, 29].

Clinical presentation. Ninety-nine patients (55.6%) presented with the lymphocutaneous form of disease, and 45 (25.3%) presented with the localized cutaneous form. Five patients (2.8%) presented with mucosal involvement (nasal fossa involvement in 1 patient and conjunctiva involvement in 4). Twenty-nine patients (16.3%) presented with widespread cutaneous lesions [18]. The morphological characteristics of the lesions varied: there were nodules, tubercles, pustules, cysts, gummy lesions, ulcers, ulcerovegetative lesions, and verrucose lesions and plaques, with or without lymphangitis.

The number of lesions ranged from 1 (30 patients [17.4%]) to >50 (median, 7 lesions), and the duration of symptoms before medical attention was sought was 1–108 weeks (median, 4 weeks). The interval between the onset of disease and the time that medical care was sought at IPEC markedly reduced over time: in 1998, only 20% of the patients presented with an interval of <4 weeks, whereas, in 2001, the proportion increased to 60%.

The lesions were more frequent on the upper limbs (116 [65.2%] of 178 patients) and were occasionally bilateral (15 [12.9%] of 116), followed in prevalence by the lower limbs (23 [12.9%] of 178) and the face (11 [6.2%] of 178). Other locations were observed in 28 patients (15.7%).

Fifty-three patients (29.8%) noted arthralgia as an associated symptom, 5 (9.4%) of whom presented with signs of arthritis. Eight patients presented with erythema nodosum [32], and 2 presented with erythema multiforme.

Laboratory diagnosis and complementary test results. The etiological diagnosis was made by isolating the fungus from secretions or from biopsy samples of the lesions. A total of 149 samples of exudates of ulcerated lesions or aspirates of closed lesions were obtained from 178 patients. Ninety-six patients underwent biopsies.

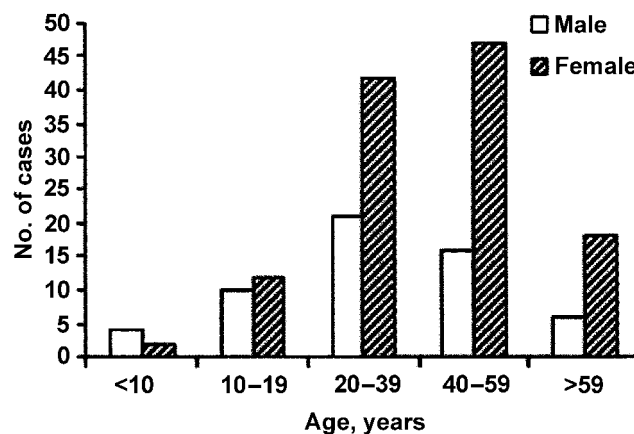


Figure 3. Age and sex distribution of cases of sporotrichosis, 1998–2001.

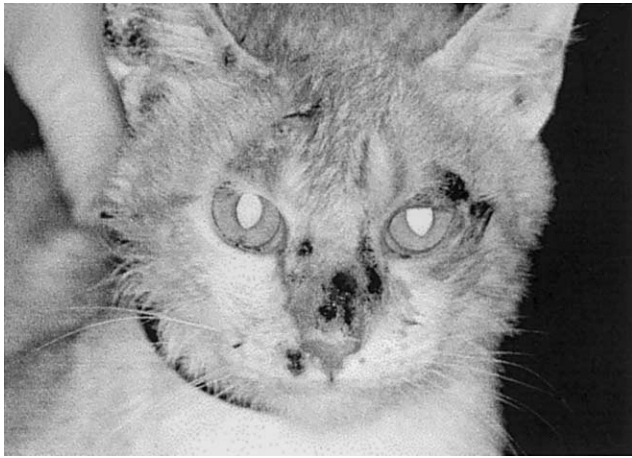

Figure 4. Cat with sporotrichosis presenting with multiple lesions on the face.

The results of direct mycological examination were positive for 4 (1.6%) of the 245 samples tested, including secretions and tissue fragments. *S. schenckii* was isolated from 141 (94.6%) of 149 exudates and 87 (90.6%) of 96 biopsy specimens. Histopathological examination of 73 biopsy specimens revealed granulomatous infiltrate in 66 (90.4%) and a nonspecific chronic inflammatory process in 7 (9.6%). The fungus was visualized in 21 (28.8%) of these fragments.

The erythrocyte sedimentation rate was noted to be elevated in 75 (63.0%) of 119 examinations performed before treatment was started. Radiography of the joints, which was performed for 34 patients with arthralgia, revealed soft-tissue swelling in 5 patients. Other changes observed in complementary examinations were due to comorbidities.

Treatment and follow-up. Of the 178 patients, 13 (7.3%) had spontaneous regression of the lesions, and 165 (92.7%) started specific treatment. One hundred forty-nine (90.3%) of 165 patients were cured, and 16 (9.7%) were lost to follow-up.

In the cases of spontaneous regression, regression occurred 6–20 weeks after the onset of disease and 4–12 weeks after diagnosis. Of the 149 patients treated, 133 received itraconazole at 100 mg/day, 8 required a dosage increase to 400 mg/day, 7 received other antifungal agents (potassium iodide, ketoconazole, fluconazole, and/or amphotericin B) in addition to itraconazole, and 1 pregnant patient underwent only heat therapy. Treatment duration ranged from 4 to 36 weeks (median, 12 weeks) for all treatment schedules.

Five patients were hospitalized: 1 was hospitalized for diabetes, 1 was hospitalized for concomitant cellulitis, 1 was hospitalized for an extensive vascular ulcer from which *S. schenckii* was isolated, and the last 2 were hospitalized for multiple skin lesions. In 1 of the 2 latter patients, new cystic lesions continued to occur after 6 months of treatment with itraconazole (400 mg q.d.). This patient presented with a positive Venereal Disease

Research Laboratory test result of 1:64 and was cured after treatment of syphilis and curettage of the lesions. The first of these 5 patients neglected follow-up after hospitalization, but the remaining 4 were cured.

All the patients were followed up for 6 months to 1 year after the end of therapy, and many of them remained in contact with sick cats. Only 2 patients were treated again: one was re-treated after abandoning the initial treatment, and the other was treated for reactivation of the disease. Both were cured after re-treatment for ~16 weeks.

Associated diseases. Nine patients were diabetic. For 5 of them, the duration of treatment was 16–24 weeks, and 3 patients required higher doses of itraconazole (200–400 mg q.d.). Four other patients with chronic obstructive pulmonary disease, 10 patients with arterial hypertension, and 9 alcoholic patients had a satisfactory response to treatment with itraconazole (100 mg q.d.), although, in the latter group, 1 patient presented with widespread skin lesions. One patient receiving treatment for multidrug-resistant tuberculosis presented with a single skin lesion, which regressed spontaneously. No other associated disease was detected.

DISCUSSION

Since the 1980s, the zoonotic transmission of sporotrichosis has been mentioned in different reports, mostly about small domiciliary outbreaks involving animals, their owners, and/or veterinarians [10–12, 27]. Before 1998, on average, 1.2 cases of human sporotrichosis were treated per year at IPEC. Starting in 1998, the number of cases increased progressively in such a way that the cumulative number during the 1998–2001 period was 178 cases, most of which involved contact with a domestic cat with sporotrichosis as the risk factor, as was previously documented by our group [28–30]. In parallel, 347 cats were examined at IPEC [29].

Because sporotrichosis has not been compulsorily notified,

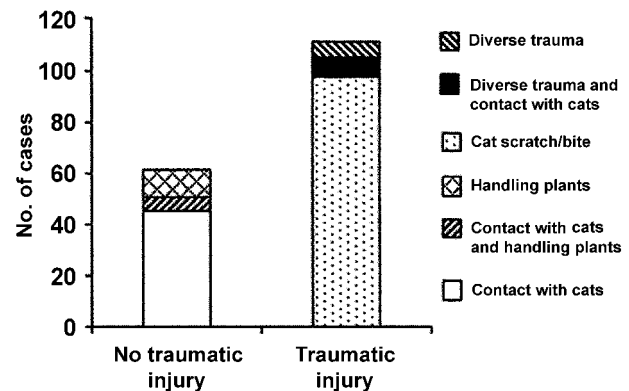


Figure 5. Number of cases of sporotrichosis, according to the presence of traumatic injury.

it is difficult to properly assess its occurrence and distribution in the State of Rio de Janeiro, and the real incidence may have been underestimated. However, it probably has been occurring in an insidious manner, reaching an epidemic proportion only in the past few years. This hypothesis is based on the following observations: (1) sporotrichosis in cats and zoonotic transmission have been considered rare all over the world; (2) at IPEC, mycological examination has been part of the routine investigation of granulomatous skin lesions since 1986; (3) the first cases of human sporotrichosis in which lesions arose at a site previously scratched by a cat were recorded at IPEC in 1991 and 1997 [28]; (4) during the course of the epidemic, a considerable reduction of the time of evolution of the lesions was observed when comparing the years 1998 and 2001, reflecting improved information about the disease on the part of both the population and health professionals, especially veterinarians, who started to refer the owners of cats with sporotrichosis to our services. This also indicates why there has been a sharp increase observed in the number of cases of sporotrichosis diagnosed at our institution.

Some epidemiological data involving sex, occupation, and transmission stand out, such as the predominance of adult women involved in domestic activities, probably because this is the group that is most exposed to the fungus by caring for the animals. In most published reports, leisure and occupational activities involving the soil and agriculture were associated with transmission of the disease [3, 8, 33–36], and some reports have suggested a higher risk for male individuals. However, there seems to be no sex-associated predilection for infection [37], and in reports of studies with a predominance of women, the occupational activity was also related to transmission [3, 33]. Curiously, the proportion of patients aged <15 years was low, especially if we consider that children usually play with animals. Unfortunately, there are no similar studies involving patients and zoonotic transmission for comparison. Pappas et al. [5] detected 60% of cases affecting children in a region of hyperendemicity in Peru.

The potential for transmission by cats is considerable [10, 12, 27], because cats commonly present with extensive lesions that are rich in parasites [29]. In patients who denied experiencing trauma, unperceived injuries may have easily occurred [12, 13, 38–40], especially during animal handling. It is also part of cats' behavior to rub their faces against their handlers, to bite, and to scratch. Schubach et al. [29] also demonstrated the zoonotic potential of cats when they isolated *S. schenckii* from 100% of skin lesions, 66.2% of nasal cavities, 41.8% of oral cavities, and 39.5% of the nails of cats with sporotrichosis. Reis et al. [41] studied 15 cases from this epidemic and showed, by molecular typing, the relationship between the patient strains and *S. schenckii* isolated from cats.

The predominant clinical form was lymphocutaneous, which

was also the case for other outbreaks in different areas of endemicity [5, 17, 25, 33, 42]. In this patient series, we did not diagnose the systemic form of the disease, even in cases involving comorbidities [43–45]. In the patient coinfecting with *Mycobacterium tuberculosis*, sporotrichosis did not present as an opportunistic disease, as reported by Schamroth et al. [46]. On the other hand, 16.3% of patients presented with skin lesions at multiple locations, due in part to repeated inoculation during contact with sick animals [31]. Bilateral involvement of the limbs has occasionally been reported elsewhere [47, 48]. Particularly noteworthy were 4 cases involving lesions in the conjunctiva and 1 case involving a lesion in the nasal mucosa, locations that are only exceptionally reported [49], although infections in these locations are considered by some authors to be a variation of the cutaneous form. These lesions may be explained by different mechanisms, such as self-inoculation, bloodstream dissemination, or aspiration of conidia and/or yeast forms from cat lesions or sneezes [29].

According to Gutierrez-Galhardo et al. [32], cases of erythema nodosum may be due to constant exposure to the cat lesions containing large amounts of fungi, possibly leading to subclinical reinfection, resulting in hypersensitivity of the erythema nodosum type. The same may have occurred in patients presenting with erythema multiforme and arthralgia, symptoms present in ~30% of patients, without radiologically visible involvement of bones or joints.

With respect to diagnosis, the results of direct microscopic evaluation of wet mount preparations were negative for almost all samples, as has also been reported by others [4]. Although most authors rarely report the presence of fungal elements in human tissues [46, 50], we found that a relatively high percentage (28.8%) of histopathological examinations revealed the presence of fungi in the lesions. It is possible that transmission by direct contact with an infected animal contributed to this result. However, some authors have pointed out that a more meticulous study may reveal the pathogen [36, 51].

Spontaneous remission was observed in 13 patients, although it has been rarely reported in the literature [52, 53]. Traditionally, supersaturated potassium iodide solution has successfully been used for the treatment of cutaneous sporotrichosis. The efficacy of this medication, as well as its low cost, has meant that it is a favored choice, especially for low-income populations. However, the frequency of adverse effects, especially those involving the digestive tract, has led to use of itraconazole as the first treatment choice. In this study, we present data on therapeutic response from the largest series of patients with sporotrichosis treated with itraconazole. Although there is a need for a clinical trial, this drug has proven to be safe and effective, even at low doses, as has been demonstrated by others [14, 43, 54].

It is interesting to note that, although many patients re-

mained in contact with sick cats, there was only 1 case of reactivation of the lesion 5 months after treatment. This may have been because a degree of temporary immunity was conferred by the infection or because there was prolonged exposure to the fungus [54].

However, a major question remains unanswered: why did the number of cases of sporotrichosis reach the epidemic proportion of an emergent zoonosis in the metropolitan region of Rio de Janeiro? The typical patients involved in this epidemic reside in houses located in regions of underprivileged socioeconomic conditions and with precarious health services. Factors related to the behavior of cats—who, although intimately cohabiting with human beings, do not remain fixed inside the domicile, but usually circulate in the neighborhood, often getting involved in fights with other animals and contacting soil and plants—may possibly have contributed to the dissemination of the disease. Additional case-control investigations and other epidemiological, social, and environmental studies are needed to better understand this question.

Acknowledgment

We thank Rodrigo de Almeida Paes, Serviço de Micologia, Instituto de Pesquisa Clínica Evandro Chagas, Fiocruz, for technical support.

References

- Conti Diaz IA. Epidemiology of sporotrichosis in Latin America. *Mycopathologia* **1989**; 108:113–6.
- Schenck B. On refractory subcutaneous abscesses caused by a fungus possibly related to the sporotricha. *Johns Hopkins Hosp Bull* **1898**; 93:286–90.
- Kusuhara M, Hachisuka H, Sasai Y. Statistical survey of 150 cases with sporotrichosis. *Mycopathologia* **1988**; 102:129–33.
- Kwon-Chung KJ, Benett JE. Sporotrichosis. In: Kwon-Chung KJ, Benett JE, eds. *Medical mycology*. Philadelphia: Lea & Febiger, **1992**:707.
- Pappas PG, Tellez I, Deep AE, Nolasco D, Holgado W, Bustamante B. Sporotrichosis in Peru: description of an area of hyperendemicity. *Clin Infect Dis* **2000**; 30:65–70.
- Centers for Disease Control and Prevention. Multistate outbreak of sporotrichosis in seedling handlers, 1988. *MMWR Morb Mortal Wkly Rep* **1988**; 37:652–3.
- Helm M, Berman C. The clinical, therapeutic and epidemiological features of sporotrichosis infection of the mines. In: *Proceedings of the Transvaal Mine Medical Officers' Association Symposium on Sporotrichosis Infection on Mines of the Witwatersrand (Johannesburg)*. Johannesburg, South Africa: The Transvaal Chamber of Mines, **1947**.
- Dixon DM, Salkin IF, Duncan RA, et al. Isolation and characterization of *Sporothrix schenckii* from clinical and environmental sources associated with the largest US epidemic of sporotrichosis. *J Clin Microbiol* **1991**; 29:1106–13.
- Kauffman CA. Sporotrichosis. *Clin Infect Dis* **1999**; 29:231–7.
- Dunstan RW, Langham RF, Reimann KA, Wakenell PS. Feline sporotrichosis: a report of five cases with transmission to humans. *J Am Acad Dermatol* **1986**; 15:37–45.
- Marques SA, Franco SR, de Camargo RM, Dias LD, Haddad Junior V, Fabris VE. Sporotrichosis of the domestic cat (*Felis catus*): human transmission [in Portuguese]. *Rev Inst Med Trop Sao Paulo* **1993**; 35:327–30.
- Reed KD, Moore FM, Geiger GE, Stemper ME. Zoonotic transmission of sporotrichosis: case report and review. *Clin Infect Dis* **1993**; 16:384–7.
- Smilack JD. Zoonotic transmission of sporotrichosis. *Clin Infect Dis* **1993**; 17:1075.
- Kauffman CA, Hajjeh R, Chapman SW. Practice guidelines for the management of patients with sporotrichosis. The Mycoses Study Group. Infectious Diseases Society of America. *Clin Infect Dis* **2000**; 30:684–7.
- Schubach TMP, Schubach AO. Esporotricose em cães e gatos—revisão. *Clínica Veterinária* **2000**; 5:21–4.
- Mackinnon J, Conti Diaz I, Gezuele E, Civilia E, Da Luz S. Isolation of *Sporothrix schenckii* from nature and considerations on its pathogenicity and ecology. *Sabouraudia* **1969**; 7:38–45.
- Conti-Diaz IA. Sporotrichosis in Uruguay: epidemiologic and clinical aspects. Washington, DC: Pan American Health Organization Scientific Publication, **1980**:312–21.
- Schubach TM, Schubach AO, Okamoto T, et al. Feline sporotrichosis epidemic in the metropolitan area of Rio de Janeiro—clinical presentation and treatment of 347 cats (1998–2001). *J Am Vet Med Assoc* (in press).
- Lutz A, Splendore A. Sobre uma mycose observada em homens e ratos. *Revista Medica de São Paulo* **1907**; 21:433–50.
- Madeira JA, Cerruti H. Sobre um caso de esporotricose cutânea verrucosa generalizada. I Reunião Anual dos Dermato-Sifilógrafos Brasileiros. Rio de Janeiro: Sociedade Brasileira de Dermatologia e Sifilografia, **1945**.
- Ramos e Silva J. Fomas minimais de esporotricose: seu interesse clínico. *O Hospital* **1945**; 28:99–109.
- Sampaio SAP, Lacaz CS, Almeida F. Aspectos clínicos da esporotricose em São Paulo—análise de 235 casos. *Revista do Hospital das Clínicas* **1954**; 9:391–402.
- Gonçalves AP, Peryassu D. A Esporotricose no Rio de Janeiro. *O Hospital* **1954**; 46:9–24.
- Donadel K, Reinoso Y, Oliveira J, Azulay RD. Esporotricose: revisão. *Anais Brasileiros de Dermatologia* **1993**; 68:45–52.
- Lopes JO, Alves SH, Mari CR, et al. Epidemiology of sporotrichosis in the central region of Rio Grande do Sul [in Portuguese]. *Rev Soc Bras Med Trop* **1999**; 32:541–5.
- Larsson CE, Goncalves Mde A, Araujo VC, Dagli ML, Correa B, Fava Neto C. Feline sporotrichosis: clinical and zoonotic aspects [in Portuguese]. *Rev Inst Med Trop Sao Paulo* **1989**; 31:351–8.
- Fleury RN, Taborda PR, Gupta AK, et al. Zoonotic sporotrichosis. Transmission to humans by infected domestic cat scratching: report of four cases in Sao Paulo, Brazil. *Int J Dermatol* **2001**; 40:318–22.
- Barros MB, Schubach TM, Gutierrez Galhardo MC, et al. Sporotrichosis: an emergent zoonosis in Rio de Janeiro. *Mem Inst Oswaldo Cruz* **2001**; 96:777–9.
- Schubach TM, de Oliveira Schubach A, dos Reis RS, et al. *Sporothrix schenckii* isolated from domestic cats with and without sporotrichosis in Rio de Janeiro, Brazil. *Mycopathologia* **2002**; 153:83–6.
- Schubach TM, Valle AC, Gutierrez-Galhardo MC, et al. Isolation of *Sporothrix schenckii* from the nails of domestic cats (*Felis catus*). *Med Mycol* **2001**; 39:147–9.
- Barros MBL, Schubach AO, Gutierrez-Galhardo MC, et al. Sporotrichosis with widespread cutaneous lesions: a report of 24 cases related to transmission by domestic cats in Rio de Janeiro, Brazil. *Int J Dermatol* **2003**; 42:677–81.
- Gutierrez Galhardo MC, De Oliveira Schubach A, De Lima Barros MB, et al. Erythema nodosum associated with sporotrichosis. *Int J Dermatol* **2002**; 41:114–6.
- Itoh M, Okamoto S, Kariya H. Survey of 200 cases of sporotrichosis. *Dermatologica* **1986**; 172:209–13.
- England T, Kasten MJ, Martin R, et al. Multistate outbreak of sporotrichosis in seedling handlers, 1988. *Arch Dermatol* **1989**; 125:170.

35. Eisfelder M, Okamoto S, Toyama K. Experience with 241 sporotrichosis cases in China/Japan [in German]. *Hautarzt* **1993**;44:524–8.
36. Espinosa-Texis A, Hernandez-Hernandez F, Lavalle P, Barba-Rubio J, Lopez-Martinez R. Study of 50 patients with sporotrichosis: clinical and laboratory assessment [in Spanish]. *Gac Med Mex* **2001**;137:111–6.
37. Schell WA. Agents of chromoblastomycosis and sporotrichosis. In: Libero Ajello RJH, ed. *Microbiology and microbial infections*. 9th ed. London: Arnold, **1998**:315–36.
38. Read SI, Sperling LC. Feline sporotrichosis: transmission to man. *Arch Dermatol* **1982**;118:429–31.
39. Schiappacasse RH, Colville JM, Wong PK, Markowitz A. Sporotrichosis associated with an infected cat. *Cutis* **1985**;35:268–70.
40. Zamri-Saad M, Salmiyah TS, Jasni S, Cheng BY, Basri K. Feline sporotrichosis: an increasingly important zoonotic disease in Malaysia. *Vet Rec* **1990**;127:480.
41. Reis RS, Schubach TM, Guimarães A, Monteiro P, Zancopé-Oliveira R. Molecular typing of *Sporothrix schenckii* strains isolated from clinical specimens in Rio de Janeiro, Brazil [abstract 498]. In: Program and abstracts of the 14th Congress of the International Society for Human and Animal Mycology (Buenos Aires). Buenos Aires: International Society for Human and Animal Mycology, **2000**:133.
42. Vismer HF, Hull PR. Prevalence, epidemiology and geographical distribution of *Sporothrix schenckii* infections in Gauteng, South Africa. *Mycopathologia* **1997**;137:137–43.
43. Sharkey-Mathis PK, Kauffman CA, Graybill JR, et al. Treatment of sporotrichosis with itraconazole. NIAID Mycoses Study Group. *Am J Med* **1993**;95:279–85.
44. Lynch PJ, Voorhees JJ, Harrell ER. Systemic sporotrichosis. *Ann Intern Med* **1970**;73:23–30.
45. Pluss JL, Opal SM. Pulmonary sporotrichosis: review of treatment and outcome. *Medicine (Baltimore)* **1986**;65:143–53.
46. Schamroth JM, Grieve TP, Kellen P. Disseminated sporotrichosis. *Int J Dermatol* **1988**;27:28–30.
47. Tomimori-Yamashita J, Takahashi CH, Fischman O, Costa EB, Michalany NS, Alchorne MM. Lymphangitic sporotrichosis: an uncommon bilateral localization. *Mycopathologia* **1998**;141:69–71.
48. Takase T, Uyeno K. Sporotrichosis with bilateral lesions: a case report. *Mycoses* **1990**;33:325–34.
49. Vieira-Dias D, Sena CM, Orefice F, Tanure MA, Hamdan JS. Ocular and concomitant cutaneous sporotrichosis. *Mycoses* **1997**;40:197–201.
50. Segal RJ, Jacobs PH. Sporotrichosis. *Int J Dermatol* **1979**;18:639–44.
51. Bullpitt P, Weedon D. Sporotrichosis: a review of 39 cases. *Pathology* **1978**;10:249–56.
52. Iwatsu T, Nishimura K, Miyaji M. Spontaneous disappearance of cutaneous sporotrichosis: report of two cases. *Int J Dermatol* **1985**;24:524–5.
53. Bargman H. Sporotrichosis of the skin with spontaneous cure—report of a second case. *J Am Acad Dermatol* **1983**;8:261–2.
54. Restrepo A, Robledo J, Gomez I, Tabares AM, Gutierrez R. Itraconazole therapy in lymphangitic and cutaneous sporotrichosis. *Arch Dermatol* **1986**;122:413–7.