

**REDESCRIPTION OF ANGIOSTRONGYLUS (PARASTRONGYLUS)
COSTARICENSIS MORERA & CÉSPEDES (NEMATODA,
METASTRONGYLOIDEA) FROM A BRAZILIAN STRAIN**

Silvana C. Thiengo¹
Joaquim Júlio Vicente²
Roberto Magalhães Pinto²

ABSTRACT. Morphometric data on larval and adult specimens of *Angiostrongylus (Parastrongylus) costaricensis* Morera & Céspedes, 1971 recovered from Swiss albino mice experimentally infected is presented. Infective larvae were obtained from parasitized veronicellid *Sarasinula marginata* (Semper, 1885) maintained in the laboratory. This is the first complete morphometric study regarding specimens of a Brazilian strain of *A. (P.) costaricensis*.

KEY WORDS. Nematoda, *Angiostrongylus (P.) costaricensis*, Mollusca, *Sarasinula marginata*, taxonomy, morphology, Brazil

Angiostrongylus (Parastrongylus) costaricensis Morera & Céspedes, 1971, is an accidental parasite of the mesenteric arteries of man, since its natural life cycle occurs among rodents and terrestrial molluscs. It causes in man abdominal angiostrongylosis, which may result in severe ischemic and inflammatory intestinal lesions. This zoonosis has been reported from Southern United States of America to Northern Argentina (MORERA 1986). Most of the cases in Brazil have been described from Southern States: São Paulo, Paraná, Santa Catarina, and Rio Grande do Sul (ZILLIOTO *et al.* 1975; AGOSTINI *et al.* 1983; AYALA 1987). Cases were also reported from the Federal District of Brasília (BARBOSA *et al.* 1980), from the State of Minas Gerais (ROCHA *et al.* 1991) and from the State of Espírito Santo (PENA *et al.* 1995).

MATERIAL AND METHODS

Parasites were recovered from Swiss albino mice (*Mus musculus* Linné, 1758) and the veronicellid slug *Sarasinula marginata* (Semper, 1885) in a 0.85% NaCl solution, fixed in hot A.F.A. solution (Alcohol 70%, 93 ml; formaldehyde 5ml; glacial acetic acid, 2ml) dehydrated unstained in ethanol, cleared in glycerine, phenol or creosote and preserved as whole mounts in balsam or kept as wet material

1) Departamento de Malacologia, Instituto Oswaldo Cruz. Avenida Brasil 4365, 21045-900 Rio de Janeiro, Rio de Janeiro, Brasil.

2) Laboratório de Helmintos Parasitos de Vertebrados, Departamento de Helminologia, Instituto Oswaldo Cruz. Avenida Brasil 4365, 21045-900 Rio de Janeiro, Rio de Janeiro, Brasil. CNPq fellow.

in the same fixative solution. Glycerine jelly mounts for the "en face" preparations were obtained according to ANDERSON (1958). Drawings were made with the aid of a tubular camera lucida connected to an Olympus light microscope. Measurements are in millimeters (mm). The studied specimens were deposited in the Helminthological Collection of Instituto Oswaldo Cruz (CHIOC). Classification of the nematodes follows ANDERSON (1978).

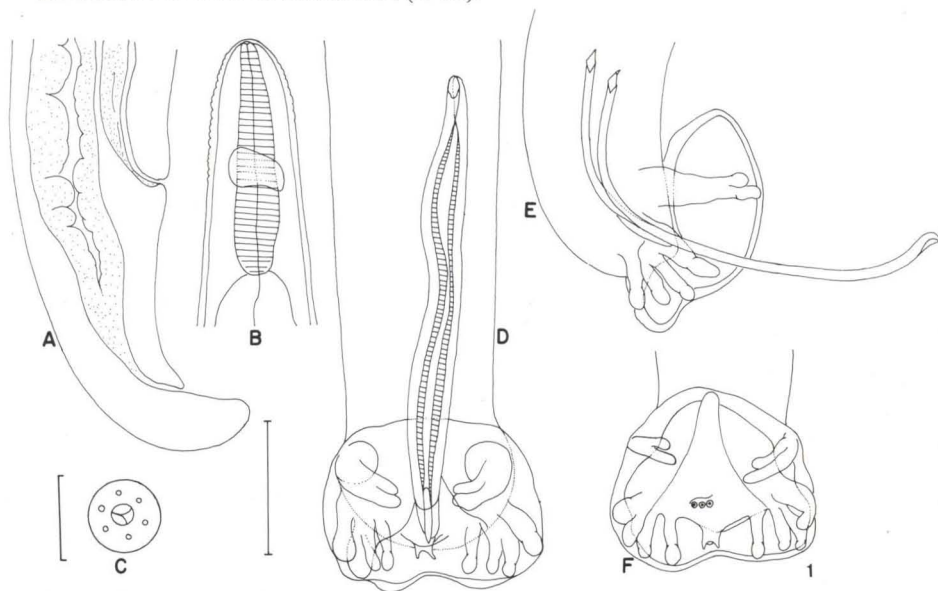


Fig. 1. *Angiostrongylus (Parastrongylus) costaricensis*. (A) Posterior portion of female, lateral view; (B) anterior portion of female, lateral view; (C) mouth of female, "en face" view; (D) posterior portion of male, ventral view; (E) posterior portion of male, lateral view; (F) posterior extremity of male, ventral view. Scales: (A, B, D, E and F) bar=1mm, (C) bar=0,05mm.

RESULTS

Angiostrongylus (Parastrongylus) costaricensis Morera & Céspedes, 1971

Figs 1-2; Tabs I-II

Adults (based on 10 males and 10 females recovered 50 days after experimental infection). Body filiform, tapered toward both ends, with caudal extremity ventrally curved in both sexes. Oral aperture simple, circular, surrounded by six inconspicuous papillae. Excretory pore slightly posterior to the junction of esophagus and intestine. Nerve ring anterior to the middle of esophagus.

Males (Fig. 1 D, E, F): body 12.0-16.0 long, 0.16-0.22 wide. Esophagus club-shaped, 0.18-0.19 long and 0.08-0.10 wide at its base. Nerve ring and excretory pore 0.09-0.11 and 0.23-0.26 from anterior end, respectively. Spicules slender,

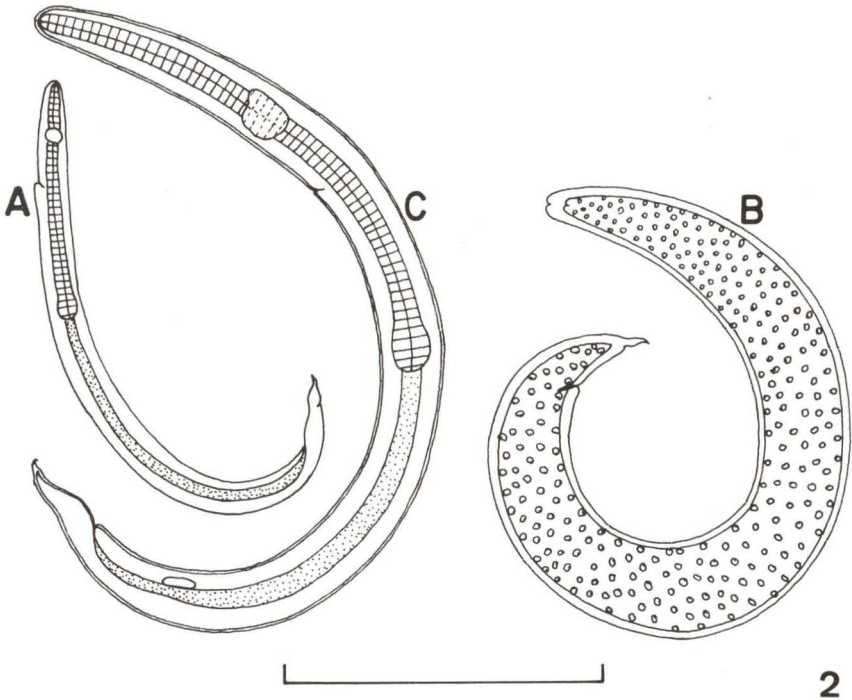


Fig. 2. *Angiostrongylus (Parastrongylus) costaricensis*. (A) First stage larva, lateral view; (B) second stage larva, lateral view; (C) third stage larva, lateral view. Scale: bar=1mm.

striated, equal, similar with sharp points, 0.34-0.37 long. Gubernaculum with two branches 0.04-0.05 long. Copulatory bursa symmetric 0.15-0.19 long if not distended. Ventral rays are fused, except at the tips; ventrolateral slightly longer than ventroventral. Lateral rays emerging from a common trunk widely separated from ventrals; mediolateral and the posterolateral fused in their proximal half; anterolateral thicker and separated from common trunk just after its emergence from it. Externolateral ray arising close to the lateral trunk and well separated from dorsal ray, with knoblike distal end. Dorsal ray short, 0.01-0.02 long bifurcates into sharp tips; conspicuous papilla present behind bifurcation. Cloacal aperture at 0.03-0.04 from distal extremity of dorsal ray and with crescent-shaped opening, anterior to three papillae.

Females (Fig. 1 A, B, C): Body 22.5-30.0 long, 0.22-0.25 wide. Esophagus as described for the males, 0.17-0.22 long and 0.08-0.11 wide at its base. Nerve ring and excretory pore 0.09-0.012 and 0.23-0.26 from anterior end, respectively. Vulvar aperture 0.19-0.26 from posterior extremity. Eggs 0.03-0.04 long. Anus 0.04-0.07 from posterior end.

Larvae (Fig. 2 A-C): (based on 10 larvae of each stage). First stage larvae (Fig. 2 A): body 0.22-0.26 long, 0.01-0.02 wide. Esophagus 0.11-0.12 long. Nerve ring and excretory pore 0.03-0.05 and 0.06-0.09 from anterior end, respectively. Anus 0.02-0.03 from distal end. Tail sharp pointed with an indentation on dorsal surface. Second stage larvae (Fig. 2 B): body 0.28-0.31 long, 0.02 wide. Nerve ring

(observed in two specimens) 0.04-0.06 from anterior extremity. Anus 0.01-0.02 from distal end. Tail with dorsal indentation. At this stage the larvae retain the sheath of the first molt and numerous granules in the intestinal lumen, making difficult the observation of internal structures. Third stage larvae (Fig. 2 C): body 0.40-0.50 long, 0.02-0.03 wide. Esophagus 0.17 long. Nerve ring and excretory pore 0.04-0.06 and 0.08-0.11 from anterior extremity, respectively. Anus 0.03-0.04 from distal end. As in other stages, the tail presents the dorsal indentation. The sheaths of the two molts are maintained until they are in contact with the gastric juice, when these larvae are liberated and become active.

Table I. Comparison of the measurements (mm) among adults of *Angiostrongylus (Parastrongylus) costaricensis* from Costa Rica (MORERA 1973), Venezuela (SANTOS 1985) and from Brazil (GRAEFF-TEIXEIRA 1989) and present data.

Measurements	Male				Female			
	Morera	Santos	Graeff-Teixeira	Present data	Morera	Santos	Graeff-Teixeira	Present data
Length	17.4-22.2	16.7-18.9	12.8-16.2	12.0-16.1	28.4-42.0	24.5-27.9	21.3-29.3	22.5-30.3
Width	0.28-0.31	0.28	0.21-0.30	0.16-0.22	0.32-0.35	-	0.16-0.32	0.22-0.25
Width at the base of esophagus	0.11-0.14	-	-	0.08-0.10	0.13-0.15	-	0.09-0.13	0.08-0.11
Esophagus	0.18-0.22	0.25-0.26	-	0.18-0.19	0.23-0.26	0.22-0.25	0.20-0.25	0.17-0.22
Nerve ring	-	-	-	0.09-0.11	-	-	-	0.09-0.12
Excretory pore	-	-	-	0.23-0.26	-	-	-	0.23-0.26
Spicules	0.31-0.33	0.27-0.33	0.39-0.42	0.34-0.37	-	-	-	-
Gubernaculum	-	-	-	0.04-0.05	-	-	-	-
Width of bursa	-	-	-	0.15-0.19	-	-	-	-
Dorsal ray	-	-	-	0.01-0.02	-	-	-	-
Cloacal aperture	-	-	-	0.03-0.04	-	-	-	-
Ovjector	-	-	-	-	-	-	-	0.06-0.07
Vulva	-	-	-	-	0.24-0.29	0.21-0.29	0.14-0.28	0.19-0.26
Eggs	-	-	-	-	-	-	-	0.03-0.04
Anus	-	-	-	-	0.06-0.065	0.04-0.06	0.03-0.07	0.04-0.07

Table II. Comparison of the measurements (mm) among larvae of *Angiostrongylus (Parastrongylus) costaricensis* from Costa Rica (MORERA 1973) and from Brazil (present data).

Measurements	L1		L2		L3	
	Morera	Present data	Morera	Present data	Morera	Present data
Length	0.26-0.29	0.22-0.26	0.37	0.28-0.31	0.46-0.48	0.40-0.54
Width	0.01-0.02	0.01-0.02	0.04	0.02	0.03	0.02-0.03
Esophagus	0.12	0.11	-	-	0.16	0.15
Nerve ring	0.04	0.03-0.05	-	0.04-0.06	0.06	0.04-0.06
Excretory pore	-	0.06-0.09	-	-	0.08	0.08-0.11
Anus	0.03	0.02-0.03	-	0.02	0.03	0.03-0.04

Taxonomic summary

Definitive host (experimentally infected): *Mus musculus* Linné, 1758.

Intermediate host (experimentally infected): *Sarasinula marginata* (Semper, 1885)

Site of infection: mesenteric artery and its branches in the intestinal wall of definitive host.

Specimens studied: CHIOC n° 33.289 a-d (whole mounts) n° 32.988 (wet material)

DISCUSSION

Angiostrongylus (P.) costaricensis, due to its implication in human abdominal angiostrongylosis, has been the subject of many studies regarding its life cycle, potential intermediate hosts, epidemiology, pathology and other related parameters. However only a few papers deal with morphometric aspects of this nematode (MORERA & CESPEDES 1971; MORERA 1973; SANTOS 1985; GRAEFF-TEIXEIRA *et al.* 1989; ISHIIH *et al.* 1990). All of them, except for data after GRAEFF-TEIXEIRA *et al.* (1989) deal with findings in other countries. These authors studied 16 females and 4 males from Brazilian Swiss albino mice. Nevertheless, the redescription of *A. (P.) costaricensis* in Brazil lacks substantial information on the parasite morphology since only differences between measurements of some structures were considered by comparison of specimens of *Angiostrongylus (P.) costaricensis* from albino *M. musculus* from Brazil with those reported by MORERA (1973) based on specimens recovered from the cotton rat, *Sigmodon hispidus* Say & Ord, 1825 and other Costa Rican hosts. The present findings in *A. (P.) costaricensis* are in agreement with those previously reported (Tab. I, II), except for the fact that males studied by GRAEFF-TEIXEIRA *et al.* (1989) presented bigger spicules. In our opinion, the morphometric differences so far observed between samples from Costa Rica, Venezuela and Brazil probably concern intraspecific variation.

REFERENCES

- AGOSTINI, A.A.; A. PEIXOTO; A. CALEFFI; A. DEXHAIMER & R.R. CAMARGO. 1983. Angiostrongilíase abdominal. Três casos observados no Rio Grande do Sul. **R. AMRGS** 27: 200-203.
- ANDERSON, R.C. 1958. Méthode pour l'examen des nématodes en vue apicale. **Ann. Parasitol. Hum. et Comp.** 33: 171-172.
- . 1978. Keys to the genera of the superfamily Metastrongyloidea. In: R.C. ANDERSON, A.G. CHABAUD & S. WILLMOT (Eds). **C.I.H. Keys to the nematode parasites of vertebrates. #5**. Bucks, Commonwealth Agricultural Bureaux, Farnham Royal, 40p.
- AYALA, M. 1987. Angiostrongiloidose abdominal nos Estados do Paraná e Santa Catarina: apresentação de cinco casos e revisão da literatura. **Mem. Inst. Oswaldo Cruz** 8: 29-36.
- BARBOSA, H.; A.N. RAICK; A.V. MAGALHÃES & P.M.F. OTERO. 1980. Angiostrongilose abdominal. **Rev. Ass. Med. Brasil.** 226: 178-180.
- GRAEFF-TEIXEIRA, C.; J.W. THOMÉ; S.C. PINTO; L. CAMILLO-COURA & H. LENZI. 1989. *Phyllocaulis variegatus* – an intermediate host of *Angiostrongylus costaricensis* in south Brazil. **Mem. Inst. Oswaldo Cruz** 84: 65-68.
- ISHIH, A.; B.A. RODRIGUEZ & M. SANO. 1990. Scanning electron microscopic observations of the first and third stage larvae and adults of *Angiostrongylus costaricensis*. **Southeast Asian Jour. Trop. Med. Pub. Health** 21: 568-573.
- MORERA, P. 1973. Life history and redescription of *Angiostrongylus costaricensis* Morera & Céspedes, 1971. **Amer. Jour. Trop. Med. Hyg.** 22: 613 -621.

- . 1986. Abdominal angiostrongyliasis, p.4-8. In: J.A. SPITTELL (Ed.). **Clinical Medicine**. Philadelphia, Harper & Row Publishers.
- MORERA, P. & R. CÉSPEDES. 1971. *Angiostrongylus costaricensis* n.sp. (Nematoda: Metastrongylidae) a new lungworm occurring in man in Costa Rica. **Rev. Biol. Trop.** **18**: 173-185.
- PENA, G.P.M.; J.S. ANDRADE FILHO & S.C. ASSIS. 1995. *Angiostrongylus costaricensis*: First record of its occurrence in the state of Espírito Santo, Brazil, and a review of its geographic distribution. **Rev. Inst. Med. trop. São Paulo** **37**: 369-374.
- ROCHA, A; J.M. SOBRINHO & L.C. SALOMÃO. 1991. Angiostrongilíase abdominal. Primeiro relato de caso autóctone de Minas Gerais. **Rev. Soc. Bras. Med. Trop.** **24**: 265-268.
- SANTOS, C.P. 1985. Redescritção de *Angiostrongylus (Parastrongylus) costaricensis* isolado de um novo hospedeiro silvestre, *Proechimys* sp. na Venezuela (Metastrongyloidea: Angiostrongylidae). **Mem. Inst. Oswaldo Cruz** **80**: 81-83.
- ZILIOOTTO, A. JR.; J.E. KUNZLE; L.A. RUS FERNANDEZ; J.C. PRATES-CAMPOS & R. BRITTO-COSTA. 1975. Angiostrongilíase: apresentação de um provável caso. **Rev. Inst. Med. trop. São Paulo** **17**: 312-318.

Recebido em 16.I.1997; aceito em 02.X.1997.