

Angiostrongylus cantonensis and Rat Lungworm Disease in Brazil

Silvana Carvalho Thiengo PhD; Raquel de Oliveira Simões MsC;
Monica Ammon Fernandez PhD; and Arnaldo Maldonado Júnior PhD

Abstract

The metastrongyloid nematode genus *Angiostrongylus* includes 18 species, two of which are relevant from a medical standpoint, *Angiostrongylus costaricensis* and *Angiostrongylus cantonensis*. The first was described from Costa Rica in 1971 and causes abdominal angiostrongyliasis in the Americas, including in Brazil. *Angiostrongylus cantonensis*, first described in 1935 from Canton, China, is the causative agent of eosinophilic meningitis. The natural definitive hosts are rodents, and molluscs are the intermediate hosts. Paratenic or carrier hosts include crabs, freshwater shrimp, amphibians, flatworms, and fish. Humans become infected accidentally by ingestion of intermediate or paratenic hosts and the parasite does not complete the life cycle as it does in rats. Worms in the brain cause eosinophilic meningitis. This zoonosis, widespread in Southeast Asia and the Pacific islands, has now been reported from other regions. In the Americas there are records from the United States, Cuba, Jamaica, Brazil, Ecuador, and Haiti. In Brazil seven human cases have been reported since 2007 from the southeastern and northeastern regions. Epidemiological studies found infected specimens of *Rattus norvegicus* and *Rattus rattus* as well as many species of molluscs, including the giant African land snail, *Achatina fulica*, from various regions of Brazil. The spread of angiostrongyliasis is currently a matter of concern in Brazil.

Keywords

Achatina fulica, *Angiostrongyliasis*, Brazil, Eosinophilic meningitis, *Rattus norvegicus*, *Rattus rattus*, Snails

Introduction

The metastrongyloid nematode *Angiostrongylus cantonensis* causes eosinophilic meningitis (and meningoencephalitis) in humans. This parasite, widespread in Southeast Asia and some Pacific islands, has now dispersed to other regions, including Latin America.¹ The spread of this emerging zoonosis is correlated with increased tourism, commerce, and the diversification of habits and customs in certain countries, factors that have facilitated the dispersal of the definitive and intermediate hosts of *A. cantonensis*.² In addition, the introduction of non-native molluscs plays an important role, as has been observed with the giant African snail, *Achatina fulica*, in Brazil³⁻⁵ and the South American freshwater snail *Pomacea canaliculata* in China.⁶ Species of *Angiostrongylus* can infect domestic dogs and wild mammals,⁷ as well as humans, as accidental hosts, causing parasitic diseases.⁸ Besides *A. cantonensis*, another congeneric species, *A. costaricensis*, described from Costa Rica in 1971,⁹ is important from a public health standpoint as the causative agent of abdominal angiostrongyliasis, a zoonosis recorded from the south of the United States to northern Argentina. In Costa Rica up to 500 human cases are reported annually.¹⁰ In Brazil cases have been reported mainly in the southern States.¹¹ This paper focuses on *A. cantonensis* in Brazil.

Taxonomy

Attempts to organize the family Angiostrongylidae into genera

and subgenera, based on the morphology of the rays of the caudal bursa and on the host species, have divided the scientific community, particularly in relation to the important human parasites, ie, *A. cantonensis* and *A. costaricensis*.

Dougherty¹² synonymized the following genera with *Angiostrongylus*: *Haemostromylus*, *Parastrongylus*, *Pulmonema*, *Cardionema*, and *Rodentocaulus*. Subsequently, Skrjabin et al.¹³ recognized four genera, accepting Dougherty's synonyms, with the exception of *Rodentocaulus*, which was retained as a valid genus along with two additional more recently described genera that were also considered valid, *Rattostrongylus* and *Angiocaulus*. Yamaguti¹⁴ accepted the systematic arrangement proposed by Skrjabin et al.¹³

In 1970 Drozd⁵ proposed dividing the genus *Angiostrongylus* into two subgenera: *Angiostrongylus* (*Angiostrongylus*) with *Haemostromylus*, *Cardionema*, and *Angiocaulus* as synonyms; and *Angiostrongylus* (*Parastrongylus*) with *Rodentocaulus*, *Pulmonema*, and *Rattostrongylus* as synonyms. Chabaud¹⁵ abolished the subgenera, and recognized four genera: *Angiostrongylus* (with synonyms *Haemostromylus*, *Cardionema*, and *Angiocaulus*), *Parastrongylus*, *Rodentocaulus*, and his newly created genus *Morerostromylus*. However, Anderson⁷ adopted the subgeneric classification of Drozd, with *Morerostromylus* as a synonym of *Parastrongylus*, which was treated as a subgenus of *Angiostrongylus*, but with the exception of recognizing *Rodentocaulus* as a distinct valid genus.

In 1986, Ubelaker¹⁶ reorganized the family Angiostrongylidae, recognizing the genera *Angiostrongylus* (synonym *Haemostromylus*), *Parastrongylus* (synonyms *Pulmonema*, *Rattostrongylus*, *Morerostromylus*, *Chabaudistromylus*), *Angiocaulus* (synonym *Cardionema*), *Rodentocaulus*, *Galegostrongylus* (synonym *Thaistromylus*), and *Stefanskostrongylus*. Although this is the most recent taxonomic revision of the Angiostrongylidae, based on morphological similarity of the bursal rays and host animals, it has not been widely accepted, since, for instance, few people use *Parastrongylus* for *A. cantonensis*. Too few molecular data are available to help resolve the systematics of the family.

Based on the classification of Dougherty,¹² we recognize 18 species of *Angiostrongylus* from around the world (excluding those albeit nomenclaturally valid species that have been described on the basis only of female morphology). *Angiostrongylus vasorum*, *A. raillieti*, *A. gubernaculatus*, and *A. chabaudi* have carnivores as their definitive hosts. The remaining 14 species have rodents as definitive hosts: *A. taterone*, *A. cantonensis*, *A. sciuri*, *A. mackerrasae*, *A. sandarsae*, *A. petrowi*, *A. dujardini*, *A. schmidti*, *A. costaricensis*, *A. malaysiensis*, *A. ryjikovi*, *A. siamensis*, *A. morerai*, and *A. lenzii*.

Angiostrongylus cantonensis was originally described in the genus *Pulmonema* from specimens recovered from the lungs of naturally infected rats (*Rattus norvegicus* and *Rattus rattus*) from Canton, China.¹⁷ The adult worms (Figure 1) are characterized by a filiform body in both sexes, tapering at the anterior end. Females are larger and more robust than males. Detailed morphological descriptions have been published elsewhere.^{18,19}

Life Cycle and Hosts

The life cycle of *A. cantonensis* involves various species of terrestrial and freshwater gastropods as intermediate hosts and rats as definitive hosts.²⁰⁻²³ As *A. cantonensis* occurs in the adult stage in the pulmonary arteries of the definitive hosts, commonly *Rattus rattus* and *R. norvegicus*, it is known as the rat lungworm. In experimental infection of *R. norvegicus*, the female worm lays eggs inside the pulmonary arteries, where they develop into the first-stage larvae (L₁), which then move to the interior of the alveoli. The larvae then migrate to the pharynx and are swallowed, pass through the gastrointestinal tract, and are eliminated in the feces.^{21,24} Land or freshwater snails are the principal intermediate hosts, and become infected either by ingestion of L₁ in the rat feces or by penetration of these larvae through the body wall or respiratory pore.²⁵ In the mollusc tissue the L₁ molts twice (L₂ and L₃) and the period necessary for the development is around 20 days. Rats become infected mainly by the ingestion of intermediate hosts infected by L₃ larvae. These larvae then penetrate the intestinal wall and enter the bloodstream a few hours after being ingested. They reach the pulmonary circulation from the heart and are dispersed to various other organs by the arterial circulation. Many reach the brain and molt again, becoming L₄ larvae. The fifth molt into the subadult stage (L₅) occurs in the subarachnoid space, from where, after developing further, they migrate to the pulmonary arteries where they are found 25 days after infection. The worms then reach sexual maturity at around 35 days and the L₁ larvae can be found in the rodent's feces about 42 days after the exposure to the previous generation of L₁ larvae.

Infection in humans occurs when they eat raw or undercooked snails and slugs, or paratenic hosts, including land crabs, freshwater shrimp, fish, frogs, and planarians.²⁶ In humans, the young larvae reach the brain, where they die rather than migrating further and completing their development. This causes eosinophilic meningitis (or meningoencephalitis), which has neurological symptoms. Usually the infection does not kill the victim, except when there is massive exposure to infective L₃ larvae.²⁷

The parasite displays broad specificity for intermediate hosts; many species of terrestrial and freshwater molluscs have been found naturally infected, including *Achatina fulica*, *Bradybaena similaris*, *Subulina octona*, *Pomacea canaliculata*, *Pomacea lineata*, other *Pomacea* species, *Deroceras laeve*, and species of *Pila*.^{3,18,23,28} It has been found in various paratenic hosts, and although these are passive hosts in which the parasite does not undergo any development, they play an important role as they increase the opportunities for the parasite to infect definitive hosts.

In southern China, an apple snail species, *Pomacea canaliculata*, and the giant African snail, *Achatina fulica*, both non-native, are widespread and the number of cases of eosinophilic meningitis has been increasing, the transmission being linked to both species. Most recently, serious outbreaks have been reported, in most cases directly related to consumption of *P. canaliculata*.^{6,29}

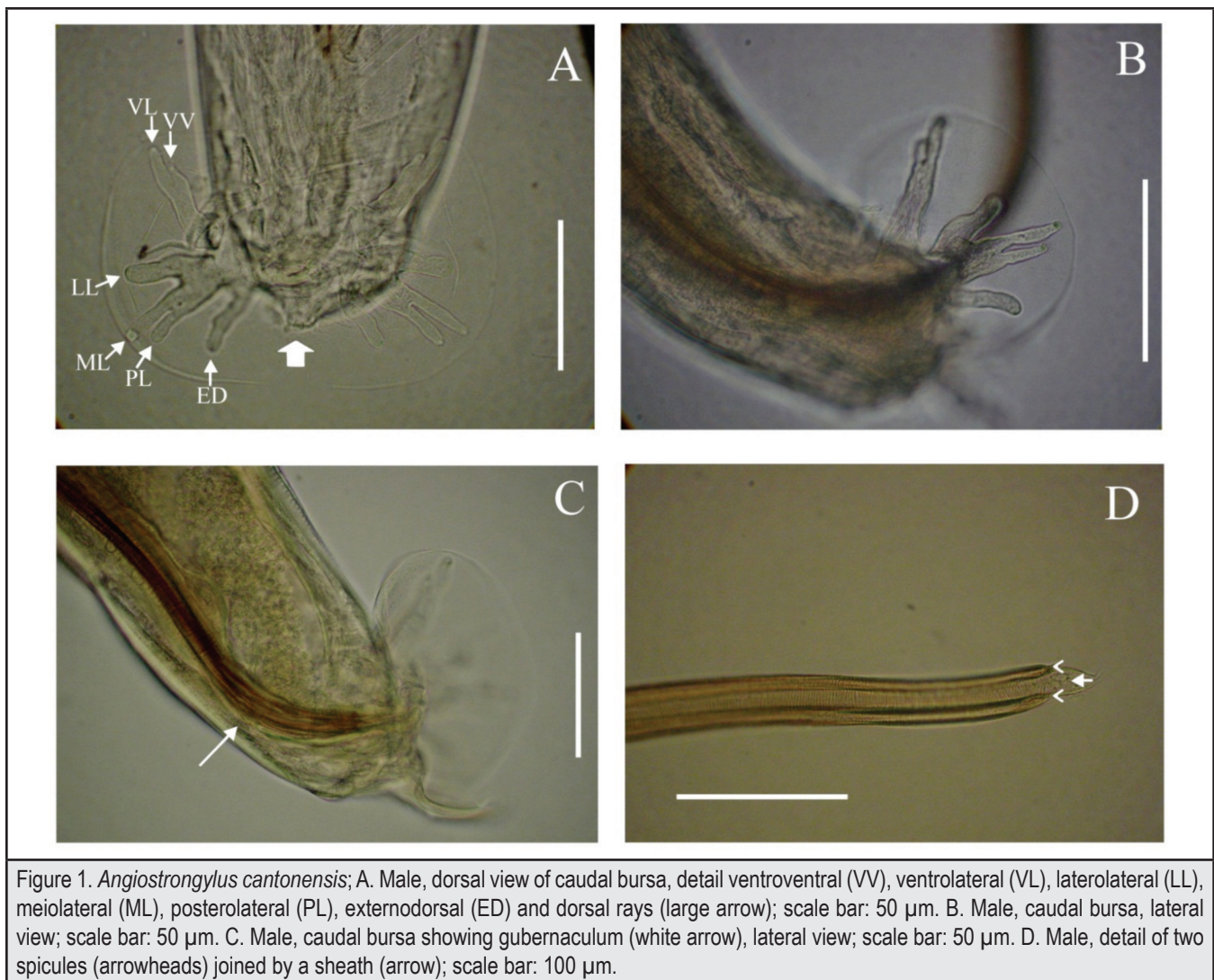
Angiostrongylus cantonensis and Angiostrongyliasis in Brazil

Sporadic outbreaks of eosinophilic meningitis caused by *A. cantonensis* were first reported in the Americas in the latter part of the twentieth century.³⁰ The zoonosis, or at least infected rodents, have now been reported in the Americas and islands of the Caribbean from the United States,³¹ Cuba,^{32,33} Jamaica,³⁴ Brazil,^{3,4,26} Ecuador,³⁵ and Haiti.³⁶

The first report of this zoonosis in Brazil was in the municipality of Cariacica, Espírito Santo State,³ with subsequent reports from two municipalities (Olinda and Escada) in Pernambuco State,^{18,26} and in the city of São Paulo, São Paulo State.³⁷ In the first two states naturally infected definitive and/or intermediate hosts had been discovered during the epidemiological investigation of the human cases. *Achatina fulica* was considered the vector in three of the four reported cases.^{3,18,26} One of the cases in Pernambuco State was attributed to ingestion of undercooked apple snails (*Pomacea lineata*).¹⁸ Specimens of *A. fulica* have been found infected with *A. cantonensis* larvae in south and southeastern Brazil since 2007 and more recently from Pará State in the Amazon region, northern Brazil.³⁸ A species of *Pomacea* was also associated with an outbreak of eosinophilic meningitis in Ecuador.³⁵

Natural infection of definitive vertebrate hosts with *A. cantonensis* has also been reported in Brazil. Infected *Rattus rattus* and *R. norvegicus* have both been found in Pará State³⁸ and infected *R. norvegicus* have also been reported in the States of Rio de Janeiro (southeastern Brazil)³⁹ and Rio Grande do Sul (southern Brazil), according to Carlos Graeff-Teixeira (oral communication, June 2012). Some reports of infected rodents in urban areas were associated with epidemiological investigations following the occurrence of cases of eosinophilic meningitis.³⁹ The prevalence of *A. cantonensis* in rodents is highly variable⁸ and does not suggest specificity among species in the genus *Rattus*.

How *A. cantonensis* arrived and became established in the Americas is not well understood, although Diaz⁴⁰ attributed its introduction to introduction of *Rattus norvegicus* in shipping containers. Its introduction to Brazil has been postulated as either with parasitized rats during the country's colonial period (1500-1822), when there was frequent contact with Africa and Asia⁴ and/or by recent invasion of the giant African snail, *A. fulica*, which began in the 1980s.^{41,42} As Brazil is currently experiencing the explosive phase of the invasion of *A. fulica*, which has now been recorded in 25 of the 26 states and in the Federal District (Figure 2), the emergence of eosinophilic meningitis is a matter of concern,^{41,42} although many species of molluscs may act as intermediate hosts in Brazil.⁴³



Conclusion

The spread of *Angiostrongylus cantonensis* in Brazil is a matter of public health concern because of the widespread occurrence of infected rats and snails in peridomestic areas. There is a need for education of the population regarding disease transmission and prevention. Physicians should be made more aware of the possibility of *A. cantonensis* infection. And serological diagnosis of angiostrongyliasis should be available to facilitate appropriate medical treatment. Control and monitoring of intermediate and definitive hosts in areas of epidemiological relevance should be undertaken to limit the occurrence of new transmission foci.

Conflict of Interest

None of the authors identifies any conflict of interest.

Acknowledgements

This paper represents a contribution to the Rat Lungworm Disease Scientific Workshop held at the Ala Moana Hotel, Honolulu, Hawaii in August 2011.

Funding for the workshop and for this publication was provided by the National Institute of Food and Agriculture, United States Department of Agriculture, through Award No. 2011-65213-29954.

Authors' Affiliations:

- Laboratório de Malacologia, Instituto Oswaldo Cruz-Fiocruz, Rio de Janeiro, RJ, Brasil (S.C.T., M.A.F.)
- Laboratório de Biologia e Parasitologia de Mamíferos Silvestres Reservatórios, Instituto Oswaldo Cruz-Fiocruz, Rio de Janeiro, RJ, Brasil (R.D.S., A.M.)

Correspondence to:

Silvana Carvalho Thiengo PhD; Laboratório de Malacologia, Instituto Oswaldo Cruz-Fiocruz, Av. Brasil 4365, 21040-900 Rio de Janeiro, RJ, Brasil; Ph: +55 21 2562 1305; Email: sthiengo@ioc.fiocruz.br

References

1. Foronda P, López-González M, Miquel J, et al. Finding of *Parastrongylus cantonensis* (Chen, 1935) in *Rattus rattus* in the Canary Islands (Spain). *Acta Trop.* 2010;114:123-127.
2. Cross J. Public health importance of *Angiostrongylus cantonensis* and its relatives. *Parasitol Today.* 1987;3(12):367-369.
3. Caldeira R, Mendonça C, Gouveia C, et al. First record of molluscs naturally infected with *Angiostrongylus cantonensis* (Chen, 1935) (Nematoda: Mestastromylidae) in Brazil. *Mem Inst Oswaldo Cruz.* 2007;102(7):887-889.

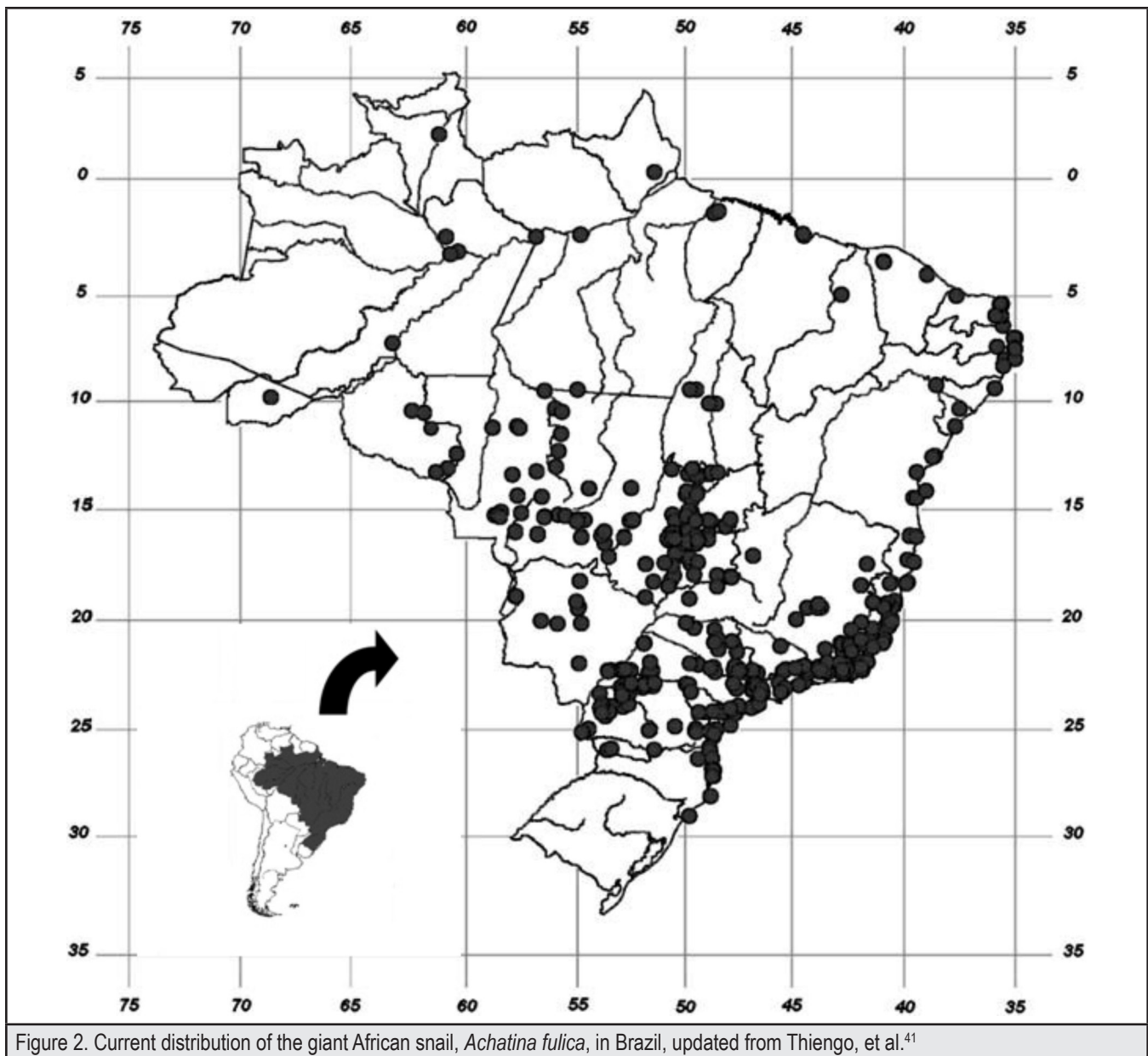


Figure 2. Current distribution of the giant African snail, *Achatina fulica*, in Brazil, updated from Thiengo, et al.⁴¹

4. Maldonado A Jr, Simões R, Oliveira A, et al. First report of *Angiostrongylus cantonensis* (Nematoda: Metastrongylidae) in *Achatina fulica* (Mollusca: Gastropoda) from southeast and south regions of Brazil. *Mem Inst Oswaldo Cruz*. 2010;105(7): 938-941.
5. Drozd J. Révision de le systématique du genre *Angiostrongylus* Kamensky, 1905 (Nematoda: Metastrongyloidea). *Ann Parasit Hum Comp*. 1970;45(5):597-603.
6. Lv S, Zang Y, Liu H, et al. 2009. Invasive snails and an emerging infectious disease: results from the first national survey on *Angiostrongylus cantonensis* in China. *PLoS Neglect Trop Dis*. 2009;3(2):1-8.
7. Anderson RC. *CIH Keys to the Nematode Parasites of Vertebrates*. No. 5. *Keys to Genera of the Superfamily Metastrongyloidea*. Farnham Royal, UK: Commonwealth Agricultural Bureau; 1978.
8. Wang Q-P, Lai D-H, Zhu X-Q, Chen X-G, et al. Human angiostrongyliasis. *Lancet Infect Dis*. 2008;8:621-630.
9. Morera P, Céspedes R. *Angiostrongylus costaricensis* n. sp. (Nematoda: Metastrongylidae) a new lungworm occurring in Man in Costa Rica. *Rev Biol Trop*. 1971;18:173-185.
10. Morera P, Amador J. Prevalencia de la angiostrongilosis abdominal y la distribución estacional en la precipitación. *Rev Costarric Salud Publica*. 1998;7:1-14.
11. Quirós JL, Jiménez E, Bonilla R, et al. Abdominal angiostrongyliasis with involvement of liver histopathologically confirmed: a case report. *Rev Inst Med Trop São Paulo*. 2011;53(4):219-222.
12. Dougherty EC. The genus *Aelurostrongylus* Cameron, 1927 (Nematoda: Metastrongylidae), and its relatives; with descriptions of *Parafilaroides* gen. nov., and *Angiostrongylus gubernaculatus* sp. nov. *Proc Helm Soc Wash*. 1946;13(1):16-26.
13. Skrjabin KI, Shikhobalova NP, Schulz RS, Popova TI, Boev SN, Delyamure SL. *Keys to Parasitic Nematodes, Vol. 3 Strongylata*. Brill: Leiden; 1997.
14. Yamaguti S. Studies on the helminth fauna of Japan. Part 35. Mammalian nematodes II. *Japan J Zool*. 1941;9(3):409-439.
15. Chabaud AG. Description of *Stefankostrongylus dubostini* sp. parasite of *Patomagale* and attempt at classification of Angiostrongylinae nematodes. *Ann Parasit Hum Comp*. 1972;47(5):735-744.
16. Ubelaker JE. Systematics of species referred to the genus *Angiostrongylus*. *J Parasitol*. 1986;72:237-244.
17. Chen HT. Un nouveau nématode pulmonaire, *Pulmonema cantonensis* n. g., n. sp., des rats de Canton. *Ann Parasit Hum Comp*. 1935;13:312-370.
18. Thiengo SC, Maldonado A, Mota EM, et al. The giant African snail *Achatina fulica* as natural intermediate host of *Angiostrongylus cantonensis* in Pernambuco, northeast Brazil. *Acta Trop*. 2010;115:194-199.
19. Maldonado A, Simões R, Thiengo SC. Angiostrongyliasis in the Americas. In: Lorenzo-Morales J, ed. *Zoonosis*. InTech, Rijeka. 2012;303-320.
20. Cheng T, Alicata J. On the mode of infection of *Achatina fulica* by the larvae of *Angiostrongylus cantonensis*. *Malacologia*. 1965;2:267-274.

21. Bhaibulaya M. Comparative studies on the life history of *Angiostrongylus mackerrasae* Bhaibulaya, 1968 and *Angiostrongylus cantonensis* (Chen, 1935). *Int J Parasitol.* 1975;5:7-20.
22. Graeff-Teixeira C, da Silva ACA, Yoshimura K. Update on eosinophilic meningoencephalitis and its clinical relevance. *Clin Microbiol Rev.* 2009;22(2):322-348.
23. Wallace G, Rosen L. Studies on eosinophilic meningitis V. Molluscan hosts of *Angiostrongylus cantonensis* on Pacific Islands. *Am J Trop Med Hyg.* 1969;18(2):206-216.
24. Yousif F, Ibrahim A. The first record of *Angiostrongylus cantonensis* from Egypt. *Z Parasitenkd.* 1978;56:73-80.
25. Thiengo SC. Mode of infection of *Sarasinula marginata* (Mollusca) with *Angiostrongylus costaricensis* larvae (Nematoda). *Mem Inst Oswaldo Cruz.* 1996;91(3):277-288.
26. Acha PN, Szyfres B. *Zoonosis y Enfermedades Transmisibles Comunes al Hombre y a los Animales.* Organización Panamericana de la Salud: Washington, DC; 2003.
27. Lima A, Mesquita S, Santos S, et al. Alicate disease: neuroinfestation by *Angiostrongylus cantonensis* in Recife, Pernambuco, Brazil. *Arq Neuro-psiquiat.* 2009;67(4):1093-1096.
28. Malek E, Cheng T. *Medical and Economic Malacology.* Academic Press: New York; 1974.
29. Lv S, Zhang Y, Steinmann P, et al. The emergence of angiostrongyliasis in the People's Republic of China: the interplay between invasive snails, climate change and transmission dynamics. *Freshw Biol.* 2011;56(4):717-734.
30. Pascual JE, Bouli RP, Aguiar H. Eosinophilic meningitis in Cuba, caused by *Angiostrongylus cantonensis*. *Am J Trop Med Hyg.* 1981;30:960-962.
31. New D, Little M, Cross J. *Angiostrongylus cantonensis* infection from eating raw snails. *New Engl J Med.* 1995;332(16):1105-1106.
32. Aguiar PH, Moreira P, Pascual J. First record of *Angiostrongylus cantonensis* in Cuba. *Am J Trop Med Hyg.* 1981;30(5):963-965.
33. Dorta-Contreras A, Padilla-Docal B, Moreira J, et al. Neuroimmunological findings of *Angiostrongylus cantonensis* meningitis in Ecuadorian patients. *Arq Neuro-psiquiat.* 2011;69(3):466-469.
34. Slom T, Johnson S. Eosinophilic meningitis. *Curr Infect Dis Rep.* 2003;5(4):322-328.
35. Pincay T, García L, Narváez E, Decker O, Martini L, Moreira JM. Angiostrongyliasis due to *Parastrostrongylus (Angiostrongylus) cantonensis* in Ecuador. First report in South America. *Trop Med Int Health.* 2009;14(suppl 2):37.
36. Raccurt CP, Blaise J, Durette-Desset MC. Présence d'*Angiostrongylus cantonensis* en Haïti. *Trop Med Int Health.* 2003;8(5):423-426.
37. Ciaravolo RMC, Pinto PLS, Mota DJG. Meningite eosinofílica e a infecção por *Angiostrongylus cantonensis*: um agravo emergente no Brasil. *Vector, Inf Têc Cient, SUCEN-SES-SP.* 2010;8:7-8.
38. Moreira V, Giese E, Nascimento L, et al. Endemic angiostrongyliase in Brazilian Amazon: a natural parasitism by *Angiostrongylus cantonensis* (Nematoda: Metastrongyloidea) in *Rattus rattus* and *R. norvegicus* (Rodentia: Muridae) and *Achatina fulica* (Mollusca: Gastropoda). *Acta Trop.* 2013;125(1):90-7.
39. Simões R, Monteiro F, Sánchez E, et al. Endemic angiostrongyliasis, Rio de Janeiro, Brazil. *Emerg Infect Dis.* 2011;17(7):1331-1333.
40. Diaz J. Helminth eosinophilic meningitis: emerging zoonotic diseases in the South. *J Louisiana State Med Soc.* 2008;160(6):333-342.
41. Thiengo SC, Faraco FA, Salgado NC, et al. Rapid spread of an invasive snail in South America: the giant African snail, *Achatina fulica*, in Brasil. *Biol Invasions.* 2007;9:693-702.
42. Zanol J, Fernandez M, Oliveira A, Russo C, Thiengo S. The exotic invasive snail *Achatina fulica* (Stylommatophora, Mollusca) in the State of Rio de Janeiro (Brazil): current status. *Biota Neotrop.* 2010;10(3):447-451.
43. Carvalho OS, Scholte RGC, Mendonça CLF, Passos LKJ, Caldeira RL. *Angiostrongylus cantonensis* (Nematode: Metastrongyloidea) in molluscs from harbour areas in Brazil. *Mem Inst Oswaldo Cruz.* 2012;107(6):740-746.