

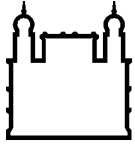
MINISTÉRIO DA SAÚDE  
FUNDAÇÃO OSWALDO CRUZ  
INSTITUTO OSWALDO CRUZ

Doutorado em Medicina Tropical

Avaliação de fatores epidemiológicos, micológicos, clínicos e  
terapêuticos associados à esporotricose.

DAYVISON FRANCIS SARAIVA FREITAS

Rio de Janeiro  
Fevereiro de 2014



Ministério da Saúde

FIOCRUZ

Fundação Oswaldo Cruz

## **INSTITUTO OSWALDO CRUZ**

### **Doutorado em Medicina Tropical**

*DAYVISON FRANCIS SARAIVA FREITAS*

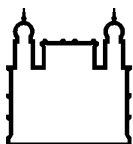
Avaliação de fatores epidemiológicos, micológicos, clínicos e terapêuticos associados à esporotricose.

Tese apresentada ao Instituto Oswaldo Cruz como parte dos requisitos para obtenção do título de Doutor em Medicina.

**Orientadoras:** Prof<sup>a</sup>. Dr<sup>a</sup>. Maria Clara Gutierrez Galhardo  
Prof<sup>a</sup>. Dr<sup>a</sup>. Rosely Maria Zancopé Oliveira

**RIO DE JANEIRO**

Fevereiro de 2014



Ministério da Saúde

FIOCRUZ

Fundação Oswaldo Cruz

## **INSTITUTO OSWALDO CRUZ**

**Doutorado em Medicina Tropical**

***AUTOR: DAYVISON FRANCIS SARAIVA FREITAS***

Avaliação de fatores epidemiológicos, micológicos, clínicos e terapêuticos associados à esporotricose.

**ORIENTADORAS:** Prof<sup>a</sup>. Dr<sup>a</sup>. Maria Clara Gutierrez Galhardo  
Prof<sup>a</sup>. Dr<sup>a</sup>. Rosely Maria Zancopé Oliveira

**Aprovada em: 26 / 02 / 2014**

### **EXAMINADORES:**

**Prof. Dr. Antonio Carlos Francesconi do Valle - IPEC/FIOCRUZ (Presidente)**

**Prof. Dr. Bodo Wanke – IPEC/FIOCRUZ**

**Prof. Dr. Leonardo Nimrichter – UFRJ/RJ**

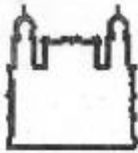
**Prof<sup>a</sup>. Dr<sup>a</sup>. Isabella Dib Ferreira Gremião – IPEC/FIOCRUZ**

**Prof. Dr. José Henrique da Silva Pilotto – IOC/FIOCRUZ**

**Prof. Dr. Rodrigo de Almeida Paes – IPEC/FIOCRUZ (Suplente)**

**Prof. Dr. Manoel Marques Evangelista de Oliveira – IPEC/FIOCRUZ (Suplente)**

Rio de Janeiro, 26 de fevereiro de 2014.



Ministério da Saúde

Fundação Oswaldo Cruz  
Instituto Oswaldo Cruz

Ata da defesa da tese de doutorado em Medicina Tropical de **Dayvison Francis Saraiva Freitas**, sob orientação de Dr<sup>a</sup> Maria Clara Gutierrez Galharo e Dr<sup>a</sup> Rosely Maria Zancopé Oliveira. Ao vigésimo sexto dia do mês de fevereiro de dois mil e quatorze, realizou-se às nove horas, no Auditório Maria Deane/Fiocruz, o exame da tese de doutorado intitulada: "**Avaliação de fatores epidemiológicos, micológicos, clínicos e terapêuticos associados à esporotricose**" no programa de Pós-graduação em Medicina Tropical do Instituto Oswaldo Cruz, como parte dos requisitos para obtenção do título de Doutor em Medicina - área de concentração: Doenças Infecciosas e Parasitárias, na linha de pesquisa: Estudos biológicos, clínicos e epidemiológicos da doença de Micoses. A banca examinadora foi constituída pelos Professores: Dr. Antonio Carlos Francesconi do Valle – IPEC/Fiocruz (presidente), Dr. Bodo Wanke – IPEC/Fiocruz, Dr. Leonardo Nimrichter – UFRJ, Dr<sup>a</sup> Isabella Dib Ferreira Gremião – IPEC/Fiocruz e Dr. José Henrique da Silva Pilotto – IOC/Fiocruz; e como suplentes: Dr. Rodrigo de Almeida Paes – IPEC/Fiocruz e Dr. Manoel Marques Evangelista de Oliveira - IPEC/Fiocruz. Após arguir o candidato e considerando que o mesmo demonstrou capacidade no trato do tema escolhido e sistematização da apresentação dos dados, a banca examinadora pronunciou-se pela aprovação da defesa da tese de doutorado. De acordo com o regulamento do programa de Pós-graduação em Medicina Tropical do Instituto Oswaldo Cruz, a outorga do título de **Doutor em Medicina** está condicionada à emissão de documento comprobatório de conclusão do curso. Uma vez encerrado o exame, o Coordenador do Programa, Dr. Filipe Anibal Carvalho Costa, assinou a presente ata tomando ciência da decisão dos membros da banca examinadora. Rio de Janeiro, 26 de fevereiro de 2014.

Dr. Antonio Carlos Francesconi do Valle (Presidente da Banca):

Dr. Bodo Wanke (Membro da Banca):

Dr. Leonardo Nimrichter (Membro da Banca):

Dr<sup>a</sup> Isabella Dib Ferreira Gremião (Membro da Banca):

Dr. José Henrique da Silva Pilotto (Membro da Banca):

Dr. Filipe Anibal Carvalho Costa (Coordenação do Programa):

*Aos meus pais José Francisco e Maria  
Antonia, à minha irmã “Sanda” e à  
minha sobrinha e afilhada Julianne.  
Obrigado pelo amor!*

A vida das gentes neste mundo, senhor sabugo, é isso.  
Um rosário de **PiScAdAs**. Cada **PiScO** é um dia. **PiScA** e  
mama; **PiScA** e anda; **PiScA** e brinca; **PiScA** e estuda;  
**PiScA** e ama; **PiScA** e cria filhos; **PiScA** e geme os reu-  
matismos; por fim **PiScA** pela última vez e *morre*.

– E depois que morre? – perguntou o Visconde.

– Depois que morre, vira hipótese.

**É OU NÃO É?**

Monteiro Lobato

## AGRADECIMENTOS

Vamos por partes... Ir da clínica ao laboratório, do Rio à NYC, foi uma aventura e tanto!

À Maria Clara, incansável, persistente, psicóloga e sempre disponível. À sua família, por dividir sua atenção e seu tempo comigo, mesmo nas férias.

Ao Francesconi, pelos ensinamentos e confiança.

Aos colegas médicos do IPEC, pelo atendimento aos pacientes, intercâmbio de ideias e conhecimentos.

Aos profissionais do SEAM e do Hospital do IPEC, pela presteza e carinho com os pacientes.

À Dayse, pela parceria, prontidão e pelos bons papos.

À Sayonara, grande médica e pessoa, por ter me apresentado à Fiocruz.

À Raquel, fera na estatística, pelas dicas desde o mestrado.

À Rosely, antes brava, agora doce, parceira e provedora de novos conhecimentos e oportunidades.

Ao Rodrigo, meu ídolo em sua sapiência científica, foi professor, orientador, revisor, conselheiro, companheiro de viagem e amigo.

À velha guarda do DM, atuais ou ex, Helena, Fábio, Rosani e Mônica, pelos ensinamentos com minhas inúmeras perguntas. Aos colegas permanentes ou passageiros, pela ajuda nos experimentos.

Ao Manoel, pela orientação na parte molecular, e tantas outras dicas. Espero ainda ter muitas parcerias com você e com o Rodrigo.

Ao Marcos, pela paciência no laboratório e pelos papos e noitadas.

Aos novos companheiros de laboratório IMD, pela paciência em me ensinar.

Aos coordenadores da PGMT, Dr<sup>a</sup>. Alda Cruz e Dr. Filipe Costa, pelo carinho e atenção.

Aos professores da pós-graduação, mestres e doutores exemplares.

Aos profissionais da Secretaria Acadêmica da PGMT, pela flexibilidade e disponibilidade em ajudar.

*To Dr. Joshua Nosanchuk (Josh), for receiving me in his lab at Einstein, so clever, friendly, patient and fun.*

*To David Sanchez, o gringo mais brasileiro e bacana que já conheci, por tudo que me ensinou, no lab e nas ruas de NYC. Será sempre bem-vindo ao Brasil.*

*À Su, à Lu, às Anas, à Estefe e à Lorena, pela ajuda com os experimentos no Einstein.*

*A estas e aos outros Brazukas do Bronx, amigos que fiz e que ficarão para sempre em meu coração, pela cumplicidade e pelo apoio mútuo.*

*To all the guys at Einstein, from Nosanchuk's, Casadevall's, and others who helped me a lot.*

*To the staff at Einstein, for helping me during my stay there.*

*À Fiocruz e à CAPES, pelo apoio estrutural e financeiro.*

*Ao CNPq, pela bolsa de doutorado *sandwich* do projeto Ciência sem Fronteiras.*

*To Fogarty International Center, for the additional funding during my research in the United States of America, at Einstein College of Medicine.*

*Aos professores e médicos, desde a pré-escola até a residência médica, pelo engrandecimento.*

*À Pati, minha mãe de iniciação científica e grande amiga, por ter me apresentado melhor o mundo da ciência.*

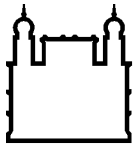
*Aos meus amigos e amigas, que souberam entender e me aturar nos momentos de estresse e reclusão durante os anos de doutorado, proporcionando o bem-estar nos momentos difíceis e nos fáceis também.*

*À minha família: pai, mãe, Sanda e Juju pela força incondicional e pelo amor.*

*Aos meus tios e primos, em especial aos dindinhos Célio e Toninho, *in memoriam*, pela admiração e confiança, mesmo que à distância.*

*Aos pacientes que atendi e, de alguma forma, pude contribuir para a melhora na qualidade de suas vidas, meu grande agradecimento, pois certamente contribuíram muito mais comigo.*





Ministério da Saúde

FIOCRUZ

Fundação Oswaldo Cruz

## INSTITUTO OSWALDO CRUZ

### AValiação de Fatores Epidemiológicos, Micológicos, Clínicos e Terapêuticos Associados à Esporotricose.

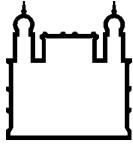
#### RESUMO

#### TESE DE DOUTORADO EM MEDICINA TROPICAL

Dayvison Francis Saraiva Freitas

Esporotricose é uma micose subcutânea causada pelo fungo dimórfico previamente descrito como uma única espécie, *Sporothrix schenckii*, agora entendido como um complexo de diferentes espécies de interesse clínico. A região metropolitana do Rio de Janeiro constitui área hiperendêmica de esporotricose zoonótica transmitida por gatos desde 1998. Clinicamente tem se caracterizado por formas clínicas pouco usuais, manifestações de hipersensibilidade e um número crescente de pacientes coinfectados com HIV. Este estudo teve como objetivo avaliar fatores epidemiológicos, micológicos, clínicos e terapêuticos associados às diversas formas clínicas de pacientes com esporotricose. Foram utilizados o banco hospitalar de registros de pacientes e o banco de cepas do laboratório de micologia do Instituto de Pesquisa Clínica Evandro Chagas (IPEC), bem como técnicas de identificação genotípica e laboratoriais clássicas para determinação de virulência e fenótipo dos isolados fúngicos. Foi verificado que a dacriocistite aguda (quatro casos entre 2008 e 2010) é uma manifestação da esporotricose que evolui com complicações (fístula e dacriocistite crônica) necessitando reparação cirúrgica. A Síndrome de Sweet foi observada em três pacientes até 2010 e deve ser incorporada como manifestação de hipersensibilidade da esporotricose. As 12 gestantes com esporotricose entre 2005 e 2010 apresentaram boa evolução com termoterapia local. Na análise clínica e terapêutica de 21 casos de esporotricose e HIV, as formas clínicas variaram com o *status* imunológico dos pacientes e ocorreu resposta terapêutica em 81% dos casos. A investigação diagnóstica de doença sistêmica em pacientes com linfócitos T CD4<sup>+</sup> < 200 células/ $\mu$ L se impõe. Na série histórica avaliada, com 48 pacientes com esporotricose e HIV e 3.570 com esporotricose, observamos que pacientes com HIV evoluíram com quadros mais disseminados, hospitalização e óbito. Na avaliação genotípica de 50 isolados, *Sporothrix brasiliensis* esteve associado às formas pouco usuais e aos casos de hipersensibilidade. O estudo de cinco isolados coletados ao longo de cinco anos em um paciente com quadro de esporotricose disseminada demonstrou aumento de virulência no isolado obtido após 11 anos de infecção (5 anos de tratamento no IPEC), quando utilizado *Galleria mellonella* como modelo *in vivo*, sugerindo uma adaptação do fungo ao hospedeiro neste período. Conclui-se que a esporotricose no Rio de Janeiro está relacionada ao surgimento de formas raras e inéditas. Da mesma forma, tem acometido pacientes infectados pelo HIV, com morbimortalidade, devendo ser incorporada como uma infecção oportunística na sua forma disseminada. *S. brasiliensis*, espécie envolvida na quase totalidade dos casos desta região, pode ter incremento em sua virulência ao longo dos anos, favorecendo sua sobrevivência e dificultando a cura do paciente.

**Palavras-chave:** 1. Epidemiologia. 2. Esporotricose. 3. Formas Clínicas. 4. *Galleria mellonella*. 5. Genotipagem. 6. HIV. 7. Oportunística. 8. Síndrome de Sweet. 9. *Sporothrix brasiliensis*. 10. Virulência.



Ministério da Saúde

FIOCRUZ  
Fundação Oswaldo Cruz

## INSTITUTO OSWALDO CRUZ

### EVALUATION OF EPIDEMIOLOGICAL, MYCOLOGICAL, CLINICAL AND THERAPEUTIC FACTORS ASSOCIATED WITH SPOROTRICHOSIS.

#### ABSTRACT

#### PHD THESIS IN TROPICAL MEDICINE

Dayvison Francis Saraiva Freitas

Sporotrichosis is a subcutaneous mycosis caused by the dimorphic fungus previously described as a single species, *Sporothrix schenckii*, now understood as a complex of different species of clinical interest. The metropolitan region of Rio de Janeiro is an endemic area of zoonotic sporotrichosis transmitted by cats since 1998. Clinically, it has been characterized by unusual clinical presentations, manifestations of hypersensitivity and an increasing number of patients coinfecting with HIV. This study aimed to evaluate epidemiological, mycological, clinical and therapeutic factors associated with different clinical aspects of patients with sporotrichosis. The hospital database of patient records and the stock strains of the laboratory of mycology of Instituto de Pesquisa Clínica Evandro Chagas (IPEC) were used, as well as techniques for genotypic identification and classical laboratory tools for determination of virulence and phenotype of the fungal isolates. It was found that acute dacryocystitis (4 cases between 2008 and 2010) is a manifestation of sporotrichosis which evolves with complications (fistula and chronic dacryocystitis) requiring surgical repair. Sweet syndrome was observed in three patients until 2010 and should be incorporated as a manifestation of hypersensitivity of sporotrichosis. The 12 pregnant women with sporotrichosis between 2005 and 2010 presented a good evolution with local thermotherapy. In the clinical and therapeutical analysis of the 21 cases of sporotrichosis and HIV, the clinical forms varied with the immunological status of the patients, and a good therapeutic response was seen in 81% of the cases. The diagnostic investigation of systemic disease in immunosuppressed patients ( $CD4^+ < 200$  cells/ $\mu$ L) is required. In the historical series evaluated, with 48 patients with sporotrichosis and HIV, and 3,570 with sporotrichosis, it was seen that patients with HIV evolved with more disseminated pictures, hospitalization and death. In the genotypic evaluation of 50 isolates, *Sporothrix brasiliensis* was associated with unusual aspects and cases of hypersensitivity. The study of five isolates collected over five years in a patient with disseminated sporotrichosis demonstrated increased virulence of the isolate obtained after 11 years of infection (5 years of treatment at IPEC), when *Galleria mellonella* was used as an *in vivo* model, suggesting an adaptation of the fungus to the host within this period. In conclusion, sporotrichosis in Rio de Janeiro is related to the emergence of rare and novel aspects. On the same way, it has affected HIV-infected patients, with morbimortality, and should be incorporated as an opportunistic infection on its disseminated form. *S. brasiliensis*, the species involved in almost all cases of this region, may have an increase in virulence over the years, favoring its survival and hindering the healing of the patient.

**Keywords:** 1. Epidemiology. 2. Sporotrichosis. 3. Clinical Presentations. 4. *Galleria mellonella*. 5. Genotyping. 6. HIV. 7. Opportunistic. 8. Sweet syndrome. 9. *Sporothrix brasiliensis*. 10. Virulence.

## LISTA DE FIGURAS

Figura 1 – Morfologia de <i>Sporothrix</i> spp. ....	3
Figura 2 – Produção de Protease por <i>S. brasiliensis</i> . ....	8
Figura 3 – Produção de urease. ....	8
Figura 4 – Três tipos distintos de melanina produzidos por <i>Sporothrix</i> spp. ....	11
Figura 5 – Esporotricose felina. ....	15
Figura 6 – Formas clínicas de esporotricose humana. ....	20
Figura 7 – Reações de hipersensibilidade associadas à esporotricose. ....	22

## LISTA DE SIGLAS E ABREVIATURAS

AFLP	Polimorfismo do comprimento de fragmentos amplificados ( <i>Amplified fragment length polymorphism</i> )
Aids	Síndrome da imunodeficiência humana adquirida ( <i>Acquired Immunodeficiency Syndrome</i> )
BHI	Infusão de cérebro e coração ( <i>Brain Heart Infusion</i> )
CD4 <sup>+</sup>	Grupo de diferenciação de membrana 4 ( <i>Cluster of Differentiation</i> )
CD284	Grupo de diferenciação de membrana 284 ( <i>Cluster of Differentiation</i> )
CHS	Quitina sintase
CIM	Concentração inibitória mínima
CoA	Coenzima A
CTLA-4	Antígeno 4 de linfócitos T citotóxicos ( <i>Cytotoxic T-Lymphocyte Antigen 4</i> )
CYP3A4	Isoenzima da família P450
DHN	di-hidroxi naftaleno
DNA	Ácido desoxirribonucleico ( <i>Deoxyribonucleic acid</i> )
DPOC	Doença pulmonar obstrutiva crônica
ELISA	Ensaio Imunoenzimático ( <i>Enzyme-linked Immunosorbent assay</i> )
EUA	Estados Unidos da América
Fas-L	Fas-ligante: Uma proteína transmembrana ( <i>Fas ligand</i> )
Fiocruz	Fundação Oswaldo Cruz
HIV	Vírus da imunodeficiência humana ( <i>Human Immunodeficiency Virus</i> )

HTLV	Vírus Linfotrópico de células T humanas ( <i>Human T-lymphotropic Virus</i> )
IFN- $\gamma$	Interferon Gama
Ig	Imunoglobulina
IL	Interleucina
IPEC	Instituto de Pesquisa Clínica Evandro Chagas
ITS	Região de transcrição interna ( <i>internal transcribed spacer</i> )
SSKI	Solução saturada de iodeto de potássio
Lapclin- Dermzoo	Laboratório de Pesquisa Clínica em Dermatozoonoses em Animais Domésticos
L-DOPA	Levodopa (L-3,4-dihidroxi-fenilalanina)
M13	<i>Primer</i> específico para regiões minissatélites derivadas da sequência do fago tipo selvagem
P450	Superfamília muito ampla e diversificada de hemoproteínas celulares coloridas, com pigmento que absorve luz a 450nm
PAS	Ácido periódico de Schiff ( <i>Periodic acid-Schiff</i> )
PCR	Reação em cadeia da polimerase ( <i>Polymerase Chain Reaction</i> )
RAPD	DNA polimórfico randomicamente amplificado ( <i>Random amplified polymorphic DNA</i> )
rDNA	Ácido desoxirribonucleico ribossomal ( <i>ribosomal deoxyribonucleic acid</i> )
RFLP	Polimorfismo do comprimento de fragmentos de restrição ( <i>Restriction fragment length polymorphism</i> )
rRNA	Ácido ribonucleico ribossomal ( <i>ribosomal ribonucleic acid</i> )

S2-R2	<i>Primer</i> usado para reconhecer o gene codificador da quitina sintase
SNC	Sistema nervoso central
T3B	<i>Primer</i> universal para a região do t-RNA
Th1	Linfócitos T auxiliares do subtipo 1 ( <i>T-helper 1</i> )
Th2	Linfócitos T auxiliares do subtipo 2 ( <i>T-helper 2</i> )
TLR	Receptor do Tipo Toll ( <i>Toll-like receptor</i> )
TNF- $\alpha$	Fator de necrose tumoral alfa ( <i>Tumor necrosis factor</i> )

# SUMÁRIO

<b>1. INTRODUÇÃO</b> .....	<b>1</b>
1.1. REVISÃO DA LITERATURA .....	1
1.1.1. HISTÓRICO .....	1
1.1.2. O AGENTE .....	2
1.1.3. FATORES DE VIRULÊNCIA .....	6
1.1.3.1. TERMOTOLERÂNCIA .....	6
1.1.3.2. ATIVIDADE PROTEOLÍTICA .....	7
1.1.3.3. PRODUÇÃO DE UREASE .....	8
1.1.3.4. ADESINAS .....	9
1.1.3.5. OUTRAS PROTEÍNAS .....	9
1.1.3.6. PERÓXIDO DE ERGOSTEROL .....	10
1.1.3.7. MELANINA .....	10
1.1.4. EPIDEMIOLOGIA .....	12
1.1.5. FISIOPATOGENIA .....	15
1.1.6. RESPOSTA IMUNE .....	16
1.1.7. FORMAS CLÍNICAS .....	19
1.1.7.1. ESPOROTRICOSE E INFECÇÃO PELO HIV .....	23
1.1.8. DIAGNÓSTICO .....	24
1.1.8.1. DIAGNÓSTICO MICOLÓGICO .....	24
1.1.8.2. DIAGNÓSTICO HISTOPATOLÓGICO .....	25
1.1.8.3. INTRADERMORREAÇÃO .....	25
1.1.8.4. DIAGNÓSTICO SOROLÓGICO .....	26
1.1.8.5. DIAGNÓSTICO MOLECULAR .....	27
1.1.9. TRATAMENTO .....	27
1.1.9.1. TRATAMENTO ADJUVANTE .....	29
1.1.9.2. TRATAMENTO DE GESTANTES .....	30
1.1.10. MEDIDAS DE CONTROLE .....	31
1.2. RACIONAL E JUSTIFICATIVA .....	32

<b>2. OBJETIVOS .....</b>	<b>34</b>
2.1. OBJETIVO GERAL .....	34
2.2. OBJETIVOS ESPECÍFICOS .....	34
<b>3. CONSIDERAÇÕES ÉTICAS .....</b>	<b>35</b>
<b>4. CAPÍTULO 1 – APRESENTAÇÕES CLÍNICAS INÉDITAS E TERAPÊUTICA INCOMUM .....</b>	<b>36</b>
<b>5. CAPÍTULO 2 – ESPOROTRICOSE E HIV .....</b>	<b>45</b>
<b>6. CAPÍTULO 3 – INFLUÊNCIA GENOTÍPICA E VIRULÊNCIA FÚNGICA NAS APRESENTAÇÕES CLÍNICAS .....</b>	<b>74</b>
<b>7. DISCUSSÃO .....</b>	<b>116</b>
<b>8. CONCLUSÕES .....</b>	<b>126</b>
<b>9. PERSPECTIVAS .....</b>	<b>127</b>
9.1. DIAGNÓSTICO E CONTROLE DA ESPOROTRICOSE .....	127
9.2. ATUAÇÃO PROFISSIONAL FRENTE À ESPOROTRICOSE .....	127
<b>REFERÊNCIAS BIBLIOGRÁFICAS .....</b>	<b>128</b>
<b>ANEXOS .....</b>	<b>143</b>
ANEXO A – PARECER CONSUBSTANCIADO DO COMITÊ DE ÉTICA .....	144
ANEXO B – TERMO DE COMPROMISSO E RESPONSABILIDADE .....	146
<b>APÊNDICE .....</b>	<b>147</b>
APÊNDICE A – Certificado em Congresso Internacional: Melhor Pôster .....	148



## 1. INTRODUÇÃO

### 1.1. REVISÃO DA LITERATURA

#### 1.1.1. HISTÓRICO

A esporotricose foi descrita inicialmente por Schenck em 1898, nos Estados Unidos da América (EUA), em um paciente de 36 anos com abscesso no dedo indicador e linfangite nodular no antebraço. O fungo isolado foi estudado pelo micologista Erwin F. Smith, que concluiu pertencer ao gênero *Sporotrichum* (Schenck, 1898). Em 1900, no mesmo país, Hektoen e Perkins descreveram outro caso, que regrediu espontaneamente. Os autores deram ao isolado a denominação atual do fungo, *Sporothrix schenckii*. A partir de 1903 a doença foi descrita na França por Beurmann e Ramond. O fungo isolado foi chamado *Sporotrichum beurmanni* por Matruchot e Ramond, em 1905 (Rippon, 1988). Em 1907 foi identificado no Brasil, por Lutz e Splendore, o primeiro caso de infecção natural em animais (ratos) (Lutz; Splendore, 1907). Em 1910, Matruchot renomeia o fungo como *Sporothrichum schenckii*, nomenclatura que passou a ser utilizada. Terra e Rabelo descreveram o primeiro caso de esporotricose no Rio de Janeiro em 1912 e, desde então, casos isolados vêm sendo descritos em várias regiões do país (Donadel et al., 1993). A suscetibilidade de gatos para a infecção por *S. schenckii* foi demonstrada experimentalmente em 1909 (de Beurmann et al., 1909). No entanto, a esporotricose felina naturalmente adquirida foi apenas relatada no início dos anos 50 por Singer e Muncie (1952), enquanto no Brasil isto se deu em 1956 (Freitas et al., 1956).

Em 1962, por diferenciação morfológica, Carmichael determinou que a correta nomenclatura do agente da esporotricose fosse *Sporothrix schenckii* (Rippon, 1988).

No início do século XX a doença apresentava maior prevalência nos EUA e na França, com alguns casos no restante da Europa, América do Sul, Rússia e Extremo Oriente (Rippon, 1988). Desde então, diversos surtos foram documentados em vários países: África do Sul (Helm; Berman, 1947), EUA (CDC, 1988; Dooley et al., 1997), Austrália (Feeney et al., 2007), China (Song et al., 2013). Atualmente a doença tem se tornado mais frequente nas Américas Central e do Sul e na Ásia, com alguns casos na Europa. No Brasil é a micose subcutânea mais frequente (Rippon, 1988; Kwon-Chung; Bennett, 1992; Lacaz, 2002; Barros et al., 2004; da Rosa et al., 2005; Verma et al., 2012; Song et al., 2013). Em 2007, após análise fenotípica e

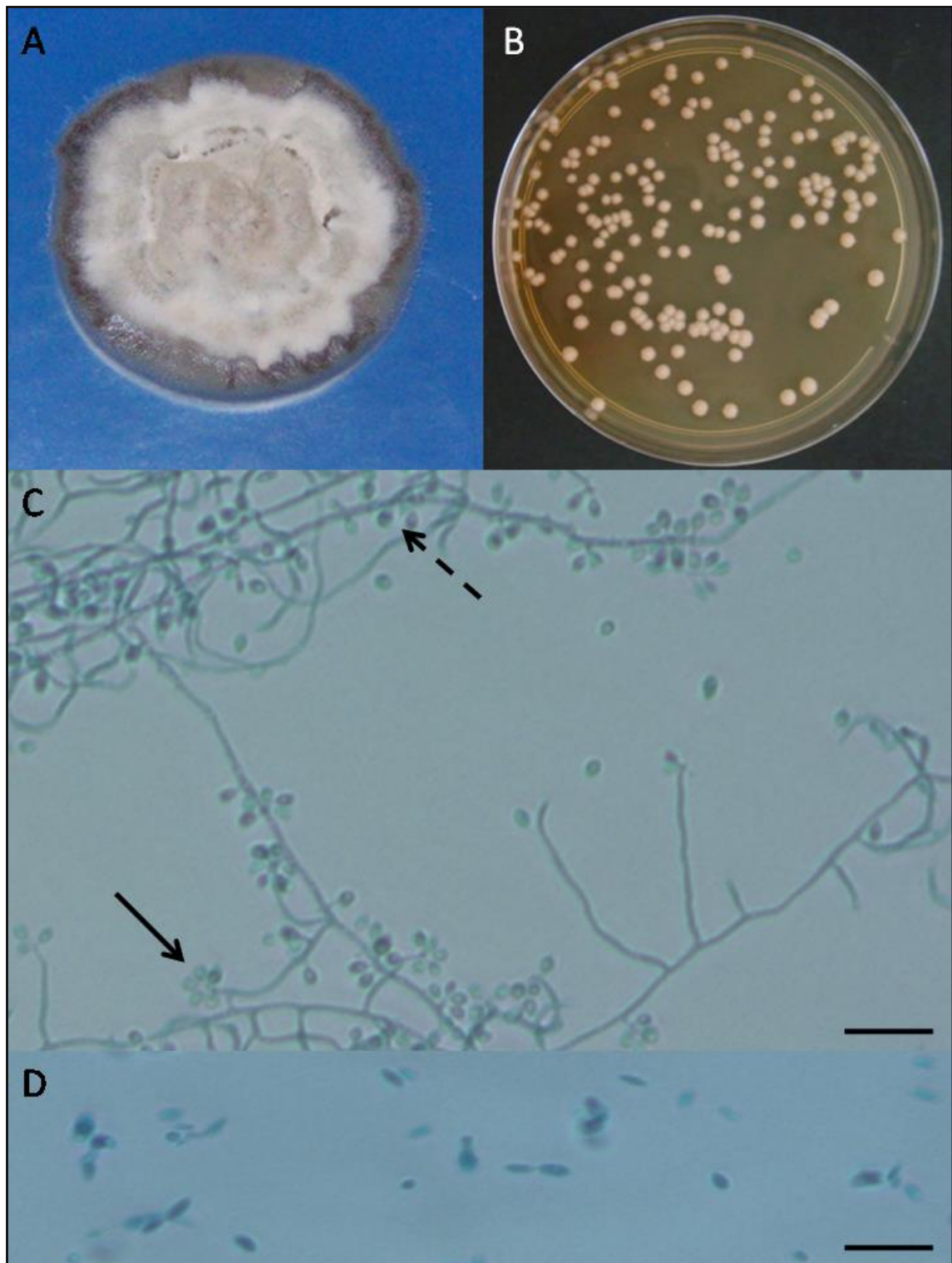
genotípica de diversos isolados obtidos em diferentes países, foi proposta uma divisão do agente *Sporothrix schenckii* em um complexo, composto por diferentes espécies patogênicas (Marimon et al., 2007).

### 1.1.2. O AGENTE

As espécies do complexo *Sporothrix schenckii* pertencem ao Reino Fungi, Divisão Ascomycota, Classe Pyrenomycetes, Ordem Ophiostomatales, Família Ophiostomataceae. São organismos eucarióticos, heterotróficos, sem mobilidade própria e com parede celular quitinosa e rígida. Vivem saprofiticamente na natureza e são patogênicas para os seres humanos e os animais (Guarro et al., 1999).

São fungos dimórficos que, na fase saprofítica ou quando cultivados a 25°C em meios como Agar Extrato de Malte ou Agar Batata Dextrose, apresentam colônias inicialmente com cor branca que assumem gradativamente uma coloração marrom a preta, ao formar conídios escuros (Figura 1A) (Kwon-Chung; Bennett, 1992). Algumas cepas, no entanto, têm a capacidade de formar colônias escuras desde o início do crescimento (Zancopé-Oliveira et al., 2011). As colônias de *Sporothrix* spp. na forma filamentosa nunca se tornam cotonosas ou flocosas (Kwon-Chung; Bennett, 1992). Microscopicamente, apresentam hifas hialinas septadas e conídios unicelulares demáceos ou não, sésseis ou dispostos em conidióforos (Figura 1C) (St-Germain; Summerbell, 1996). Em parasitismo ou em cultivo a 35-37°C, *Sporothrix* spp. apresentam colônias de coloração bege amarelada e aspecto cremoso (Figura 1B) (Rippon, 1988). Microscopicamente se apresentam sob a forma de leveduras unicelulares ovaladas, globosas ou em forma de charuto, podendo ter um ou mais brotamentos (Figura 1D) (Zancopé-Oliveira et al., 2011). A transição da forma filamentosa para a leveduriforme em *Sporothrix* spp. pode ser alcançada por meio da cultura de fragmentos de micélios e conídios em meios de cultura ricos, como Agar infusão de cérebro e coração (BHI - *Brain Heart Infusion*) a 35-37°C. Esse processo de transição também ocorre quando os pacientes são infectados com *Sporothrix* spp. na forma filamentosa. A transformação morfológica em nível ultraestrutural ocorre por formação direta de brotamentos nas pontas e ao longo das hifas em conjunto com a formação de células arredondadas após septação das hifas, sem alterações visíveis do conteúdo citoplasmático da célula-mãe micelial. Acredita-se não haver brotamento direto de leveduras a partir dos conídios, sendo

que estes se alongam formando hifas e daí, surgem as leveduras (Howard, 1961; Garrison et al., 1975).



**Figura 1:** Morfologia de *Sporothrix* spp. (A): colônia filamentosa em Agar Batata Dextrose após 21 dias de incubação a 25°C. (B): colônias leveduriformes em Agar infusão de cérebro e coração após 10 dias de incubação a 36°C. (C): microcultivo da forma filamentosa corado com lactofenol azul de algodão (aumento de 400X). Seta contínua indica conidióforo simpodial e seta tracejada indica conídio demáceo. (D): Microscopia de células leveduriformes coradas com lactofenol azul de algodão apresentando brotamentos em forma de charuto (aumento de 400X). Barras: 10 µm. (Extraído de Almeida-Paes, 2012)

O desenvolvimento de métodos moleculares baseados na detecção de ácido desoxirribonucleico (DNA) para identificação de isolados fúngicos poderá promover uma redução no tempo do diagnóstico, mantendo ou melhorando a especificidade, sensibilidade e precisão quando comparado à cultura fúngica (Oliveira et al., 2014a). Poucos métodos moleculares têm sido aplicados na detecção de DNA de *Sporothrix* spp. a partir de espécimes clínicos e na identificação de *Sporothrix* spp. em cultura. O estudo pioneiro utilizando a metodologia de detecção de DNA para o diagnóstico de infecções fúngicas foi relatado por Sandhu et al. (1995), no qual os autores desenvolveram 21 *primers* específicos com alvo para a grande subunidade do ácido ribonucleico ribossomal (rRNA) de diversos fungos, incluindo *Sporothrix* spp. Os resultados apresentaram um alto nível de especificidade (Sandhu et al., 1995). Estudos prévios utilizando a análise do DNA mitocondrial apresentaram heterogeneidade de perfis em cepas de *Sporothrix* spp. (Suzuki et al., 1988; Takeda et al., 1991). Diversos estudos taxonômicos moleculares utilizando diferentes metodologias, como a *restriction fragment length polymorphism* (RFLP) de diferentes genes alvos, *random amplified polymorphic DNA* (RAPD), sequenciamento do DNA da região de transcrição interna do rRNA (ITS), reação em cadeia da polimerase (PCR) com alvo no gene da enzima topoisomerase II, *amplified fragment length polymorphism* (AFLP), e M13 PCR *fingerprinting* demonstraram que isolados de *S. schenckii lato sensu* apresentavam polimorfismos, sugerindo que poderiam não ser apenas uma espécie (Oliveira et al., 2014a).

Em 2007, Marimon et al. sugeriram que *S. schenckii* não deveria ser considerada a única espécie causadora da esporotricose, uma vez que por meio da combinação de características fenotípicas (macroscopia da colônia, microscopia dos conídios, assimilação de sacarose e rafinose, capacidade de crescer a 37°C) e genotípicas (sequenciamento parcial do gene da calmodulina), uma chave de identificação foi desenvolvida. Esses autores propuseram a criação de três novas espécies:

- a. *S. brasiliensis* - espécie relacionada à epidemia zoonótica de esporotricose no estado do Rio de Janeiro, Brasil (Marimon et al., 2007; Oliveira et al., 2011);
- b. *S. globosa* - espécie pouco virulenta e mundialmente distribuída (Madrid et al., 2009; Oliveira et al., 2010; Cruz et al., 2012) e
- c. *S. mexicana* - encontrada em certas amostras ambientais do México e casos de esporotricose na Europa e no Brasil (Marimon et al., 2007; Dias et al., 2011; Rodrigues et al., 2013a).

Essas foram associadas às demais espécies já existentes *S. schenckii* e *S. albicans*, recentemente renomeada como *S. pallida* (de Meyer et al., 2008). A espécie *S. pallida* apresenta uma característica peculiar que é a presença apenas de conídios hialinos. Posteriormente, Marimon et al. sugeriram que *S. schenckii* var. *luriei* deveria, também, ser considerada uma nova espécie, *S. luriei*, após estudos baseados na mesma metodologia proposta um ano antes (Marimon et al., 2008a).

Até o presente não se conhece o teleomorfo do gênero *Sporothrix*, embora haja fortes evidências moleculares de que estes fungos sofram mecanismos de recombinação na natureza (Mesa-Arango et al., 2002) e possuam genes relacionados à reprodução sexuada (Kano et al., 2013).

Outra espécie fora do complexo de espécies de *Sporothrix* patogênicas, *S. cyanescens*, foi isolada de amostras de sangue e pele de pacientes humanos, mas estudos de patogenicidade concluíram que, embora este fungo possa crescer a 37°C, ele não é virulento (Sigler et al., 1990).

Também foram descritas, por de Meyer et al. (2008), três outras espécies ambientais do gênero *Sporothrix*: *S. stylites*, *S. humicola* e *S. lignivora*. As duas primeiras espécies diferem de *S. schenckii* pela incapacidade de produzir conídios melanizados e conseqüente não-escurecimento das colônias com o tempo. *S. lignivora* tem conídios distintos que não correspondem em tamanho ou forma aos de outras espécies de *Sporothrix* ou espécies do gênero *Ophiostoma*. É interessante notar que os isolados classificados como *S. humicola* eram anteriormente referidos como isolados ambientais de *S. schenckii*. Em seu estudo, os autores concluíram que a análise da sequência de  $\beta$ -tubulina é fortemente recomendada nos estudos taxonômicos das espécies de *Sporothrix* isoladas do meio ambiente.

Baseados nos estudos de Marimon et al. (2007, 2008a), Romeo et al. (2011) analisaram a filogenia molecular e epidemiologia das espécies de *Sporothrix* isoladas na Itália, demonstrando 26 cepas ambientais identificadas como *S. albicans*, e dois isolados clínicos como *S. schenckii*. Uma análise filogenética baseada no rDNA e no gene da  $\beta$ -tubulina de *S. albicans*, *S. pallida* e *S. nivea* revelou grande semelhança entre as três espécies, sendo proposto que fossem classificadas como *S. pallida*. Os autores demonstraram também que a análise do sequenciamento parcial da  $\beta$ -tubulina é recomendada em estudos taxonômicos de *Sporothrix* spp. isoladas do ambiente (de Meyer et al., 2008). A análise do sequenciamento parcial da  $\beta$ -tubulina, permitiu a descrição mais detalhada de outras

duas espécies ambientais de *Sporothrix*: *S. brunneoviolacea* e *S. dimorphospora* (Madrid H et al., 2010).

Oliveira et al. (2012) descreveram uma PCR *fingerprinting* utilizando o *primer* universal T3B, para distinguir as espécies do complexo *Sporothrix schenckii*: *S. brasiliensis*, *S. globosa*, *S. mexicana* e *S. schenckii*. Essa metodologia gerou padrões de bandas distintos, permitindo a correta identificação de isolados clínicos em nível de espécie, confirmados pelo sequenciamento parcial do gene da calmodulina. Esta metodologia é simples, confiável, rápida e de baixo custo, sendo um sistema de identificação ideal para utilização em laboratórios clínicos de micologia que não disponham de recursos para o sequenciamento de DNA.

### **1.1.3. FATORES DE VIRULÊNCIA**

Pode-se definir fator de virulência como um recurso que permite a um microrganismo sobreviver e muitas vezes ampliar seu crescimento no hospedeiro. A origem da virulência microbiana tem sido o objetivo principal de vários estudos. Em geral, a teoria mais aceita é que, por interações microbianas com outros organismos presentes no habitat natural do patógeno, os microrganismos adquirem estratégias de sobrevivência que levam o micróbio a ter uma maior virulência quando acidentalmente encontrarem um hospedeiro animal (Casadevall, 2012). Por exemplo, esses microrganismos, no hospedeiro mamífero, normalmente têm a capacidade de formar biofilmes, possuem mecanismos para a aquisição de ferro e produzem enzimas proteolíticas que levam a uma maior virulência (Casadevall, 2006).

Pouco se sabe sobre os fatores de virulência de *Sporothrix* spp. devido à escassez de estudos neste campo, em parte porque não é possível realizar estudos genéticos clássicos em *Sporothrix* spp., já que seu teleomorfo é desconhecido. No entanto, alguns prováveis fatores de virulência têm sido propostos em algumas investigações, como discutido a seguir.

#### **1.1.3.1. TERMOTOLERÂNCIA**

Um dos fatores de virulência de *Sporothrix* spp., bem como de outros fungos patogênicos, é a termotolerância, ou seja, a capacidade dos fungos em suportar e crescer na temperatura corpórea dos hospedeiros endotérmicos (Hogan et al.,

1996). Na verdade, os isolados de *Sporothrix* spp. capazes de crescer a 35°C, mas não a 37°C são incapazes de causar esporotricose linfática, produzindo lesões cutâneas fixas. Os fungos isolados de formas linfáticas, disseminadas e de lesões extracutâneas apresentam tolerância e crescimento a 37°C (Kwon-Chung; Bennett, 1992; Tachibana et al., 1998; Mesa-Arango et al., 2002).

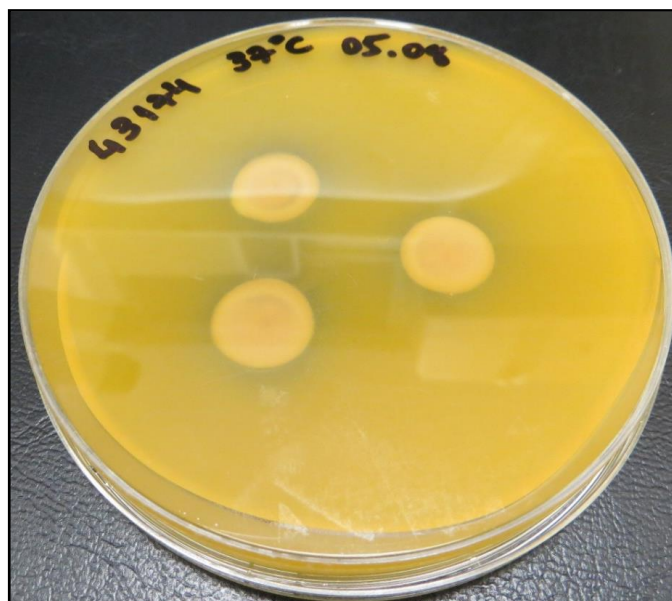A espécie *S. globosa* tem baixa termotolerância, apresentando grande inibição do seu crescimento quando incubada a 37°C (Marimon et al., 2007). Esta mesma espécie, quando inoculada em camundongos, é a que apresenta menor virulência quando comparada às demais espécies do complexo, não matando os animais e apresentando baixa carga parasitária e inflamação local nos camundongos infectados, independentemente do tamanho de inóculo utilizado (Arrilaga-Moncrieff et al., 2009). A infecção humana por esta espécie, no entanto, não aparenta ser diferente das demais, necessitando de tratamento para sua resolução (Oliveira et al., 2010, 2014b).

#### **1.1.3.2. ATIVIDADE PROTEOLÍTICA**

Proteases e outras enzimas como lipases e urease facilitam a adesão e penetração de fungos nas células e tecidos do hospedeiro, propiciando maior capacidade de invasão e disseminação da infecção, além de conferir evasão do sistema imune hospedeiro. Esta atividade enzimática também aumenta a biodisponibilidade de nutrientes essenciais, em meio à escassez (Abi-chacra et al., 2013). Há formas distintas de se demonstrar sua produção, sendo a degradação de uma forma cromogênica de albumina, uma delas (Figura 2).

A produção de proteases extracelulares foi relatada em leveduras do complexo *Candida parapsilosis* (Abi-chacra et al., 2013). Essas proteases secretadas têm papel reconhecido na virulência de espécies patogênicas do gênero *Candida*, sendo que a ausência na sua produção pode acarretar perda desta patogenicidade, marcada por incapacidade em sobreviver no soro e dentro dos macrófagos humanos. Já foi proposto que também possam contribuir para o descolamento das leveduras de *C. parapsilosis* aderidas em biofilmes (Tavanti et al., 2010). Almeida-Paes (2012) demonstrou a atividade proteolítica a 37°C em todos os 15 isolados analisados (14 *S. brasiliensis* e 1 *S. schenckii*) obtidos de pacientes oriundos da região hiperendêmica para esporotricose do Rio de Janeiro. Entretanto, apenas 3 isolados, todos da espécie *S. brasiliensis*, apresentaram esta atividade a

30°C. Esse autor não conseguiu relacionar a produção de proteases às diferentes formas clínicas de esporotricose observadas no Rio de Janeiro.



**Figura 2:** Produção de protease por *S. brasiliensis*. O halo de degradação da azoalbumina no agar é observado ao redor das colônias, com perda da pigmentação amarelo-ouro característica desta proteína cromogênica e que evidencia a atividade proteolítica.

#### 1.1.3.3. PRODUÇÃO DE UREASE

Urease é um importante fator de virulência estudado em *Coccidioides posadasii*, e é responsável pela alcalinização do pH do microambiente externo das esférulas, contribuindo para o dano tecidual e para exacerbar a infecção (Mirbod-Donovan et al., 2006). Esta enzima também é um importante fator de virulência em *Cryptococcus neoformans* (Figura 3), permitindo a transmigração do fungo para o parênquima cerebral, num processo que pode ser inibido pela flurofamida, um inibidor da enzima urease (Shi et al., 2010).



**Figura 3.** Produção de urease. Alcalinização do caldo de ureia de Christensen promove alteração de sua cor laranja para o róseo, evidenciando a atividade ureásica das cepas de *C. neoformans*. *Candida parapsilosis* não altera a coloração laranja, pois não degrada a ureia do meio (tubo à direita). (Gentilmente cedido por Luã Cardoso, Mestrando em Doenças Infecciosas - IPEC).



As colônias de *Sporothrix* spp. (então consideradas *S. schenckii*) obtidas de espécimes clínicos no Canadá foram urease negativas após sete dias, e tornaram-se urease positivas ao décimo-quarto dia (Sigler et al., 1990). Em estudo realizado com leveduras de *Sporothrix* oriundas da Índia mostraram que nenhum dos 49 isolados testados foi capaz de degradar ureia, somente havendo produção de urease na forma filamentosa (Ghosh et al., 2002). Entretanto, outros estudos verificaram variação na produção de urease (Marimon et al., 2007), e alta produção de urease após quatro dias de incubação em isolados de *S. brasiliensis* do Rio de Janeiro, frente a isolados de *S. schenckii* (Almeida-Paes, 2012).

#### **1.1.3.4. ADESINAS**

Adesão primária a células endoteliais e epiteliais, bem como aos componentes da matriz extracelular é essencial para uma invasão efetiva dos tecidos do hospedeiro por patógenos. Tanto as células de levedura como os conídios de *Sporothrix* spp. são capazes de reconhecer três importantes glicoproteínas da matriz extracelular: fibronectina, laminina e colágeno do tipo II (Lima et al., 1999, 2001). Alguns estudos demonstram que o fungo apresenta integrinas ou adesinas semelhantes a lectinas que reconhecem a fibronectina humana em vários pontos da molécula (Lima et al., 2001). As moléculas de adesão à fibronectina estão localizadas na superfície de células de levedura e sua expressão está relacionada com a virulência do fungo (Teixeira et al., 2009). Sabe-se também que esses receptores para fibronectina são diferentes dos receptores de laminina. Ambos estão presentes tanto em leveduras como nas hifas de *Sporothrix* spp., apesar das leveduras terem maior capacidade de se ligar à matriz extracelular. A existência destas adesinas favoreceria a adesão para infectar os tecidos e também a disseminação do fungo pelo corpo (Lima et al., 2004). A expressão destas moléculas em *Sporothrix* spp. está provavelmente relacionada à virulência, já que a sua expressão preferencial se dá na forma parasitária e não na forma saprofítica do fungo. Uma glicoproteína de 70kDa obtida de um isolado de *S. schenckii* foi descrita, e sua participação na adesão à matriz extracelular dérmica foi demonstrada (Ruiz-Baca et al., 2009).

#### **1.1.3.5. OUTRAS PROTEÍNAS**

O papel de diversas proteínas relacionadas à virulência de diferentes fungos patogênicos tem sido elucidado. No entanto, a função de diferentes proteínas de

*Sporothrix* spp. na virulência deste patógeno ainda é incerta. Acredita-se que fosfatases ácidas tenham algum papel na interação entre fungos e macrófagos, embora não haja evidências definitivas para apoiar esta teoria (Hogan et al., 1996). Peptido-ramnomanas da parede celular de *Sporothrix* spp. causam depressão da resposta imune até a sexta semana de infecção e podem agir como fator de virulência (Carlos et al., 1998).

#### **1.1.3.6. PERÓXIDO DE ERGOSTEROL**

Uma análise dos lipídios de *Sporothrix* spp. utilizando métodos espectroscópicos identificou peróxido de ergosterol em leveduras. Este composto pode ser convertido em ergosterol quando em contato com uma enzima extraída do fungo. O peróxido de ergosterol foi encontrado em um fungo patogênico pela primeira vez em *Sporothrix* spp., e age como um mecanismo de proteção para escapar de espécies reativas de oxigênio durante a fagocitose e também pode representar um fator de virulência. Aparentemente, no entanto, a sobrevivência de leveduras virulentas de *Sporothrix* spp. após a fagocitose por polimorfonucleares hospedeiros é baseada, além desta, em outras estratégias de escape (Sgarbi et al., 1997; Carlos et al., 2009).

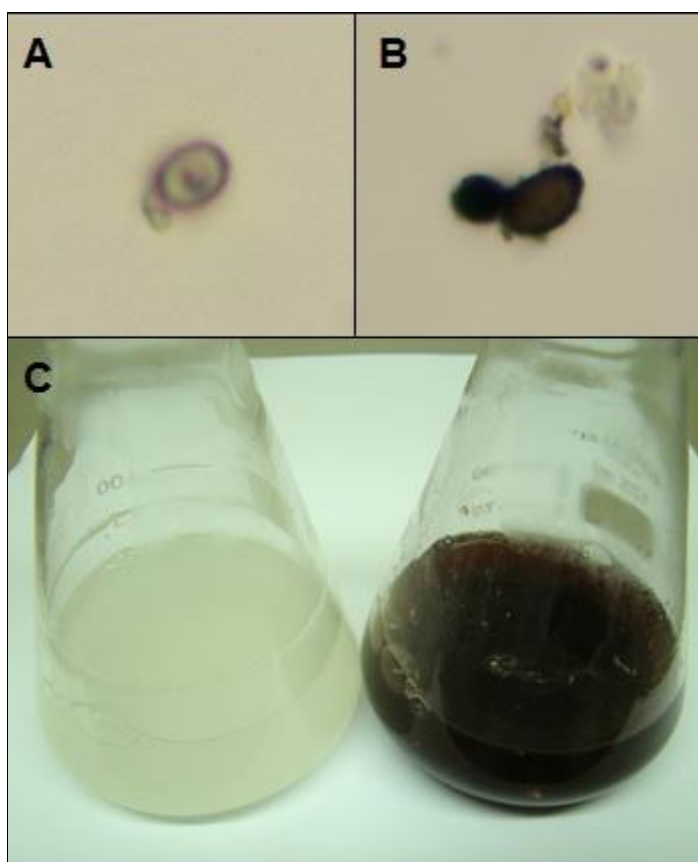
#### **1.1.3.7. MELANINA**

Melaninas são pigmentos ubíquos produzidos por uma ampla gama de organismos vivos, desde bactérias aos seres humanos (Riley, 1997; Nosanchuk; Casadevall, 2003). Elas apresentam tipicamente cor marrom-escura ou negra (Liu; Nizet, 2009) e possuem um alto peso molecular (Hamilton; Gomez, 2002). Melaninas são sintetizadas por várias vias metabólicas, todas convergindo para a polimerização oxidativa de compostos fenólicos ou indólicos (Gomez; Nosanchuk, 2003; Nosanchuk; Casadevall, 2006). Algumas das propriedades físicas e químicas das melaninas incluem uma carga negativa, hidrofobicidade e insolubilidade em ambos solventes aquosos e orgânicos (Jacobson, 2000).

Até o momento, nenhuma estrutura definitiva foi encontrada para qualquer um dos tipos de melanina por causa de sua insolubilidade, o que torna os estudos sobre melaninas muito difíceis (Riley, 1997; Nosanchuk; Casadevall, 2006). Em geral, melaninas fúngicas são estudadas após a digestão de células com enzimas proteolíticas e glicolíticas, seguida de extração com agentes desnaturantes e ácido concentrado quente. Este tratamento produz partículas escuras mantendo a forma

celular original, mas desprovidas de citoplasma ou organelas, e que são referidas como “fantasmas” de melanina (Wang et al., 1996).

Vários tipos de melaninas podem ser encontrados na natureza. O principal tipo de melanina encontrado dentro do Reino Fungi é a melanina 1,8-di-hidroxi naftaleno (DHN) (Figura 4A) sintetizada a partir de acetil-coenzima A (CoA) ou malonil-CoA por vias de produção de policetídeos (Wheeler; Bell, 1988; Langfelder et al., 2003). É importante observar que, uma vez que a biossíntese deste tipo de melanina começa com um produto de vias metabólicas celulares essenciais, como a glicólise e via das pentoses fosfato, a melanina-DHN pode ser sintetizada sem a presença de qualquer precursor no ambiente de crescimento dos fungos. Outros tipos de melaninas fúngicas são sintetizados apenas se um precursor específico estiver presente durante o crescimento do fungo. O precursor mais comum para a síntese de melaninas fúngicas é a L-tirosina. Dois tipos de melanina podem ser formados na presença deste aminoácido: eumelanina (Figura 4B) e piomelanina (Figura 4C) (semelhante ao pigmento humano alcaptomelanina) (Almeida-Paes et al., 2012a).



**Figura 4.** Três tipos distintos de melanina produzidos por *Sporothrix* spp. A) melanina DHN evidenciando o contorno de um conídio; B) eumelanina produzida por leveduras na presença de L-DOPA e C) piomelanina produzida por leveduras em meio adicionado com L-tirosina à direita; o frasco à esquerda continha leveduras mortas e foi usado como controle. (Fotografias extraídas de Almeida-Paes, 2012)

Ambas morfologias de *Sporothrix* spp. têm a capacidade de sintetizar melanina. A produção de melanina em conídios demáceos de *Sporothrix* spp. ocorre pela via DHN (Romero-Martinez et al., 2000). Macroscopicamente, apenas a fase miceliana do fungo é melanizada, no entanto a produção de melanina em leveduras foi demonstrada *in vitro* e durante a infecção. A formação de melanina DHN, sem adição de precursores, foi observada somente em leveduras e conídios. Hifas, quando tratadas com enzimas, agentes desnaturantes e ácido quente, são totalmente digeridas sem que restem partículas compatíveis com DHN (Morris-Jones et al., 2003).

A melanização dos conídios aumenta a sua resistência à fagocitose por macrófagos (Romero-Martinez et al., 2000). Melanização também tem importância na patogênese da esporotricose cutânea, uma vez que amostras pigmentadas selvagens de *S. schenckii* apresentaram maior capacidade invasiva do que uma cepa mutante albina em um modelo experimental de esporotricose em ratos (Madrid I et al., 2010a). Melanização *in vivo* foi confirmada pelo isolamento de partículas de melanina a partir de tecidos de animais infectados por *Sporothrix* spp. e pela detecção de anticorpos reativos contra melanina em soros de pacientes humanos com esporotricose (Morris-Jones et al., 2003).

#### **1.1.4. EPIDEMIOLOGIA**

O agente da esporotricose vive no solo, geralmente associado a vegetais, podendo ser isolado, além do solo, de plantas, palha, insetos mortos, entre outros. É patogênico para os homens e os animais (Rippon, 1988; Kwon-Chung; Bennett, 1992).

Alguns animais têm sido relacionados à transmissão zoonótica de *Sporothrix* spp. Os animais mais comumente descritos são os gatos, que desenvolvem a doença, muitas vezes com quadros graves e evolução para o óbito, veiculando o parasita pela arranhadura, mordedura e exsudato de lesões. No meio silvestre, os tatus podem apresentar a infecção e atuar como transmissores do fungo pela arranhadura, apesar do fungo não ter sido ainda isolado de sua epiderme. Outros casos humanos relatados têm sido associados a picadas de mosquitos, abelhas, cobras, bicadas de papagaios ou mordidas de ratos, cavalos, cachorros e peixes. Os indivíduos que por profissão ou hábitos de vida lidam com essas situações são os

mais predispostos à infecção como floristas, jardineiros, fazendeiros, horticultores, mineiros, feirantes, veterinários e tratadores de animais (Rippon, 1988; Kwon-Chung; Bennett, 1992; Schubach; Schubach, 2000; Schubach et al., 2001; Lacaz, 2002; Barros et al., 2004). A esporotricose tem distribuição mundial, sendo mais frequente em regiões de clima tropical e temperado. É provável que muitos países com alto potencial de número de casos não os relatem internacionalmente e talvez nem cheguem ao diagnóstico definitivo, o que leva a números subestimados da doença no mundo. Nos últimos anos, as maiores casuísticas foram de Brasil, China, Índia, Japão, México, Peru e Uruguai (Barros et al., 2011a).

Diversos surtos foram documentados em vários países, mas a maior epidemia no século XX ocorreu na África do Sul onde, entre os anos de 1941 e 1944, cerca de 3.000 mineradores de ouro foram infectados pelo fungo presente nas vigas de madeira de sustentação dos túneis das minas (Helm; Berman, 1947). Nos EUA, especialmente no vale do Mississipi, foram descritos surtos relacionados ao trabalho em florestas, com mudas de pinheiro e manipulação de musgo (CDC, 1988). Entre os anos de 1992 e 1993, também nos EUA, ocorreu uma microepidemia de esporotricose pela contaminação de pessoas pelo feno estocado em uma casa abandonada, onde se realizavam festas de *Halloween* (Dooley et al., 1997). No Sudoeste da Austrália entre os anos de 2000 e 2003 houve um surto tendo novamente o feno como material contaminado (Feeney et al., 2007). No nordeste da China, atualmente há um aumento no número de casos de esporotricose, com publicação de 457 casos humanos entre os anos de 2007 e 2009 (Song et al., 2013). Estudos genotípicos de alguns isolados desta epidemia apontam *S. globosa* como a espécie responsável pelos casos, sendo a manipulação de gravetos para aquecimento domiciliar nos meses de inverno, a forma de aquisição da doença (Yu et al., 2013; Liu et al., 2014). Esta região epidêmica já ultrapassou 2.000 casos, segundo informações obtidas durante o 1º Encontro Internacional de *Sporothrix* e Esporotricose, realizado na cidade do Rio de Janeiro em outubro de 2013 (Li et al., 2013). As maiores casuísticas brasileiras com a transmissão clássica pelo solo ou matéria orgânica são provenientes dos estados de São Paulo, com 235 casos humanos confirmados até o ano de 1953 (Sampaio et al., 1954) e Rio Grande do Sul, com 646 casos humanos acumulados em diferentes casuísticas entre os anos 1957 e 2002 (Londero; Ramos, 1989; Lopes et al., 1999; da Rosa et al., 2005).

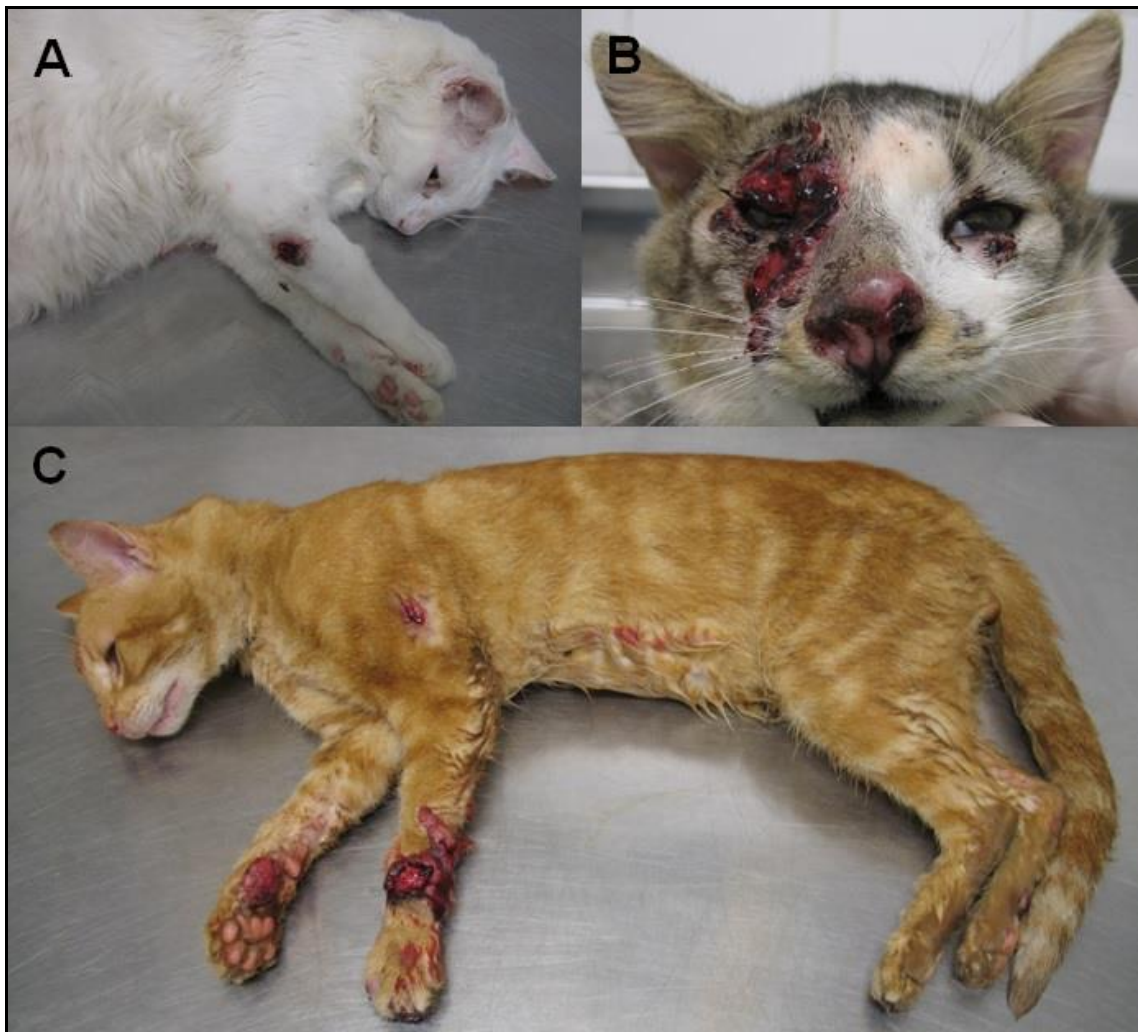O papel do gato na transmissão zoonótica de esporotricose ganhou importância a partir dos anos 80, quando Read e Sperling (1982) relataram um surto

envolvendo cinco pessoas expostas a um gato com esporotricose. Desde então, pequenos surtos de transmissão zoonótica foram documentados. No Brasil, os principais surtos descritos tinham ocorrido no estado de São Paulo, envolvendo 4 gatos domésticos e 3 humanos (Marques et al., 1993) e no Rio Grande do Sul, com envolvimento de 15 gatos e 3 humanos (Madrid I et al., 2010b), ambos surtos de pequena monta e com rápido controle.

No Rio de Janeiro, o que inicialmente era considerado mais um surto assumiu proporções maiores e, hoje, já com mais de 15 anos desde o aumento no número de casos de esporotricose intimamente atribuída à transmissão por gatos (domésticos ou errantes), vivemos uma epidemia, ou mesmo, uma hiperendemia de esporotricose (Freitas et al., 2010). O potencial zoonótico do gato foi demonstrado em um estudo com a presença de *Sporothrix* em diferentes espécimes clínicos coletados tanto de gatos com esporotricose, como de gatos aparentemente saudáveis (Schubach et al., 2002). Em 2004, Schubach et al. descreveram a casuística de 347 gatos com esporotricose provenientes desta epidemia e observaram um amplo espectro clínico: desde formas subclínicas a disseminadas e fatais (Figura 5). Diferente do que ocorre no ser humano, a forma linfocutânea foi menos frequente (19,3%), predominando lesões cutâneas múltiplas (39,5%) e lesões nas mucosas das vias respiratórias e digestórias superiores (34,9%) (Schubach et al., 2004). A disseminação do fungo havia sido verificada tanto pelo alto percentual de positividade em hemoculturas (34,4%), como pela observação do agente na pele e em vários órgãos internos em 10 gatos necropsiados. (Schubach et al., 2003).

Até 2011, no Laboratório de Pesquisa Clínica em Dermatozoonoses em Animais Domésticos (Lapclin-Dermzoo) do Instituto de Pesquisa Clínica Evandro Chagas (IPEC) havia registro de 3.804 gatos com esporotricose (Pereira et al., 2012). Os cães parecem não desempenhar um papel importante na cadeia epidemiológica da micose, com número bem menor de casos (120 até o ano de 2009), não tendo sido comprovada, até dezembro de 2009, a transmissão ao ser humano por esses animais (Barros et al., 2010).

Já se sabe, por estudos moleculares de alguns isolados desta epidemia, que *S. brasiliensis* é a principal espécie envolvida (Oliveira et al., 2011). Também, em outro estudo recente, comprovou-se que a espécie *S. brasiliensis* está associada aos casos felinos no Brasil (Rodrigues et al., 2013b).



**Figura 5.** Esporotricose felina. A) Lesão localizada no membro anterior direito; B) Lesões cutâneo-mucosas na face; C) Lesões cutâneas disseminadas. (Imagens gentilmente cedidas pelo Lapclin-Dermzoo/IPEC/Fiocruz)

#### 1.1.5. FISIOPATOGENIA

A infecção por *Sporothrix* spp. geralmente decorre de pequenos traumatismos com prejuízo da integridade da epiderme. Na transmissão clássica, a matéria orgânica contaminada com o fungo é inoculada por meio de gravetos, espinhos, palha ou outro veículo, por isso é comumente conhecida como “doença da roseira” ou “doença do jardineiro”. Após inoculação, o fungo alcança as camadas mais profundas, onde assumirá a forma parasitária. Nos casos associados aos animais, principalmente o gato, o traumatismo advém de arranhadura, mordedura ou mesmo de lesões traumáticas prévias, com inoculação posterior do fungo, sem trauma pelo gato. Gatos com esporotricose têm alta carga parasitária em suas lesões e, neste modo de transmissão, os humanos podem ser infectados diretamente por leveduras,

ou por hifas (Schubach et al., 2002; Barros et al., 2004). O fungo pode permanecer no tecido subcutâneo, disseminar-se para os linfáticos subjacentes e/ou por via hematogênica (Rippon, 1988; Kwon-Chung; Bennett, 1992), esta última atribuída à interação do fungo com células endoteliais do hospedeiro, como já descrito *in vitro* (Figueiredo et al., 2004). As lesões surgem de 3 dias a 12 semanas após a inoculação do agente no organismo, porém não raramente, a doença pode ter evolução subclínica e cura espontânea.

A infecção por via inalatória é tida como extremamente rara, acometendo principalmente etilistas, e determina uma forma pulmonar primária, semelhante à tuberculose em sua apresentação clínica, pois a área apical do pulmão parece ser o sítio de infecção mais frequente (Rippon, 1988).

A resposta imunológica do hospedeiro, a carga parasitária, a profundidade da inoculação e a tolerância térmica da cepa vão determinar a apresentação clínica da doença (Lopes et al., 1999). Outro fator determinante é a virulência do fungo.

#### **1.1.6. RESPOSTA IMUNE**

A virulência de *Sporothrix* spp. é um dos fatores que afetam o desenvolvimento da esporotricose, assim como a resposta imune do hospedeiro (Carlos et al., 2009). Os mecanismos imunológicos envolvidos na prevenção e no controle das infecções por *Sporothrix* spp. ainda não são muito bem compreendidos. No entanto, eles provavelmente incluem tanto a resposta imune celular como humoral (Carlos et al., 1992, 2009; Maia et al., 2006), as quais parecem ser desencadeadas por tipos distintos de antígenos de superfície celular, especialmente alguns lipídios com ação na ativação de células do sistema imune. A resposta humoral é induzida por proteínas secretadas pelo fungo, os exoantígenos, que não estão envolvidos na resposta celular (Carlos et al., 2003). A resposta imune inata também desempenha uma função protetora na patogênese da esporotricose (Carlos et al., 2009).

O sistema complemento pode ser ativado por *Sporothrix* spp., especialmente a via alternativa, embora a ativação da via clássica não possa ser excluída. A ativação do complemento pode auxiliar na fagocitose de leveduras de *Sporothrix* spp. por células do hospedeiro por deposição do componente C3b na parede celular



fúngica. Além disso, o complexo de ataque à membrana também contribui para a lise das leveduras (Torinuki; Tagami, 1985; Scott et al., 1986).

Estudos recentes enfatizam a importância de receptores do tipo Toll na esporotricose. TLR-4, também designado CD284, é uma importante molécula envolvida na ativação do sistema imune inato e na esporotricose é capaz de reconhecer moléculas de um extrato de lipídios da forma de levedura do fungo. Essa interação leva à indução de uma resposta oxidativa contra o fungo (Carlos et al., 2009). De fato, a importância de receptores do tipo Toll na esporotricose ocorre nos estágios mais iniciais da infecção, nos quais queratinócitos participam da resposta inflamatória na esporotricose reconhecendo, por receptores TLR-2 e TLR-4, tanto conídios como leveduras, em fases bem iniciais da infecção (Li M et al., 2012). Neutrófilos também participam da imunidade inata contra *Sporothrix* spp., conforme demonstrado por imunohistoquímica (Morgado et al., 2011) e por infecção experimental em camundongos com doença granulomatosa crônica (Kajiwara et al., 2004). A ação destas células provavelmente reside na produção de metabólitos oxidativos com ação fungicida e fungistática (Kajiwara et al., 2004; Barros et al., 2011a). Outros dados mostram que pacientes com a forma linfocutânea da esporotricose apresentam, por exemplo, maiores níveis de óxido nítrico sintase induzível (Morgado et al., 2011).

Imunidade adquirida contra o fungo requer a ação de macrófagos ativados. Eles podem ser ativados durante a esporotricose por linfócitos T CD4<sup>+</sup>, que liberam interferon (IFN)- $\gamma$ , um forte ativador de macrófagos (Tachibana et al., 1999), e por outras células apresentadoras de antígeno, estabelecendo uma ligação entre as respostas imunes inata e adaptativa (Carlos et al., 2009). Durante o início da infecção ocorre produção do fator de necrose tumoral (TNF)- $\alpha$ , uma citocina que age em macrófagos ativados para produzir óxido nítrico (Carlos et al., 2003), um agente oxidante que apresenta elevado efeito citotóxico contra *Sporothrix* spp. (Fernandes K et al., 2000). Esta citocina também é produzida no final da infecção, o que proporciona sua resolução total (Maia et al., 2006).

Embora o óxido nítrico seja uma molécula fungicida, este composto pode estar implicado com imunossupressão *in vivo*, porque os níveis elevados de TNF- $\alpha$  e óxido nítrico liberados após a disseminação da levedura pelos tecidos levam à síntese de moléculas que suprimem a resposta de células T, como IL-10, Fas-L e CTLA-4. Este efeito deletério do óxido nítrico ocorre apenas após a infecção inicial, tornando-se crucial algum tempo depois da inoculação do fungo (Fernandes K et al.,

2008). Na verdade, TNF- $\alpha$  tem sua produção drasticamente diminuída quatro a seis semanas após a infecção experimental, permitindo ao fungo reproduzir e infectar tecidos do hospedeiro. Uma situação oposta ocorre dois meses após a infecção, quando os níveis de IL-1 e TNF- $\alpha$  aumentam, favorecendo a eliminação do fungo (Carlos et al., 1994).

Monócitos e macrófagos, após a fagocitose de conídios e de leveduras de *Sporothrix* spp., também são fortemente induzidos a produzir formas reativas de oxigênio (Romero-Martinez et al., 2000). Esses reagentes, ânion superóxido e especialmente seus metabólitos oxidativos, também produzidos por neutrófilos, estão envolvidos nas respostas fungistática e fungicida, e sua ausência está relacionada a uma maior letalidade em infecções experimentais de camundongos (Kajiwara et al., 2004). Assim, a resposta Th1 é de grande importância na patogênese da esporotricose, atuando como fator de controle da infecção fúngica, e sua ativação diferencial leva a diferentes manifestações clínicas da doença (Uenotsuchi et al., 2006).

A resposta imune humoral na esporotricose é dirigida por IL-4 produzida por células Th2. Na esporotricose experimental, a liberação de IL-4 é reforçada cinco a seis semanas após a infecção (Maia et al., 2006), sugerindo a participação da resposta imune humoral apenas em estágios avançados da esporotricose (Carlos et al., 2009). Anticorpos podem ter algum efeito sobre o desenvolvimento de *Sporothrix* spp., já que um anticorpo monoclonal contra um antígeno glicolipídico é capaz de impedir o crescimento do fungo e sua diferenciação *in vitro* (Toledo et al., 2010). Um anticorpo monoclonal contra a adesina de 70 kDa também é protetor em um modelo murino de esporotricose (Nascimento et al., 2008), e anticorpos presentes no soro de pacientes com esporotricose são capazes de reconhecer várias isoformas de proteínas de 70 kDa (Almeida-Paes et al., 2012b). No entanto, pouco se sabe sobre os anticorpos produzidos durante o curso da esporotricose naturalmente adquirida. Tem sido descrito que camundongos infectados com *Sporothrix* spp. são capazes de produzir anticorpos da classe IgG1 e IgG3 específicos contra uma proteína de 70 kDa do fungo durante a infecção experimental, e talvez estes anticorpos estejam relacionados à eliminação do agente nesses organismos (Nascimento; Almeida, 2005). Durante o curso da esporotricose humana, nosso grupo demonstrou a produção de IgG, IgM e IgA contra exoantígenos da fase filamentosa de *Sporothrix* spp. Como pacientes com diferentes formas clínicas da esporotricose produzem quantidades similares desses anticorpos, a resposta imune humoral contra proteínas

secretadas por *Sporothrix* spp. não deve ter um papel fundamental na patogenia da esporotricose, possuindo apenas valor diagnóstico (Almeida-Paes et al., 2007a).

#### 1.1.7. FORMAS CLÍNICAS

A esporotricose afeta ambos os sexos e pode ocorrer em qualquer idade. Na maioria das vezes é uma infecção benigna restrita à pele, tecido celular subcutâneo e vasos linfáticos adjacentes (Rippon, 1988; Kwon-Chung; Bennett, 1992; Lacaz, 2002; Zancopé-Oliveira et al., 2011).

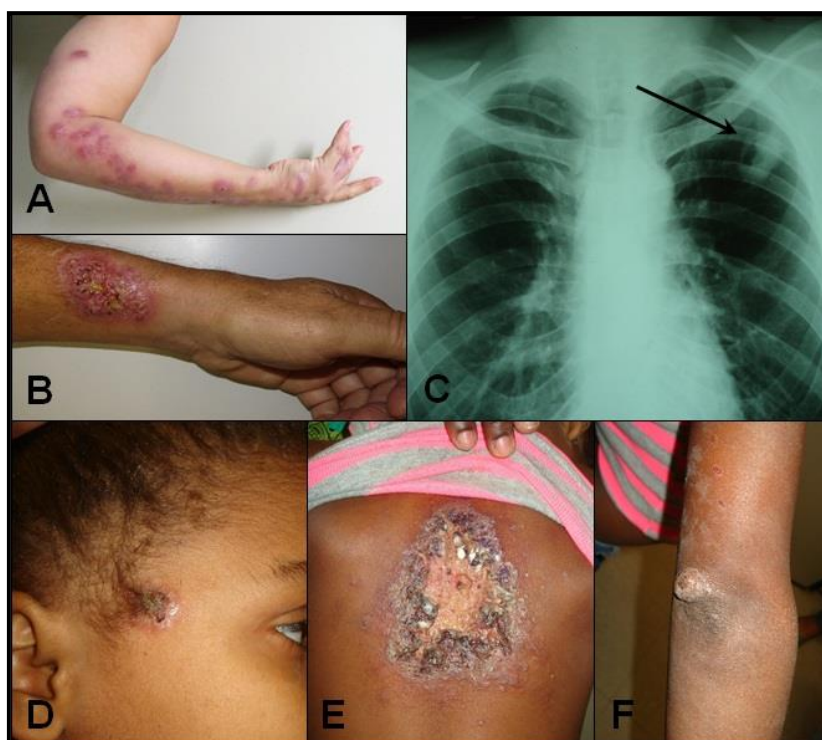Há variações nas classificações clínicas adotadas por diferentes autores e aqui será citada uma divisão em quatro formas clínicas, baseada na descrição feita por Sampaio et al. (1954):

Linfocutânea: é a apresentação mais comum e compreende até 75% dos casos, representando a forma típica e de mais fácil diagnóstico clínico de esporotricose. As lesões são localizadas geralmente nas extremidades superiores e caracterizadas por uma lesão primária que surge após dias ou semanas no local da inoculação. Pode ser ulcerada de base infiltrada, papulosa, nodular, nódulo-ulcerada, úlcero-gomosa ou placa vegetante; a partir desta lesão inicial, em trajeto dos vasos linfáticos, forma-se cadeia de nódulos indolores, que podem amolecer e ulcerar com pouco exsudato, fazendo o “aspecto esporotricóide”. Geralmente não há acometimento dos gânglios linfáticos regionais, nem alterações cutâneas entre os nódulos, mas nesta área pode ser encontrado eritema; via de regra a dor é discreta, mas quando presente costuma estar associada a aumento de eritema e supuração, o que pode evidenciar infecção secundária (Figura 6A).

Cutânea fixa: ocorre quando a lesão permanece restrita ao sítio de inoculação, sem acometimento dos vasos linfáticos e órgãos internos; é a segunda forma mais comum e abrange cerca de 20% dos casos, sendo mais frequente em crianças e indivíduos em bom estado geral. Atribui-se esta forma clínica a uma sensibilização prévia do indivíduo ao fungo, notadamente em áreas endêmicas, o que proporciona um melhor controle imunológico do hospedeiro, com limitação da lesão. Sítios comumente afetados são face, pescoço e tronco. As lesões são úlceras, placas verrucosas, acneiformes ou placas infiltradas. Pequenas lesões satélites são comuns. Este tipo clínico provoca dúvida diagnóstica frequente com piodermite, cromoblastomicose, tuberculose cutânea, micobacteriose atípica, sífilis

terciária, leishmaniose cutânea e até mesmo carcinoma cutâneo. Não infrequente ocorre involução espontânea da lesão, em contrapartida, também é uma das formas em que se encontra maior cronicidade, principalmente nas formas verrucosas exuberantes (Figura 6B).

Cutânea disseminada: atinge menos de 5% dos pacientes e acomete especialmente aqueles com comprometimento do sistema imunológico. Após inoculação através da pele, ocorre a disseminação por via hematogênica, com lesões inicialmente subcutâneas, amolecidas que, após semanas ou meses, ulceram; é bastante rara, mas tem sido descrita em pacientes com aids (síndrome da imunodeficiência humana adquirida), inclusive como primeira manifestação desta síndrome e em pacientes sem nenhuma imunodepressão aparente. Pode haver sério comprometimento do estado geral e tem curso subagudo e indolente (Donadel et al., 1993). Na transmissão por gatos, esta forma tem sido descrita com maior frequência (Figura 6D-F), e uma explicação é a ocorrência de múltiplas inoculações que o gato proporciona em um mesmo hospedeiro humano (Barros et al., 2004; Freitas et al., 2010).



**Figura 6.** Formas clínicas de esporotricose humana. A) Linfocutânea no membro superior; B) Cutânea fixa no membro superior; C) Extracutânea pulmonar (a seta aponta a cavitação no ápice do pulmão esquerdo); D-F) Cutânea disseminada (face, dorso do tronco e membro superior de uma mesma paciente).

Extracutânea: corresponde a menos de 2% dos casos e é de difícil diagnóstico. Surge após disseminação hematogênica do fungo, inalação de

conídios, contiguidade com lesão cutânea ou inoculação direta – a exemplo das regiões mucosas. Qualquer órgão ou tecido pode ser acometido pela esporotricose e os sintomas são relacionados ao órgão comprometido, acompanhados de febre e comprometimento geral em alguns casos. A quase totalidade dos pacientes com esta forma também apresenta lesão cutânea. Imunodepressão expressa por condições como diabetes, etilismo, neoplasia, corticoterapia e aids é frequente nesta forma da micose (Rippon, 1988; Kwon-Chung; Bennett, 1992; Lacaz, 2002). Algumas formas de destaque são:

- Osteoarticular: depois da pele, é o local mais frequentemente acometido. Os ossos mais afetados são tibia, ossos pequenos das mãos, rádio, ulna e ossos do crânio e da face, junto das articulações das mãos, cotovelo, punho, joelho e tornozelo. As lesões podem se apresentar como granulomas solitários ou artrite destrutiva, com grandes lesões de intensa destruição óssea e tenossinovite associada, resultando em fratura espontânea; lesões semelhantes a osteomielite e a periostite também podem aparecer. As imagens radiográficas deixam dúvida com relação à osteólise por desuso.

- Pulmonar: é mais frequente como doença primária por inalação de conídios e não consequente à disseminação do fungo. Esta infecção pode ser assintomática. Clinicamente, a esporotricose pulmonar manifesta-se como doença cavitária crônica pulmonar ou linfadenomegalia hilar maciça, esta última com certa frequência de resolução espontânea (Figura 6C). As manifestações clínicas são semelhantes às de outras micoses pulmonares, tuberculose e sarcoidose, com febre, tosse e mal-estar. Uma revisão de 86 casos relatados entre 1960 e 2010 confirmou estes achados e contabilizou 64 casos pulmonares primários e 22 multifocais, e demonstrou que hemoptise foi sinal associado à forma cavitária primária (Aung et al., 2013).

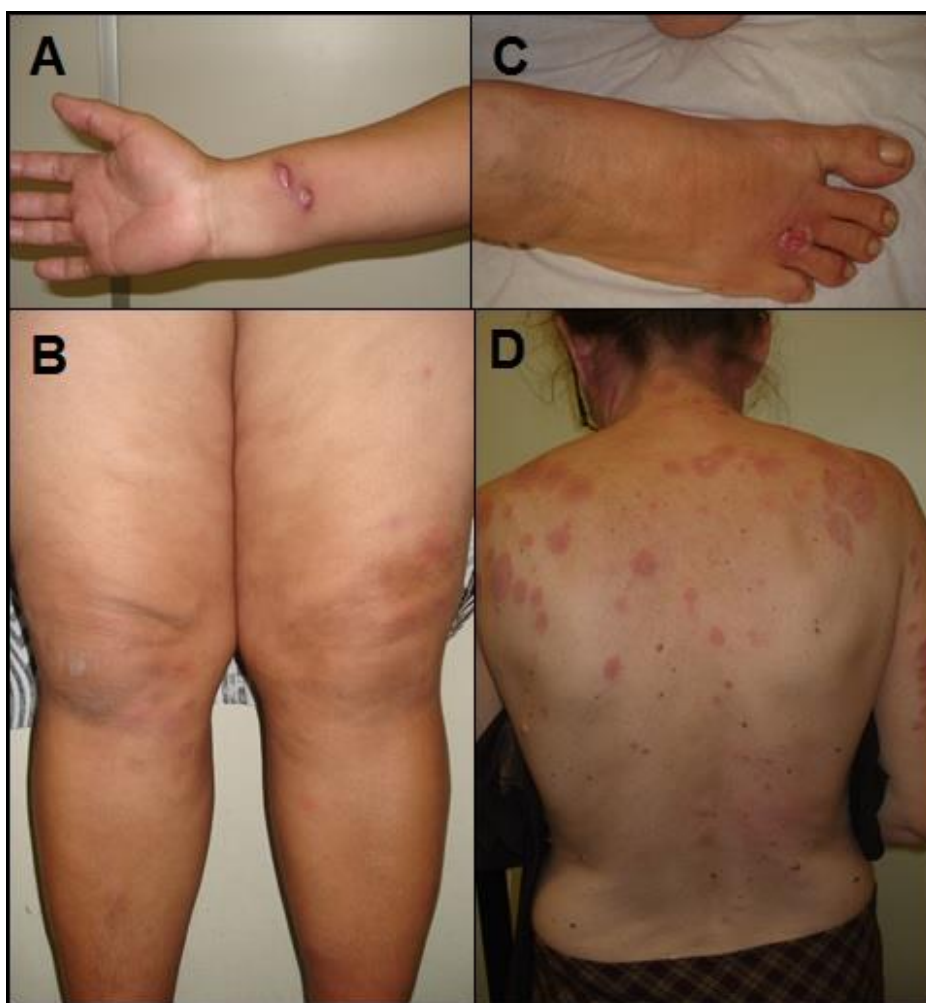- Ocular: destaca-se dentre as formas mucosas e resulta tanto da infecção exógena, como de disseminação hematogênica e pode manifestar-se como conjuntivite (com granulomas característicos visíveis de aspecto “miolo de pão”), episclerite, dacriocistite, ulceração corneal, uveíte, irite nodular, lesão retrobulbar, panoftalmite, ulceração e ectropia, levando à cegueira total em raros casos.

- Mucosa: boca, faringe, nariz e laringe são locais possíveis de acometimento tanto por via direta quanto hematogênica. Enantema, ulceração, supuração e vegetação fazem parte da clínica.

- Nervosa: abscesso cerebral ou meningite crônica podem ocorrer. A meningite é indolente, associada com hipoglicorraquia, hiperproteínorraquia e baixa

celularidade mononuclear. Uma complicação comum e potencialmente grave nestes casos é a hidrocefalia.

Condições clínicas associadas não são infrequentes no curso da esporotricose. Além dos sintomas gerais como febre, mal-estar, cefaleia, astenia, e outros já citados aqui, sinais e sintomas de hipersensibilidade ao fungo no organismo são apresentados por alguns pacientes (Barros et al., 2004, Freitas et al., 2010). As reações de hipersensibilidade descritas até o momento, atribuídas à esporotricose incluem eritema nodoso (Figura 7A-B) (Gutierrez-Galhardo et al., 2002), eritema multiforme (Figura 7C-D) (Gutierrez-Galhardo et al., 2005) e artrite reativa (Orofino-Costa et al., 2010). Nas lesões de eritema, as alterações histopatológicas são a de um infiltrado reativo e a procura do agente causador é sempre negativa (Gutierrez-Galhardo et al., 2002, 2005). Nos casos de artrite reativa, os exames de imagem não são compatíveis com lesão articular infecciosa e resolvem com o tratamento do foco da micose (Orofino-Costa et al., 2010).



**Figura 7.** Reações de hipersensibilidade associadas à esporotricose. A e B) Esporotricose linfocutânea no membro superior e eritema nodoso nos membros inferiores de uma mesma paciente; C e D) Esporotricose cutânea fixa no pé e eritema multiforme no dorso do tronco e membros superiores de uma mesma paciente.

### 1.1.7.1. ESPOROTRICOSE E INFECÇÃO PELO HIV

Em relação à infecção pelo HIV foram Lipstein-Kresch et al. em 1985, que chamaram a atenção para o caráter oportunístico que *Sporothrix* spp. poderia assumir nestes pacientes. Tratava-se de um paciente com lesões cutâneas que evoluiu com artrite de punhos e dedos sendo *Sporothrix* isolado em pele e líquido sinovial. Apesar do tratamento com anfotericina B e melhora do quadro, o paciente evoluiu para óbito por complicação da esporotricose e de outras associações da aids (Lipstein-Kresch et al., 1985). Desde os primeiros casos relatados de esporotricose e infecção pelo HIV, vários relatos de casos vieram no decorrer da epidemia de HIV/aids e até hoje somam 36 casos publicados mundialmente.

A maioria dos casos relatados apresentou a forma disseminada com imunodeficiência já instalada (linfócitos T CD4<sup>+</sup> < 200/μL), tendo sido inclusive descrita como primeira infecção oportunística em pelo menos três destes indivíduos (Al-Tawfiq; Wools, 1998; Neto et al., 1999; Silva-Vergara et al., 2012). A forma cutânea com lesões ulceradas e/ou nódulos disseminados foi a principal manifestação observada (Bibler et al., 1986; Bolao et al., 1994; Al-Tawfiq; Wools, 1998; Neto et al., 1999). Entretanto, a forma localizada, a linfangítica nodular, e lesões atípicas de difícil diagnóstico, como lesões psoriasiformes e úlceras semelhantes a pioderma gangrenoso também foram descritas (Keiser; Whittle, 1991; Al-Tawfiq; Wools, 1998).

O sistema osteoarticular foi o sítio extracutâneo mais frequentemente acometido na esporotricose, sob a forma de monoartrite, poliartrite e tenossinovite, sendo as falanges e os joelhos as articulações mais envolvidas (Matter et al., 1984; Lipstein-Kresch et al., 1985; Shaw et al., 1989; Oscherwitz; Rinaldi, 1992; Edwards et al., 2000). O sistema nervoso central (SNC) foi o segundo sítio extracutâneo mais afetado (Heller; Fuhrer, 1991; Keiser; Whittle, 1991; Penn et al., 1992; Donabedian et al., 1994; Dong et al., 1995).

A meningite por esporotricose é um evento raro, mesmo em pacientes imunossuprimidos. Recentemente, a maioria dos casos publicados de meningite por esporotricose esteve associada à infecção pelo HIV (Gutierrez-Galhardo et al., 2010). O diagnóstico de meningite muitas vezes é difícil pela pobreza de elementos fúngicos ao exame de líquido. Penn et al. (1992) relataram um paciente com aids e esporotricose que somente após cinco meses do aparecimento das lesões cutâneas foi feito o diagnóstico de meningite (com realização de quatro exames líquóricos).

Estes achados são contrastantes quando o espécime biológico é exsudato ou biópsia cutânea, nos quais *Sporothrix* é evidenciado com relativa facilidade.

Esporotricose envolvendo cavidade oral esteve associada a quadro cutâneo disseminado (Aarestrup et al., 2001). Em relação ao acometimento do sistema respiratório, foi descrito sinusite invasiva de três meses de evolução. Neste caso, o paciente costumava manipular um musgo nas suas atividades de jardinagem e a infecção ocorreu por via inalatória e/ou por autoinoculação, facilitada provavelmente pelo uso de corticoide inalatório (Morgan; Reves, 1996).

Um outro aspecto interessante na associação de esporotricose e infecção pelo HIV foi o encontro inédito de hifas de *Sporothrix* em grande quantidade no exame de escarro em um paciente com tosse produtiva, com conversão para a forma de leveduras em meio de cultivo (Gori et al., 1997). Esta morfologia com hifas é observada na natureza, em saprofitismo. Neste caso, aspectos fenotípicos da cepa, como uma maior virulência, associados à imunodeficiência do hospedeiro, podem ter contribuído para os achados.

Além das manifestações descritas, uveíte granulomatosa por esporotricose em um paciente que vinha sendo tratado com anfotericina B intravenosa também foi verificada, e o paciente evoluiu com endoftalmite e enucleação. Provavelmente o uso de corticoide local acelerou o processo (Kurosawa et al., 1988). Outro achado não usual foi o de orquite associada a lesão cutânea e artrite (Ware et al., 1999).

#### **1.1.8. DIAGNÓSTICO**

##### **1.1.8.1. DIAGNÓSTICO MICOLÓGICO**

No diagnóstico laboratorial, os elementos de *Sporothrix* spp. no exame direto são raramente visualizados (Kwon-Chung; Bennett, 1992; Zancopé-Oliveira et al., 2011). Ocasionalmente, podem-se ver formas leveduriformes em navetas ou charutos cercados por um halo claro em esfregaços corados ao Giemsa. O isolamento de *Sporothrix* spp. em cultura a partir de espécimes clínicos como exsudato, escarro ou raspado da lesão é o padrão ouro. A semeadura do fungo em Agar-Sabouraud com antibióticos resulta no aparecimento de colônias em 3 a 5 dias, porém esse período pode se estender a 4 semanas. O exame microscópico da cultura em temperatura ambiente revela a forma miceliana com hifas finas, hialinas, septadas e ramificadas com conídios unicelulares ovais ou piriformes dispostos ao



longo da hifa com aparência de cachos ou buquê. Esses conídios podem se apresentar como demáceos ou hialinos. Como *Sporothrix* spp. apresentam dimorfismo térmico reversível, tornam-se leveduriformes quando cultivadas entre 35 e 37°C. Nesta forma, o fungo se reproduz por brotamento e não forma conídios. A conversão do fungo produtor de conídios demáceos da forma filamentosa para leveduriforme confirma o diagnóstico (Rippon, 1988; Kwon-Chung; Bennett, 1992; Penha; Bezerra, 2000; Lacaz, 2002; Zancopé-Oliveira et al., 2011).

#### **1.1.8.2. DIAGNÓSTICO HISTOPATOLÓGICO**

Os achados histopatológicos em geral são inespecíficos e apresentam semelhanças com outras doenças infecciosas e inflamatórias. Muito comumente são vistos dermatite difusa e infiltrado inflamatório granulomatoso com necrose caseosa ou de liquefação (Quintella et al., 2011, 2012). As estruturas fúngicas são raramente visíveis e são coradas positiva e irregularmente no Gram, melhor coradas por ácido periódico de Schiff (PAS) ou métodos de impregnação pela prata, medem 3-5µm, podem ter formato de levedura ou semelhante a um charuto, único ou múltiplo brotamento. O granuloma mais típico pode exibir três regiões distintas: a central com predomínio de polimorfonucleares e necrose; a intermediária composta por células gigantes e epitelioides e a externa mostra vasos com proliferação endotelial e infiltrado linfocitário, plasmócitos, fibroblastos e alguns eosinófilos (Ramos-e-Silva, 1972). Nas lesões mais crônicas surge uma exuberante reação pseudoepiteliomatosa. Há uma estrutura considerada típica, porém não patognomônica e raramente visível que é o “corpo asteroide”; esta é formada pela estrutura fúngica basofílica cercada por raios eosinofílicos de complexos antígeno-anticorpos, reação denominada fenômeno de Splendore-Hoeppli (pela contribuição dos dois autores na observação e descrição do achado) (Rippon, 1988; Kwon-Chung; Bennett, 1992; Lacaz, 2002).

#### **1.1.8.3. INTRADERMORREAÇÃO**

O teste cutâneo (intradermorreação) com esporotriquina detecta hipersensibilidade tardia (resposta imune celular). Não é utilizado como rotina diagnóstica, uma vez que pode ser positivo em pacientes sem doença ativa e negativo nas formas extracutâneas e disseminadas (Ramos-e-Silva, 1972). A sua principal utilização é em inquéritos epidemiológicos para estudos de prevalência em determinadas áreas geográficas, já que é usualmente positivo em mais de 90% dos

casos comprovados de esporotricose (Itoh et al., 1986; Alchorne et al., 1990). Vale destacar que esta técnica está cada vez mais em desuso.

#### 1.1.8.4. DIAGNÓSTICO SOROLÓGICO

Provas sorológicas são úteis no diagnóstico da esporotricose, embora não sejam utilizadas frequentemente. As mais citadas na literatura são: fixação do complemento, imunofluorescência direta, imunodifusão dupla, soroaglutinação do látex e ELISA. O resultado positivo dessas provas é sugestivo, porém não confirma o diagnóstico de esporotricose. Esses exames são úteis principalmente em casos com acometimento extracutâneo, em que o acesso à coleta de amostra para análise micológica se torna difícil como, por exemplo, no envolvimento do SNC e ossos.

Técnicas sorológicas por ensaio imunoenzimático (ELISA) demonstram alta sensibilidade no diagnóstico de esporotricose, entretanto algumas apresentam reação cruzada com soros de portadores de leishmaniose tegumentar americana. Penha e Bezerra (2000) conseguiram a detecção de anticorpos contra uma peptidomannana capaz de se ligar à concanavalina-A da parede celular de *Sporothrix* spp. por um teste ELISA demonstrando 100% de sensibilidade e baixo grau de reação cruzada com soro de pacientes com leishmaniose cutânea. Almeida-Paes et al. (2007b), ao avaliarem soro de 90 pacientes com esporotricose utilizando a técnica de ELISA com exoantígeno da fase miceliana do fungo, encontraram sensibilidade de 97% e especificidade de 89%. Fernandes G et al. (2011) realizaram um estudo comparando o antígeno purificado e o exoantígeno, cujos resultados demonstraram respectivamente, 90 e 96% de sensibilidade e 96 e 98% de especificidade, corroborando esses dados apresentados por Almeida-Paes. Esse método diagnóstico ainda não está estabelecido como rotina, uma vez que ainda não foi superada a reação cruzada com as diversas infecções fúngicas.

O teste de *immunoblot* foi usado pela primeira vez para o sorodiagnóstico da esporotricose em 1989, quando o exoantígeno da fase leveduriforme de *Sporothrix* spp. apresentou 100% de sensibilidade e 95% de especificidade para a detecção de anticorpos em amostras de soro (Scott; Muchmore, 1989). Almeida-Paes et al. (2012b) descreveram a aplicabilidade do *immunoblot* em uma área endêmica de esporotricose utilizando antígenos de superfície não covalentemente ligados à parede celular de células leveduriformes de *S. brasiliensis* no diagnóstico da esporotricose, que apresentou sensibilidade de 92,9% e especificidade de 80% quando duas ou mais bandas foram reveladas nas tiras contendo o antígeno.

#### 1.1.8.5. DIAGNÓSTICO MOLECULAR

O diagnóstico baseado na amplificação das sequências gênicas de fungos por PCR é uma ferramenta poderosa para a identificação de micoses invasivas. A primeira PCR para a identificação de *Sporothrix* spp. foi descrita por Kano et al. (2001). Iniciadores baseados no gene codificador da *CHS 1* (quitina sintase 1) foram desenhados e a PCR foi capaz de detectar 10 pg de fragmento de DNA genômico de *Sporothrix* spp. Posteriormente essa metodologia foi utilizada para o diagnóstico molecular da esporotricose (Kano et al., 2005). Uma *nested* PCR para detecção de *Sporothrix* spp. foi avaliada em amostras clínicas utilizando como alvo a região do gene *18S rRNA*. Essa reação detectou DNA de *Sporothrix* spp. em amostras de tecidos de animais infectados ou de amostras clínicas de pacientes com esporotricose, confirmados por cultura ou coloração histoquímica. O ensaio mostrou uma alta sensibilidade e especificidade, indicando que poderia permitir o diagnóstico rápido, com precisão suficiente para ser útil no diagnóstico de pacientes com esporotricose (Hu et al., 2003). Liu X et al. (2013) relataram uma PCR em biópsia de tecido utilizando o *primer* para o gene codificador da *CHS*, *S2-R2*, que apresentou reações positivas em 25 de 30 casos (83,3%). Esses *primers* também foram utilizados com sucesso para o diagnóstico da esporotricose felina, sem apresentar reações cruzadas com células da pele de gatos saudáveis ou infectados com outros fungos dimórficos (Kano et al., 2005). Contudo, estes estudos não permitiram a classificação em nível de espécie do complexo *Sporothrix schenckii*, o que foi conseguido posteriormente, como já detalhado na sessão “O Agente” desta tese.

#### 1.1.9. TRATAMENTO

A solução saturada de iodeto de potássio (SSKI), descoberta no século XIX, ainda é um dos fármacos mais prescritos para o tratamento da esporotricose nas formas cutâneas por ser efetiva e de baixo custo. O seu mecanismo de ação é desconhecido. Tem sido sugerido que este sal atue na resolução dos granulomas pelo aumento da proteólise. Outros sugerem que ele promova o aumento da fagocitose (Barros et al., 2011a; Reis et al., 2012). Estudos *in vitro* sugerem que este fármaco promova destruição da parede das leveduras durante a conversão da forma iodeto para iodo (Torres-Mendoza et al., 1997). É um fármaco de difícil utilização, uma vez que se deve aumentar gradualmente a dose (de 5 até 40 gotas) para ser

bem tolerado e ser administrado três vezes ao dia com água ou, preferencialmente, suco ou leite. Efeitos adversos frequentemente relatados são: gosto metálico, náusea, vômitos, anorexia, epigastralgia e diarreia. Esses efeitos podem ser atenuados pela redução da dose ou suspensão temporária do fármaco. Com o uso prolongado, alguns pacientes podem apresentar sintomas de iodismo (acentuado gosto metálico e queimação na boca, sialorreia, sensibilidade nos dentes e gengivas e cefaleia) ou toxicidade pelo potássio (arritmias, fraqueza, confusão mental, parestesia em mãos) (Sterling; Heymann, 2000).

Devido aos efeitos adversos relacionados à SSKI, outras opções foram mais exploradas, como os derivados azólicos. Atualmente, o itraconazol é o fármaco de eleição para o tratamento da esporotricose cutânea (Barros et al., 2004, 2011a, 2011b; Kauffman et al., 2007). Este, por via oral, é bem tolerado, sendo necessários cuidados especiais com interação farmacológica e eventual dano hepático. No tratamento da esporotricose cutânea a dose recomendada varia de 100 a 200 mg por dia. Em um estudo foram relatados cinco pacientes com esporotricose cutânea tratados com pulsoterapia de itraconazol (400 mg/dia por uma semana a cada mês), sendo que quatro destes pacientes evoluíram para cura após uma média de três pulsos e meio (Bonifaz et al., 2008). Barros et al. (2011b), avaliando 645 pacientes, demonstraram sucesso terapêutico com 100 mg/dia de itraconazol.

O itraconazol é um derivado triazólico que interage com enzimas do citocromo P450 inibindo a síntese do ergosterol na membrana celular do fungo, o que prejudica sua permeabilidade. Este fármaco é metabolizado no fígado, principalmente pela isoenzima CYP3A4 do citocromo P450, por isso interage com outros fármacos metabolizados por esta via (Katz, 1999). Estão descritas 202 interações farmacológicas de intensidades decrescentes: 32 delas implicam em contraindicação absoluta ao seu uso, 95 em interação grave, 73 em moderada e 2 em interação leve (Micromedex, 2014).

A terbinafina é outro fármaco que vem sendo utilizado com sucesso na terapia da esporotricose cutânea, quando o itraconazol não pode ser utilizado (Francesconi et al., 2009), pois apresenta menos interações farmacológicas (12 interações descritas). É um derivado alilamina que atua bloqueando a síntese do ergosterol pela inibição da enzima esqualeno epoxidase. O seu metabolismo é hepático e apresenta, também, pequena ligação com as enzimas microssomais do citocromo P450 (em torno de 5% da capacidade total), por isso acredita-se que não altere a disponibilidade de outros fármacos metabolizados por este sistema enzimático. Sua

excreção é renal (80%) e em paciente com insuficiência renal e hepática o *clearance* da terbinafina diminui em 50% (Micromedex, 2014).

Estudos de sensibilidade demonstraram uma boa atividade *in vitro* do itraconazol, da terbinafina e do posaconazol contra *Sporothrix* spp. (Meinerz et al., 2007; Gutierrez-Galhardo et al., 2008; Silveira et al., 2009). Três estudos usando terbinafina em pacientes humanos demonstraram eficácia em doses variando de 250 a 1000 mg/dia (Chapman et al., 2004; Francesconi et al., 2009, 2011). Posaconazol é um fármaco triazólico de segunda geração, com amplo espectro, mas seu uso na esporotricose ainda deve ser avaliado (Scheinfeld, 2007; Silveira et al., 2009). Em um estudo *in vivo* em murinos este fármaco foi capaz de evitar a morte por *S. schenckii* e *S. brasiliensis* nos animais testados, bem como reduzir a carga fúngica tecidual a níveis próximos aos conseguidos com anfotericina B (Fernández-Silva et al., 2012). Recentemente, este fármaco foi utilizado com sucesso em combinação com a anfotericina B no tratamento de esporotricose disseminada, por *S. schenckii*, em um paciente com leucemia de células T cabeludas (Bunce et al., 2012).

Nas formas mais graves os fármacos de escolha são o itraconazol em doses maiores (200 a 400 mg ao dia) ou a anfotericina B. Esta última, um antifúngico poliênico produzido pelo actinomiceto *Streptomyces nodosus*, é efetiva em infusão intravenosa na dose de 0,25 a 1 mg/kg/dia com dose cumulativa de 2 a 4 gramas, conforme a resposta clínica; entretanto apresenta inúmeros efeitos adversos, além de toxicidade renal e cardíaca. As apresentações deste fármaco em dispersão coloidal ou lipossomal apresentam reações adversas semelhantes às da apresentação convencional, mas menos frequentes e de menor intensidade, o que permite a utilização de doses maiores, encurtando o tempo de tratamento (Kauffman et al., 2007).

#### **1.1.9.1. TRATAMENTO ADJUVANTE**

Tratamentos adjuvantes podem ser empregados com êxito em diversas situações. O calor local (42°C a 43°C) com bolsa de água quente, fonte de infravermelho ou método similar, por cerca de 15 a 20 minutos, três vezes ao dia está indicado em lesões nodulares e fistulizadas. Esta forma de tratamento baseia-se na sensibilidade do fungo a altas temperaturas, constituindo importante alternativa terapêutica em gestantes e em pessoas com risco aumentado para o uso dos fármacos (Rippon, 1988; Kwon-Chung; Bennett, 1992; Barros et al., 2001, 2004; Lacaz, 2002; da Rosa et al., 2005; Kauffman et al., 2007).

Soluções contendo iodo são empregadas nas lesões ulceradas, atentando para sensibilidade a este elemento e extensão das lesões. A absorção maciça do iodo traz efeitos deletérios em pacientes com insuficiência renal. Na esporotricose é habitual a persistência de lesões infiltradas e residuais a despeito da cicatrização das demais. A curetagem e/ou eletrocoagulação destas lesões muitas vezes possibilita a suspensão do antifúngico (Valle; Gutierrez-Galhardo, 2012). Outro método com excelentes resultados é a crioterapia. Nosso grupo tem sido pioneiro no seu uso, e empregamos muitas vezes no início do tratamento nas lesões verrucosas ou úlcero-vegetantes únicas (Ferreira et al., 2011). Uma outra situação que empregamos é nas lesões cutâneas múltiplas associadas à aids. Acreditamos que este método, ao destruir parcialmente a lesão possibilita uma melhor disponibilização do fármaco. São realizadas sessões a cada 15 a 30 dias, de 2 ciclos com um tempo de congelamento de 15 a 20 segundos. A aspiração de nódulos flutuantes confere alívio e favorece a cicatrização (Valle; Gutierrez-Galhardo, 2012). Recentemente, a terapia fotodinâmica adjuvante ao itraconazol foi empregada com sucesso no tratamento de uma forma localizada verrucosa de esporotricose previamente tratada sem sucesso com itraconazol e terbinafina (Gilaberte et al., 2014).

#### **1.1.9.2. TRATAMENTO DE GESTANTES**

As gestantes, se possível, não devem receber tratamento farmacológico até o término da gestação. Nas formas linfocutânea e cutânea fixa pode-se fazer aplicação diária de calor local, e aguardar o final da amamentação para tratamento farmacológico, caso persistam as lesões, pois os fármacos indicados passam para o leite materno e podem causar prejuízos ao lactente. Em caso de disseminação da doença ou de difícil controle, a anfotericina B deve ser empregada (Valle; Gutierrez-Galhardo, 2012).

### **1.1.10. MEDIDAS DE CONTROLE**

Medidas de controle e profilaxia podem ser adotadas, tais como: uso de luvas e roupas de mangas longas no manuseio de plantas ou outros materiais que possam facilitar a exposição ao fungo; uso de calçados em trabalhos rurais (Barros et al., 2011a); encaminhamento de indivíduos com lesões suspeitas de esporotricose para um serviço de referência em dermatologia.

No caso da esporotricose zoonótica, deve ser realizado o tratamento dos animais doentes e, se possível, o isolamento destes até a cicatrização das lesões; uso de luvas de látex durante o manuseio destes animais; castração dos gatos, para diminuir as visitas à rua; cremação dos animais mortos com esporotricose, para evitar que o fungo se perpetue na natureza; descontaminação das instalações com hipoclorito de sódio; conscientização da população contra o abandono dos animais doentes e das carcaças dos animais mortos com a doença; esclarecimento aos proprietários de animais com o diagnóstico de esporotricose sobre a doença, os modos de transmissão e a profilaxia (Schubach; Schubach, 2000; Schubach et al., 2001, 2005; Barros et al., 2011a).

A notificação dos casos pode contribuir para que ações sejam prontamente executadas com o intuito de controlar surtos nas diferentes regiões.

## 1.2. RACIONAL E JUSTIFICATIVA

A esporotricose sob forma de zoonose é rara. Entretanto, desde 1998, ocorre a maior epidemia zoonótica de esporotricose já registrada no mundo transmitida pelo gato, com discussão atual sobre já se tratar de uma hiperendemia, no município do Rio de Janeiro e arredores. Por ter a notificação compulsória no estado do Rio de Janeiro determinada somente em julho de 2013 (Resolução SES Nº 674 DE 12/07/2013), ainda não há registro da atual magnitude da epidemia.

Desde o início do aumento do número de casos, o IPEC se estruturou como centro de referência de atendimento clínico, laboratorial e terapêutico gratuito no estado, com a maior casuística do Rio de Janeiro. A esporotricose representa mais de 85% do atendimento do Laboratório de Dermatologia em Doenças Infecciosas. De 1998 a março de 2013 foram registrados no serviço de estatística e documentação do IPEC mais de 4.100 casos de esporotricose. Nos anos anteriores (1986-1997), somente 13 casos de esporotricose foram diagnosticados e com perfil epidemiológico diferente do atual (Schubach et al., 2005).

Em 2009, avaliamos 804 pacientes com esporotricose atendidos entre 2005 e 2008 e foi constatado um crescimento médio anual de 85% dos casos, comparado aos anos anteriores (1998-2004). Houve predomínio de mulheres entre a 4ª e 6ª décadas de vida, atividade no peridomicílio e residentes em áreas carentes da região metropolitana do Rio de Janeiro. Contato direto com gatos foi referido por 91% dos pacientes e 68% destes referiram trauma por estes animais. A forma clínica mais comum foi a linfocutânea (66%), seguida da forma fixa (25%), cutânea disseminada (7%) e da forma extracutânea/disseminada (2%). Destacamos a ocorrência de 14 casos de pacientes coinfectados pelo HIV. O tratamento foi feito com itraconazol em 64% dos casos e com terbinafina em 23%. Cerca de 2% dos pacientes apresentaram recidiva clínica, enquanto 11% obtiveram cura espontânea. Os pacientes tiveram seguimento clínico entre três e seis meses após o fim do tratamento. Houve perda de seguimento de 9% dos pacientes, seis pacientes foram hospitalizados e dois foram a óbito. No total, 89% dos pacientes obtiveram cura (Freitas, 2009; Freitas et al., 2010).

Alguns aspectos clínicos foram destaque, como: recidiva de lesões principalmente localizadas nas mãos após trauma local e lesões com necessidade terapêutica superior a um ano, sendo que o tempo médio de tratamento da esporotricose no grupo total observado foi em torno de 12 semanas (Freitas, 2009).



Surgiram, assim, algumas questões sobre a possível maior virulência das cepas causadoras da infecção nos pacientes com lesões de difícil resolução terapêutica, bem como se estes pacientes tinham uma mesma cepa persistente, ou reinfeção por outra cepa. Nossa equipe tem se voltado para a caracterização fenotípica e genotípica de *Sporothrix* spp. isoladas nesta epidemia. Gutierrez-Galhardo et al. (2008), ao estudar padrões fenotípicos e genotípicos dos isolados de *Sporothrix* spp. associados a diferentes formas clínicas da esporotricose, observaram um padrão muito semelhante entre os isolados, sugerindo um nicho comum, corroborando dados de Marimon et al. (2007). Reis et al. (2009), ao caracterizar fungos isolados de pacientes e gatos pela técnica de PCR-RAPD, observaram alto grau de similaridade genética, embora tenha sido possível discriminar entre 5 a 10 perfis genotípicos, sugerindo-se mais de uma população de *Sporothrix*. Estudo posterior confirmou esta variação e demonstrou que, de 247 isolados obtidos de pacientes oriundos desta epidemia, 230 amostras (93,1%) foram caracterizadas como *S. brasiliensis*, 16 (6,5%) como *S. schenckii* e 1 (0,4%) como *S. globosa* (Oliveira et al., 2011). Duas particularidades desta epidemia, o predomínio da espécie *S. brasiliensis* e as peculiaridades clínicas, como formas de hipersensibilidade e grande percentual de quadros disseminados de esporotricose, propiciaram a hipótese de uma associação causal entre espécie envolvida e apresentações clínicas.

Outros subgrupos de pacientes tiveram especial destaque, seja pelas formas clínicas menos comuns, seja pela gravidade que assumiram: pacientes coinfectados por HIV e *Sporothrix* spp. constituíram quase metade das internações pela esporotricose; pacientes com formas oculares da esporotricose (coroidite, dacriocistite), pacientes com síndrome de *Sweet* como forma de hipersensibilidade à esporotricose, e a particularidade no tratamento de gestantes com esporotricose.

O estudo de fatores epidemiológicos, micológicos, clínicos e terapêuticos associados à esporotricose é importante para melhor compreensão da doença. Há uma inquestionável contribuição no âmbito da saúde pública, uma vez que se sabe que a epidemia/hiperendemia não foi controlada, num cenário em que temos 71% dos gatos envolvidos na cadeia de transmissão com destino inadequado, perpetuando o ciclo da esporotricose zoonótica no Rio de Janeiro, além do impacto do alto custo das internações e do tratamento mais prolongado dos pacientes.

## **2. OBJETIVOS**

### **2.1. OBJETIVO GERAL**

Avaliar fatores epidemiológicos, micológicos, clínicos e terapêuticos associados às diversas formas clínicas de pacientes com esporotricose.

### **2.2. OBJETIVOS ESPECÍFICOS**

1. Descrever aspectos clínicos ainda não relatados dos casos envolvidos na hiperendemia de esporotricose.
2. Descrever a evolução de um grupo de gestantes com esporotricose.
3. Descrever aspectos epidemiológicos, clínicos e terapêuticos dos casos de coinfeção pelo HIV envolvidos na hiperendemia de esporotricose.
4. Avaliar a frequência das hospitalizações e dos óbitos dos pacientes com esporotricose.
5. Analisar procedência, fatores clínicos e evolutivos de um grupo de pacientes infectados com diferentes genótipos do complexo *Sporothrix schenckii*.
6. Determinar o genótipo e a virulência de diferentes isolados de *Sporothrix* spp. coletados de um paciente com esporotricose disseminada, ao longo de cinco anos de doença.

### **3. CONSIDERAÇÕES ÉTICAS**

O projeto: “Avaliação de fatores epidemiológicos, micológicos, clínicos e terapêuticos associados à esporotricose.” foi aprovado pelo Comitê de Ética em Pesquisa do IPEC em 30/07/10 sob o número 0024.0.009.000-10 (anexo A).

Os dados coletados após revisão dos prontuários foram inseridos no banco de dados tendo como chave de identificação o registro do paciente no IPEC, juntamente das iniciais do nome e dos dados referentes às variáveis de interesse no estudo. Um termo de compromisso e responsabilidade padrão do instituto foi preenchido pela responsável pelo projeto (anexo B).

#### 4. CAPÍTULO 1 – APRESENTAÇÕES CLÍNICAS INÉDITAS E TERAPÊUTICA INCOMUM

Neste capítulo, três trabalhos publicados são apresentados.

O grande e constante aumento no número de casos de esporotricose de transmissão zoonótica no estado do Rio de Janeiro, notadamente na região metropolitana da capital, propiciou o surgimento de novas apresentações clínicas da doença, bem como de condições associadas a estas apresentações.

Diversos casos de reação de hipersensibilidade associados à esporotricose têm sido percebidos e diagnosticados, como eritema nodoso e eritema multiforme, descrito na literatura por nosso grupo, em anos anteriores, e artrite reativa, também descrito no decorrer desta epidemia, por outro grupo de estudiosos. Aqui, a síndrome de Sweet, uma dermatose neutrofílica febril aguda, já associada a quadros neoplásicos, inflamatórios e infecciosos outros, é descrita em três pacientes diagnosticadas com esporotricose. Esta associação era, até então, inédita.

O acometimento ocular na esporotricose já foi descrito, entretanto, o processo inflamatório das vias lacrimais conhecido como dacriocistite, somente havia sido relatado como manifestação crônica da micose. Neste atual artigo, são descritos quatro pacientes que apresentaram dacriocistite aguda isolada, ou associada a lesões cutâneas da esporotricose. Três deles evoluíram com cronicidade do quadro e uma paciente, com fístula cutânea, todos com indicação cirúrgica reparadora. Destacamos, ainda, o predomínio de crianças neste grupo de pacientes.

Outro grupo de destaque, não pelo ineditismo, mas pela necessidade de um especial manejo terapêutico, foi o constituído pelas gestantes diagnosticadas com esporotricose. Felizmente não houve gestantes com quadros disseminados ou graves e a termoterapia, terapêutica já descrita há muitos anos e embasada na labilidade térmica do fungo causador da esporotricose, foi efetiva na cura na maioria dos casos, ou no controle temporário do quadro clínico, até que o tratamento farmacológico pudesse ser instituído em dois casos.

Estes novos relatos contribuem para um melhor e maior conhecimento acerca das possíveis apresentações clínicas na esporotricose e, de posse destes dados, os profissionais de saúde podem aprimorar o raciocínio clínico-epidemiológico e otimizar o diagnóstico e o tratamento dos pacientes.

**Sweet syndrome associated with sporotrichosis**

DOI: 10.1111/j.1365-2133.2011.10496.x

MADAM, Sweet syndrome (SS) is characterized by fever, acute onset of painful erythematous papules, plaques or nodules, peripheral neutrophil leucocytosis, and histological findings of a dense neutrophilic infiltrate without evidence of primary vasculitis.<sup>1-4</sup> It usually affects middle-aged women and has been associated with infection<sup>2,3</sup> and an underlying disease.

Regarding fungal infections, SS has been described in coccidioidomycosis.<sup>5</sup> Here we report three cases of SS in patients with sporotrichosis. Diagnosis of sporotrichosis was based on isolation in culture of *Sporothrix schenckii* from the initial lesion and diagnosis of SS was based on clinical and histopathological findings.<sup>2,3</sup>

The first patient was a 47-year-old woman with a cutaneous ulcerated lesion on her right thigh followed by fever, osteoarticular pain, and disseminated cutaneous plaque lesions (Fig. 1). She reported the absence of local trauma and had not taken any medication before the diagnosis. She also reported that she took care of a diseased cat. Her white blood cell count reached  $20.3 \times 10^9 \text{ L}^{-1}$  and culture of the ulcerated lesion evidenced *S. schenckii*. She improved after 8 weeks of itraconazole 100 mg daily and 2 weeks of oral prednisone.

The second patient was a 47-year-old woman with an ulcerated lesion on the knee and disseminated cutaneous erythematous plaques. She remembered taking diclofenac-cholestyramine for back pain for 5 days prior to the appearance of the lesions, and denied any contact with cats. Her white blood cell count was  $11.0 \times 10^9 \text{ L}^{-1}$ . Culture of her ulcerated lesion showed *S. schenckii*. She improved after 12 weeks of itraconazole 100 mg daily and 8 weeks of oral prednisone.

The third patient was a 78-year-old woman who had a knee injury 40 days before the onset of diffuse pruriginous cutaneous papules and plaques. She also had fever and headache. She had contact with a diseased cat at home but reported no injuries caused by the animal. She had systemic arterial hypertension that was under control with the use of hydrochlorothiazide and enalapril. Her white blood cell count was  $7.9 \times 10^9 \text{ L}^{-1}$  and *S. schenckii* was isolated from ulcerated knee lesion. The patient improved after 8 weeks of itraconazole 100 mg daily and a 1-week course of oral potassium diclofenac and oral dexchlorpheniramine.

Histopathological findings of one erythematous plaque from each patient were very similar (Fig. 2). There was marked oedema of the papillary dermis mimicking a subepidermal vesiculation. The underlying upper dermis contained an intense perivascular and interstitial infiltrate of neutrophils with leukocytoclasia and macrophages, some with epithelioid differentiation. In patients 1 and 2 there were dilated vessels and extravasated red blood cells while in patients 1 and 3 focal spongiosis with small spongiotic vesicles was seen. A few eosinophils were seen in patient 2.

Sporotrichosis is a subcutaneous infection caused by the dimorphic fungus *S. schenckii*.<sup>6</sup> Hypersensitivity reactions such as erythema nodosum<sup>7</sup> and erythema multiforme<sup>8</sup> have been described in cat-transmitted endemic sporotrichosis in Rio de Janeiro.

The patients presented here were from an endemic area of sporotrichosis and two had contact with cats. They presented localized forms of sporotrichosis and developed clinical and histopathological characteristics of SS. Patient 1 had no other factor that could explain the onset of the SS. The drugs used by patients 2 and 3 are not known to be associated with SS.<sup>9</sup> In all cases, patients were successfully treated for the mycosis and for the SS.

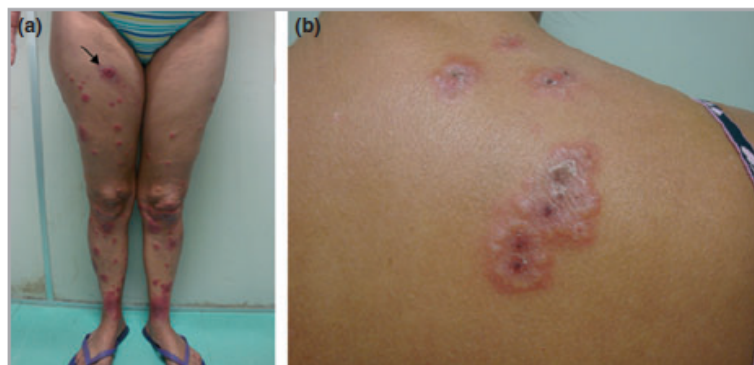
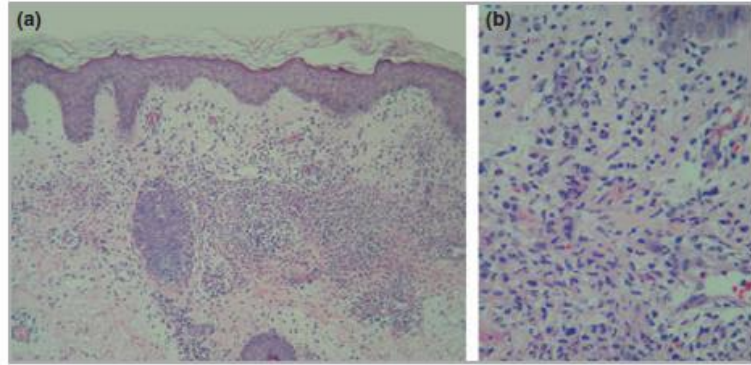


Fig 1. (a) Cutaneous erythematous plaques and papules on the legs of patient 1. An ulcerated lesion is observed on the right thigh (arrow). (b) More erythematous plaques with crusts are seen on the posterior trunk.

**Fig 2.** Histopathology of an erythematous cutaneous plaque from patient 2, compatible with Sweet syndrome. (a) Predominantly superficial and confluent dermal infiltrate associated with marked oedema of the papillary dermis. (b) Close-up view of the neutrophilic infiltrate. Haematoxylin and eosin; original magnification: (a)  $\times 10$ , (b)  $\times 40$ .



We believe that SS is another sporotrichosis-associated hypersensitivity reaction. Factors such as cat transmission (intense and repetitive fungal inoculum), host susceptibility and the pathogen itself (*S. schenckii* was recently found to be a complex of species: one of them, *S. brasiliensis*, is implicated in Rio de Janeiro endemic transmission<sup>10</sup>) might be explanations for this previously undescribed association.

### Acknowledgments

We thank the staff of the Laboratory of Mycology, IPEC/Fiocruz.

Instituto de Pesquisa Clínica Evandro  
Chagas, Fundação Oswaldo Cruz,  
Av. Brasil 4365, Manginhos,  
Rio de Janeiro, RJ 21040-360, Brazil  
E-mail: dayvison.freitas@ipecc.fiocruz.br

D.F.S. FREITAS  
A.C.F. VALLE  
T. CUZZI  
L.G.P. BRANDÃO  
R.M. ZANCOPE-OLIVEIRA  
M.C.G. GALHARDO

### References

- Sweet RD. An acute febrile neutrophilic dermatosis. *Br J Dermatol* 1964; **76**:349–56.
- von den Driesch P. Sweet's syndrome (acute febrile neutrophilic dermatosis). *J Am Acad Dermatol* 1994; **31**:535–56.
- Cohen PR. Sweet's syndrome – a comprehensive review of an acute febrile neutrophilic dermatosis. *Ophthalmol J Rare Dis* 2007; **2**:34.
- Ginarte M, Toribio J. Sweet's syndrome. *Med Clin (Barc)* 2009; **133**:31–5.
- DiCaudo DJ. Coccidioidomycosis: a review and update. *J Am Acad Dermatol* 2006; **55**:929–42.
- Rippon JW. Sporotrichosis. In: *Medical Mycology: The Pathogenic Fungi and the Pathogenic Actinomycetes* (Rippon JW, ed), 3rd edn. Philadelphia: W.B. Saunders, 1988; 325–52.
- Galhardo MCG, Schubach AO, Barros MBL et al. Erythema nodosum associated with sporotrichosis. *Int J Dermatol* 2002; **41**:114–16.
- Gutierrez-Galhardo MC, Barros MBL, Schubach AO et al. Erythema multiforme associated with sporotrichosis. *J Eur Acad Dermatol Venerol* 2005; **19**:507–9.
- Micromedex. Available at: [http://www.thomsonhc.com/micromedex2/librarian/ND\\_T/evidencexpert/ND\\_PR/evidencexpert/CS/A102C8/ND\\_AppProduct/evidencexpert/DUPLICATIONSHIELDSYNC/228D78/ND\\_PG/evidencexpert/ND\\_B/evidencexpert/ND\\_P/evidencexpert/PFAActionId/evidencexpert.DisplayDrugdexDocument?docId=0373&contentSetId=31&title=DICLOFENAC&servicesTitle=](http://www.thomsonhc.com/micromedex2/librarian/ND_T/evidencexpert/ND_PR/evidencexpert/CS/A102C8/ND_AppProduct/evidencexpert/DUPLICATIONSHIELDSYNC/228D78/ND_PG/evidencexpert/ND_B/evidencexpert/ND_P/evidencexpert/PFAActionId/evidencexpert.DisplayDrugdexDocument?docId=0373&contentSetId=31&title=DICLOFENAC&servicesTitle=)

DICLOFENAC&topicId=cautionsSection&subtopicId=adverseReactionsSection#3.3.2 (last accessed 25 July 2011).

10 Marimon R, Gené J, Cano J et al. Molecular phylogeny of *Sporotrich schenckii*. *J Clin Microbiol* 2006; **44**:3251–6.

Funding sources: none.

Conflicts of interest: none declared.

### Mild staphylococcal scalded skin syndrome: an underdiagnosed clinical disorder

DOI: 10.1111/j.1365-2133.2011.10515.x

MADAM, Staphylococcal scalded skin syndrome (SSSS) is classically described as a systemic blistering skin disorder leaving large areas of denuded skin.<sup>1</sup> It arises from the systemic circulation and accumulation in the skin of exfoliative toxins A and/or B (ETA and ETB) from an infection focus, resulting in a proteolytic cleavage of desmoglein 1.<sup>2</sup> We report five cases of SSSS characterized by a desquamation localized in the folds, with or without scarce blisters.

The five patients had a generalized exanthem associated with localized desquamation, mainly of the folds (Fig. 1a–e). In all cases an impetigo of the face was observed from 2 to 10 days before the onset of the rash. The children had mild fatigue and hyperthermia, but none had hypotension or signs of shock. Complete blood count and C-reactive protein were normal in all cases. The outcome was rapidly favourable for all five children. The same *Staphylococcus aureus* strain (ST121) producing ETA was isolated from the impetigo of the face. The five patients were treated with intravenous oxacillin (100 mg kg<sup>-1</sup> daily), one patient had double antibiotic therapy with gentamicin. Patients were without skin symptoms after 5–10 days. The clinical and microbiological data are shown in Table 1.

These patients show that SSSS is likely to be a clinical spectrum ranging from classical severe SSSS to a mild form. In our five cases the diagnosis of SSSS was based on the following criteria: the transient generalized exanthem associated with localized desquamation, mainly of the folds, the isolation of *S. aureus* harbouring the exfoliative toxin genes and absence of super-

## Acute dacryocystitis: another clinical manifestation of sporotrichosis

Dayvison Francis Saraiva Freitas<sup>1</sup>\*, Iluska Augusta Rocha Lima<sup>2</sup>, Carolina Lemos Curi<sup>3</sup>,  
Livia Jordão<sup>3</sup>, Rosely Maria Zancopé-Oliveira<sup>4</sup>, Antonio Carlos Francesconi do Valle<sup>1</sup>,  
Maria Clara Gutierrez Galhardo<sup>1</sup>, Andre Luiz Land Curi<sup>2</sup>

<sup>1</sup>Laboratório de Doenças Infecciosas em Dermatologia <sup>2</sup>Laboratório de Doenças Infecciosas em Oftalmologia

<sup>3</sup>Laboratório de Micologia, Instituto de Pesquisa Clínica Evandro Chagas-Fiocruz, Rio de Janeiro, RJ, Brasil

<sup>4</sup>Departamento de Oftalmologia, Hospital da Polícia Militar de Niterói, Niterói, RJ, Brasil

*Sporotrichosis associated with exposure to domestic cats is hyperendemic in Rio de Janeiro, Brazil. A review of the clinical records at our institute revealed four patients with clinical signs of dacryocystitis and a positive conjunctival culture for Sporothrix who were diagnosed with Sporothrix dacryocystitis. Three patients were children ( $\leq 13$  years of age) and one patient was an adult. Two patients reported contact with a cat that had sporotrichosis. Dacryocystitis was associated with nodular, ulcerated lesions on the face of one patient and with granulomatous conjunctivitis in two patients; however, this condition manifested as an isolated disease in another patient. All of the patients were cured of the fungal infections, but three patients had chronic dacryocystitis and one patient developed a cutaneous fistula. Sporotrichosis is usually a benign disease, but may cause severe complications when the eye and the adnexa are affected. Physicians, especially ophthalmologists in endemic areas, should be aware of the ophthalmological manifestations and complications of sporotrichosis.*

Key words: dacryocystitis - sporotrichosis - *Sporothrix* - cutaneous fistula - Rio de Janeiro

*Sporothrix schenckii* is a dimorphic fungus that is responsible for cutaneous disease in endemic areas worldwide. Classically, infection is associated with a traumatic subcutaneous inoculation of contaminated soil, plants or organic matter. The most common clinical form of sporotrichosis is cutaneous, lymphatic disease, which accounts for 75% of cases, followed by localised cutaneous forms (20%) (Barros et al. 2011a). Ocular sporotrichosis has rarely been described in immunocompetent patients or in individuals without prior ocular trauma. Intraocular disease has an important association with disseminated disease (Curi et al. 2003, Iyengar et al. 2010, Kashima et al. 2010).

Acute dacryocystitis presents as inflammation of the lacrimal sac and is typically caused by infection. Dacryocystitis is predominantly found in adult women and in young infants. The most common signs and symptoms include erythema, oedema and a painful area of induration that overlies the nasolacrimal sac just below the anatomical boundary of the medial canthal ligament. In addition, epiphora and discharge may be observed. When pressure is applied to the inflamed tear duct, purulent material may be expressed through the lacrimal punctum (Pinar-Sueiro et al. 2012).

Cases of isolated granulomatous conjunctivitis due to *Sporothrix* infection after exposure to cats with sporotrichosis have been reported in Rio de Janeiro (RJ), Brazil (Barros et al. 2004, Schubach et al. 2005). In this study, we evaluated cases of dacryocystitis secondary to *Sporothrix* infection in this hyperendemic area.

This study was approved by the Ethical Committee of the Evandro Chagas Institute of Clinical Research (IPEC)/Oswaldo Cruz Foundation (Fiocruz), RJ, Brazil (0024.0.009.000-10). The authors reviewed the clinical records of patients who were diagnosed with dacryocystitis secondary to *Sporothrix* infection in the dermatology and ophthalmology laboratories of IPEC/Fiocruz from July 2008-July 2010. Patients underwent dermatological and ophthalmological examinations, including visual acuity (Snellen chart), biomicroscopy and ophthalmoscopy. The patients were initially found to be free of chronic stenosis and epiphora. During this period, 2,146 patients were diagnosed with sporotrichosis and sporotrichosis with dacryocystitis was identified in four patients (Table). Three patients were children ( $\leq 13$  years of age) and one patient was an adult (41 years of age). The patients sought medical attention at a median time period of five weeks (3-8 weeks) after the initial manifestations of sporotrichosis. Patients 1 and 4 had a history of contact with cats that had sporotrichosis. Dacryocystitis was present at the outset in all cases. One child had cutaneous nodules and ulcerated skin lesions that were culture-positive for *Sporothrix* (Supplementary data), whereas the other two children had conjunctivitis, but no skin lesions. The adult patient presented only with dacryocystitis (Supplementary data).

The diagnosis of dacryocystitis was established by the presence of swelling at the medial canthus with erythema, epiphora and mucopurulent discharge from the lacrimal punctum. *Sporothrix* infection was confirmed

doi:

Financial support: FAPERJ (E-26/110.619/2012)

RMZ-O was supported in part by CNPq (350338/2000-0).

\* Corresponding author: dayvison.freitas@ipecc.fiocruz.br

Received 5 June 2013

Accepted 22 July 2013

online | [memorias.ioc.fiocruz.br](http://memorias.ioc.fiocruz.br)

TABLE

Clinical characteristics of the patients with *Sporothrix* dacryocystitis, including whether or not there were additional disease manifestations as well as the patients' treatment regimens and complications of their disease

Case	Sex/age	Site of lesion	Treatment (ITC) and length (weeks)	Follow up
1	F/2	Right dacryocystitis + cutaneous nodule-ulcerated lesions on the face	5 mg/kg (13)	Chronic dacryocystitis
2	M/5	Right dacryocystitis + conjunctivitis	100 mg (4)	Chronic dacryocystitis
3	F/13	Right dacryocystitis + conjunctivitis	100 mg (12)	Chronic dacryocystitis
4	F/41	Left dacryocystitis	Up to 400 mg (96)	Cutaneous fistula

F: female; ITC: itraconazole; M: male.

by the isolation of the fungus in culture using the mucopurulent material that was expressed from the lacrimal punctum, which was obtained by swabbing. Cultures were confirmed as positive for *Sporothrix* using previously described methods (Barros et al. 2004). Treatment included itraconazole (ITC) 100 mg/day or 5 mg/kg in children who weighed less than 20 kg. This regimen has been highly successful at our institution as previously described (Galhardo et al. 2008, Barros et al. 2011a, b). Blood count and blood biochemistry tests were conducted at baseline, 12 weeks and when clinically necessary.

A clinical cure was defined as the resolution of inflammation and a negative follow-up culture. Treatment failure was defined as the persistence or worsening of the initial lesion after 12 weeks of treatment, which occurred in the adult patient who received an escalated dose of ITC to 400 mg/day. The treatment of this patient was significantly prolonged (96 weeks). Case 2 was initially lost to follow-up after four weeks of treatment; however, this patient returned seven months later with chronic dacryocystitis and no mycological findings of sporotrichosis. The other children were treated for 12 and 13 weeks. Follow-up was conducted at a minimum of six months after the end of treatment. Despite mycological cures, the three children had chronic dacryocystitis and the adult patient developed a cutaneous fistula. These patients were referred to surgical treatment.

Dacryocystitis secondary to sporotrichosis represented 0.18% of the sporotrichosis cases that were evaluated at the IPEC from July 2008-July 2010. The patients resided in a hyperendemic region for the zoonotic transmission of sporotrichosis and two of the patients had domiciliary contact with cats that had sporotrichosis; however, no specific history of injury was elucidated. Sporotrichosis lesions in cats are rich in parasites and respiratory symptoms can manifest in cats with nasal disease (Schubach et al. 2004, Barros et al. 2011a). Therefore, transmission from cats to humans may occur via respiratory secretions without disruption of the skin barrier when individuals have close face-to-face contact with animals during play (Barros et al. 2004, 2011a).

Fungi have been reported to be present in 4-7% of dacryocystitis cases. The most commonly isolated genus

is *Candida*, followed by *Aspergillus* and *Mucor*. These cases are generally chronic (Pinar-Sueiro et al. 2012). Sporotrichosis with acute dacryocystitis was observed in the cases in this study. Three of the cases were associated with other clinical manifestations (granulomatous conjunctivitis and lymphocutaneous disease). Granulomatous conjunctivitis has been described in 2.2% of patients with cat associated sporotrichosis in RJ (Barros et al. 2004). Notably, dacryocystitis was identified in one of the 81 cases of sporotrichosis in children presented in a previous analysis of patients in RJ (Barros et al. 2008). Dacryocystitis is an unusual manifestation of sporotrichosis; however, these three cases under the age of 13 in the present study represented 2.2% of the paediatric cases of sporotrichosis at the institution, from July 2008-July 2010. Several studies have found that the face is the most frequently affected site of sporotrichosis in children, which is most likely due to the thinner, more delicate skin in this area of the body (da Rosa et al. 2005). Therefore, children are at an increased risk for this clinical form due to the aerosol mode of transmission from nasally infected cats.

The patients in this study responded to treatment; however, each patient had persistent complications that required surgical correction (chronic dacryocystitis and a fistula). Further studies are needed to determine whether dacryocystitis due to *Sporothrix* infection routinely leads to chronic disease. The pathogenesis of this disease is likely due to *Sporothrix* infection through the conjunctiva into the lacrimal sac rather than a haematogenous route. We identified two additional patients in the sporotrichosis cohort in this study who presented with dacryocystitis, but these patients were excluded because their lacrimal cultures were negative. However, both patients developed complications, including a fistula and chronic dacryocystitis.

Recently, *S. schenckii* was found to be a complex of species, including *Sporothrix brasiliensis*, which has been implicated in the hyperendemic transmission of sporotrichosis in RJ (Marimon et al. 2007). The epidemic is associated with the enhanced virulence of the emerging strains of *S. brasiliensis* (Arrillaga-Moncrieff et al. 2009). A molecular analysis of the strains in these four cases was



not performed; however, based on epidemiology, it is likely that *S. brasiliensis* was the species involved.

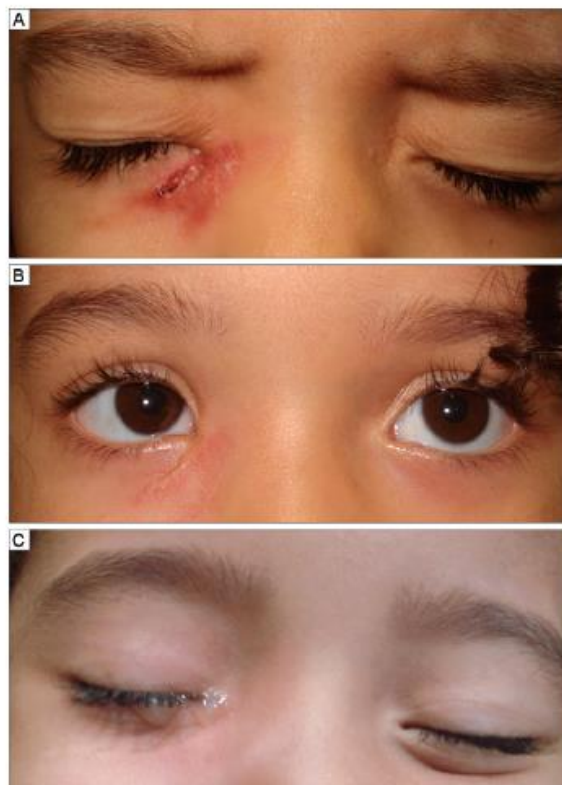
In conclusion, sporotrichosis is frequently a benign disease; however, extracutaneous manifestations, such as diseases that affect the eye and the adnexa, can lead to severe and chronic complications. Clinicians, particularly ophthalmologists and internists in highly endemic areas, should be aware of the protean manifestations of sporotrichosis.

#### ACKNOWLEDGEMENTS

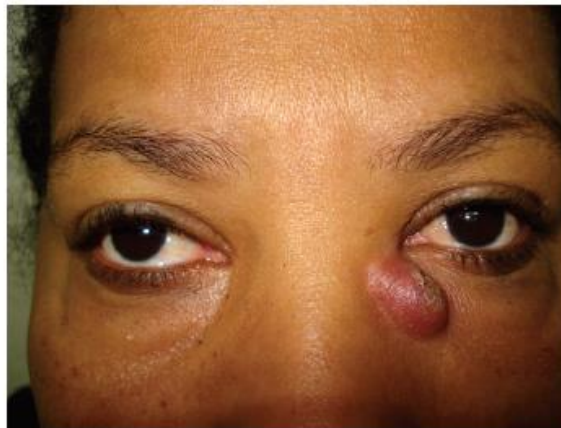To the staff of the Laboratory of Mycology (IPEC/Fiocruz), for their assistance with the fungal cultures and identifications.

#### REFERENCES

- Arrillaga-Moncrieff I, Capilla J, Mayayo E, Marimon R, Mariné M, Gené J, Cano J, Guarro J 2009. Different virulence levels of the species of *Sporothrix* in a murine model. *Clin Microbiol Infect* 15: 651-655.
- Barros MB, Ade OS, do Valle AC, Galhardo MCG, Conceição-Silva F, Schubach TM, Reis RS, Wanke B, Marzochi KB, Conceição MJ 2004. Cat-transmitted sporotrichosis epidemic in Rio de Janeiro, Brazil: description of a series of cases. *Clin Infect Dis* 38: 529-535.
- Barros MB, Costa DLMA, Schubach TMP, do Valle AC, Lorenzi NP, Teixeira JL, Ade OS 2008. Endemic of zoonotic sporotrichosis: profile of cases in children. *Pediatr Infect Dis J* 27: 246-250.
- Barros MB, Paes RA, Schubach AO 2011a. *Sporothrix schenckii* and sporotrichosis. *Clin Microbiol Rev* 24: 633-654.
- Barros MB, Schubach AO, de Oliveira RVC, Martins EB, Teixeira JL, Wanke B 2011b. Treatment of cutaneous sporotrichosis with itraconazole - study of 645 patients. *Clin Infect Dis* 52: e200-e206.
- Curi AL, Felix S, Azevedo KM, Estrela R, Villar EG, Saraça G 2003. Retinal granuloma caused by *Sporothrix schenckii*. *Am J Ophthalmol* 136: 205-207.
- da Rosa AC, Scroferneker ML, Vettorato R, Gervini RL, Vettorato G, Weber A 2005. Epidemiology of sporotrichosis: a study of 304 cases in Brazil. *J Am Acad Dermatol* 52: 451-459.
- Galhardo MC, de Oliveira RM, Valle AC, Paes RA, Silvatavares PM, Monzon A, Mellado E, Rodriguez-Tudela JL, Cuenca-Estrella M 2008. Molecular epidemiology and antifungal susceptibility patterns of *Sporothrix schenckii* isolates from a cat-transmitted epidemic of sporotrichosis in Rio de Janeiro, Brazil. *Med Mycol* 46: 141-151.
- Iyengar SS, Khan IA, Brusco M, Fitzsimmons CJ 2010. Cutaneous *Sporothrix schenckii* of the human eyelid. *Ophthalm Plast Reconstr Surg* 26: 305-306.
- Kashima T, Honma R, Kishi S, Hirato J 2010. Bulbar conjunctival sporotrichosis presenting as a salmon-pink tumor. *Cornea* 29: 573-576.
- Marimon R, Cano J, Gené J, Sutton DA, Kawasaki M, Guarro J 2007. *Sporothrix brasiliensis*, *S. globosa* and *S. mexicana*, three new *Sporothrix* species of clinical interest. *J Clin Microbiol* 45: 3198-3206.
- Pinar-Sueiro S, Sota M, Lerchundi TX, Gibelalde A, Berasategui B, Vilar B, Hernandez JL 2012. Dacryocystitis: systematic approach to diagnosis and therapy. *Curr Infect Dis Rep* 14: 137-146.
- Schubach A, Barros MBL, Schubach TM, Francesconi-do-Valle AC, Gutierrez-Galhardo MC, Sued M, Salgueiro MM, Fialho-Monteiro PC, Reis RS, Marzochi KB, Wanke B, Conceição-Silva F 2005. Primary conjunctival sporotrichosis: two cases from a zoonotic epidemic in Rio de Janeiro, Brazil. *Cornea* 24: 491-493.
- Schubach TM, Schubach A, Okamoto T, Barros MB, Figueiredo FB, Cuzzi T, Fialho-Monteiro PC, Reis RS, Perez MA, Wanke B 2004. Evaluation of an epidemic of sporotrichosis in cats: 347 cases (1998-2001). *J Am Vet Med Assoc* 224: 1623-1629.



A: two year old girl presenting with cutaneous nodule-ulcerated lesion on the inferior right lid; B: healing of cutaneous disease after oral treatment; C: chronic dacryocystitis with sterile pus draining from the lacrimal punctum.



Forty-one year old woman presenting with painful swelling at the medial canthus.

## Pregnancy during a sporotrichosis epidemic in Rio de Janeiro, Brazil

Cassio P. Ferreira\*, Antônio C.F. do Valle, Dayvison F.S. Freitas, Rosani Reis, Maria C.G. Galhardo

Evandro Chagas Clinical Research Institute, Oswaldo Cruz Foundation (IPEC-Fiocruz), Rio de Janeiro, Brazil

### ARTICLE INFO

#### Article history:

Received 11 December 2011

Received in revised form 29 January 2012

Accepted 21 February 2012

#### Keywords:

Brazil

Epidemic

Pregnancy

Sporotrichosis

Thermotherapy

Sporotrichosis is a subacute or chronic disease that affects animals and humans. It is caused by the dimorphic fungus *Sporothrix schenckii* and is the primary subcutaneous mycosis in Latin America [1,2]. Zoonotic transmission of sporotrichosis appears to be rare worldwide. An epidemic of sporotrichosis occurred in Rio de Janeiro, Brazil, from

1998 onward. Cats were found to be the main link in the epidemiological chain [1].

From 2005 through 2010, about 1000 patients were diagnosed with sporotrichosis at IPEC-Fiocruz, including 12 pregnant women. The mean age of the 12 patients was 28.3 years (range, 18–40 years). Two clinical forms of the infection, lymphocutaneous sporotrichosis (10 cases) and fixed sporotrichosis (2 cases), were recorded. Fungal culture was positive in all cases (Fig. 1). The patients underwent monthly outpatient assessments and the time of evolution ranged from 4–12 weeks. The upper limbs were the most commonly affected body area and cat scratch or bites were cited in 11 cases, suggesting that the lesions were the putative means of transmission of the fungus. All patients were instructed to perform thermotherapy with warm compresses 3 times a day. Eight patients were cured with thermotherapy, 2 patients had to use itraconazole after delivery, and 2 patients were lost to follow up.

The causative fungus can be found in decaying vegetation, soil, moss, and wood and can infect a diversity of animals. The usual mode of transmission is traumatic cutaneous inoculation of the

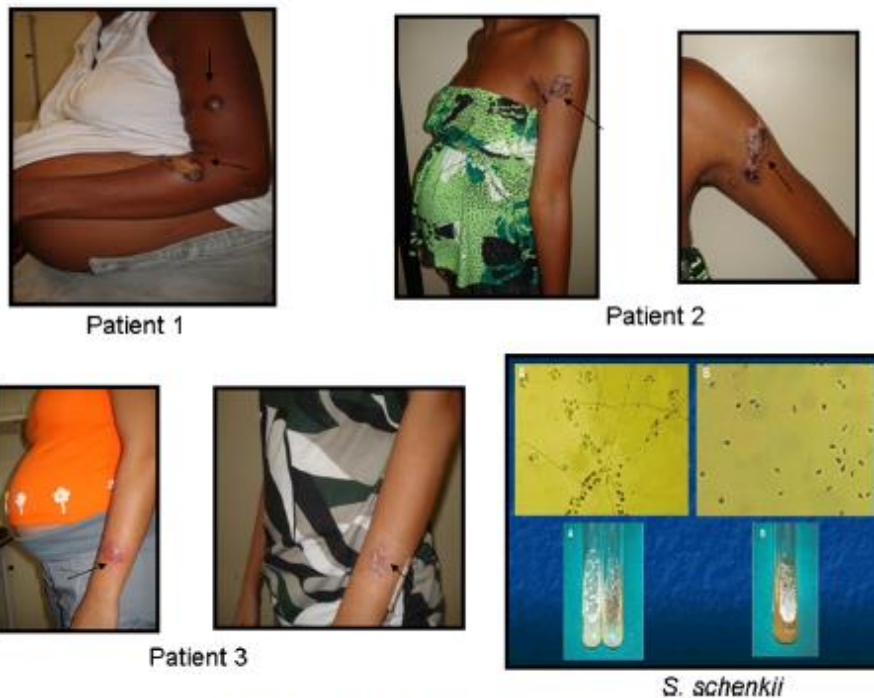


Fig. 1. Cutaneous sporotrichosis in 3 pregnant patients. (A): mycelium form (25 °C); (B) yeast form (37 °C).

\* Corresponding author at: Laboratório de Pesquisa Clínica em Dermatologia Infeciosa, Instituto de Pesquisa Clínica Evandro Chagas - Fiocruz, Av. Brasil 4365, Manguinhos, Rio de Janeiro, Brazil, CEP 21040-900. Tel.: +55 21 3865 8102; fax: +55 21 2209 4110.

E-mail address: drcassioferreira@yahoo.com.br (C.P. Ferreira).

organism [2]. Local hyperthermia can be used to treat cutaneous sporotrichosis in pregnant women [1,3]. Amphotericin B is recommended for severe sporotrichosis that must be treated during pregnancy [1]. Itraconazole is an effective fungal treatment; however, there are few data on prenatal exposure in humans and it is generally

avoided [1]. De Santis et al. [4] reported that first-trimester itraconazole-exposed infants showed no increased risk of congenital abnormalities; however, the rates of spontaneous and induced abortions were higher in the exposed group of pregnant women compared with the control group. Various authors have reported effective treatment of sporotrichosis in pregnant women using thermotherapy [1,3] and even spontaneous resolution during pregnancy [2]. Several infectious diseases, such as malaria, influenza, chickenpox, and measles, may have a markedly severe course [2] and the present cases illustrate the effective treatment of sporotrichosis in pregnancy using thermotherapy or azole therapy after delivery.

#### Conflict of interest

The authors have no conflicts of interest to declare.

#### References

- [1] Costa RO, Bernardes-Engemann AR, Anzay-Abulafia I, Benvenuto F, Neves Mde L, Lopes-Bererra IM. Sporotrichosis in pregnancy: case reports of 5 patients in a zoonotic epidemic in Rio de Janeiro, Brazil. *An Bras Dermatol* 2011;86(5):995-8.
- [2] Almeida Jr HL, Lettin CB, Barbosa JL, Dias MC. Spontaneous resolution of zoonotic sporotrichosis during pregnancy. *Rev Inst Med Trop Sao Paulo* 2009;51(4):237-8.
- [3] Agarwal S, Gopal K, Umesh Kumar B. Sporotrichosis in Uttarakhand (India): a report of nine cases. *Int J Dermatol* 2008;47(4):367-71.
- [4] De Santis M, Di Gianantonio E, Cesari E, Ambrosini G, Straface G, Clementi M. First-trimester itraconazole exposure and pregnancy outcome: a prospective cohort study of women contacting teratology information services in Italy. *Drug Saf* 2009;32(3):239-44.

## 5. CAPÍTULO 2 – ESPOROTRICOSE E HIV

Neste capítulo, é incluído um artigo publicado e outro submetido à publicação.

Em 1999, ainda no início da epidemia zoonótica de esporotricose na região metropolitana do Rio de Janeiro, foi diagnosticado no IPEC o primeiro caso de esporotricose e coinfeção por HIV. Desde então, a ocorrência de novos casos e a percepção de sua maior frequência no decorrer dos anos vem se destacando.

No trabalho publicado em 2012, 21 casos desta coinfeção foram descritos, evidenciando a maior gravidade e disseminação da esporotricose naqueles pacientes com sinais clínicos e laboratoriais de imunossupressão, enquanto os pacientes com melhor status imunológico apresentaram, via de regra, quadros clínicos localizados, à semelhança dos pacientes não infectados por HIV.

Ainda movidos pelo contínuo aumento no número de casos desta coinfeção, reunimos, em uma série histórica do IPEC até março de 2013, 48 casos atendidos, em comparação com os 3,570 pacientes com esporotricose sem coinfeção por HIV. Neste novo trabalho, destacamos novamente a gravidade dos casos com coinfeção e o conseqüente aumento no número de hospitalizações e óbitos destes pacientes. Há uma notória implicação de saúde pública, dado que esta associação tende a se tornar mais frequente, caso estas enfermidades não sejam controladas.

## Sporotrichosis in HIV-infected patients: report of 21 cases of endemic sporotrichosis in Rio de Janeiro, Brazil

DAYVISON FRANCIS SARAIVA FREITAS, BRENDA DE SIQUEIRA HOAGLAND, ANTONIO CARLOS FRANCESCONI DO VALLE, BEATRIZ BARROS FRAGA, MÓNICA BASTOS DE BARROS, ARMANDO DE OLIVEIRA SCHUBACH, RODRIGO DE ALMEIDA-PAES, TULLIA CUZZI, CLÁUDIA MARIA VALETE ROSALINO, ROSELY MARIA ZANCOPÉ-OLIVEIRA & MARIA CLARA GUTIERREZ-GALHARDO

Instituto de Pesquisa Clínica Evandro Chagas, Fundação Oswaldo Cruz, Rio de Janeiro, Brazil

Sporotrichosis is endemic in Rio de Janeiro, Brazil, and cases have been reported to be associated with HIV. This article describes the clinical manifestations and evolution of sporotrichosis in HIV-positive patients and constitutes the largest case series reported to date. There were 21 HIV-positive patients with sporotrichosis diagnosed by the recovery of the etiologic agent from 1999–2009. Sixteen patients (76.2%) were men and five (23.8%) were women, with a mean age of 41.2 years. Seven of these individuals were previously unaware of their HIV infection. Mean CD4 count was 346.4 cells/ $\mu$ l. The most frequent clinical presentations of sporotrichosis in these patients were the lymphocutaneous and disseminated form (seven patients each, 33.3%), followed by the widespread cutaneous form in five (23.8%), and fixed form in the remaining two (9.5%). In patients with the disseminated forms, clinical manifestations involved the skin in six, mucosa (nasal, oral, or conjunctival) in four, bone in two, and meninges in two. Eleven (52.4%) patients received itraconazole and eight (38.1%) amphotericin B contributing to an overall cure rate of 81%. Spontaneous cure was observed in one patient. The clinical forms of sporotrichosis varied according to the patients' immune status. The results demonstrate the importance of sporotrichosis as an opportunistic infection associated with AIDS in countries where the mycosis occurs.

**Keywords** sporotrichosis, HIV infection, clinical forms, immunosuppression, Rio de Janeiro

### Introduction

Sporotrichosis is a subacute or chronic subcutaneous infection caused by the dimorphic fungus *Sporothrix schenckii*, which is relatively common in Latin American countries with temperate and tropical climates. The typical infection is associated with traumatic inoculation of fungal elements from the soil, plants, and organic matter

contaminated with *S. schenckii*. Transmission by animals has been reported and feline sporotrichosis is a particular zoonotic hazard. Most patients with sporotrichosis have a localized disease limited to the skin and subcutaneous tissue. The lymphocutaneous form is the most common and is observed in up to 95% of patients. Dissemination to various organs and systems is observed in rare cases, mainly in immunosuppressed individuals [1,2].

Despite reports of sporotrichosis being associated with the human immunodeficiency virus (HIV) infection, only 34 cases have been described in the literature since the beginning of the HIV epidemic through 2009 [3–34]. There are reports of the widespread cutaneous form involving osteoarticular, central nervous system (CNS), pulmonary, and ocular lesions. Some of these patients died as a

Received 2 February 2011; Received in final revised form 28 April 2011; Accepted 8 June 2011

Correspondence: Dayvison Francis Saraiva Freitas, Instituto de Pesquisa Clínica Evandro Chagas, Fundação Oswaldo Cruz, Rio de Janeiro, Brazil, Postal Code: 21040-360. Tel.: +55 21 3079 5083; E-mail: dayvison.freitas@ipecc.fiocruz.br

© 2012 ISHAM

DOI: 10.3109/13693786.2011.596288

result of the dissemination of the fungus as found on autopsy [4,6,8,10,12–14,16,18,22,26–28,30].

Since it is not a notifiable disease, little information is available regarding the incidence of sporotrichosis in Brazil. However, a hyperendemic level of sporotrichosis transmitted by cats has been observed since 1998 in Greater Metropolitan Rio de Janeiro, Brazil. The increased level of the fungal disease was mainly found in low-income areas with poor health services. This zoonotic transmission is characterized by household contact with cats with sporotrichosis. In addition to the classical clinical presentations (lymphocutaneous and fixed forms), others such as widespread cutaneous sporotrichosis without underlying immunosuppression, mucosal involvement affecting the conjunctiva, and hypersensitivity syndromes have been observed [35,36].

With regard to HIV infection, the incidence of acquired immunodeficiency syndrome (AIDS) has been declining in Brazil since 2002. In addition, Brazil was the first country in Latin America to ensure free universal access to antiretroviral drugs. A total of 506,499 cases of AIDS were diagnosed in the country from 1980–2008, 60% of which in the Southeast region. Rio de Janeiro is the state of Brazil with the second largest number of AIDS cases [37].

In this study, the largest case series published to date, we describe 21 cases of sporotrichosis associated with HIV infection from sporotrichosis-endemic Rio de Janeiro, Brazil. Case reports on four of these patients have already been published due to their particular characteristics, but these patients were maintained in the cohort [33,34].

## Methods

### Study population

A descriptive study was conducted involving HIV-infected patients with sporotrichosis seen from February 1999 to December 2009. Patients were treated by the Dermatology and Infectious Diseases team of Evandro Chagas Clinical Research Institute [Instituto de Pesquisa Clínica Evandro Chagas (IPEC)], an institute for infectious disease research. Since 1998 it has also served as the main referral center for sporotrichosis in Rio de Janeiro due to its laboratory and clinical infrastructure for diagnosis of this mycosis. In addition, the institute supplies medication free of charge for patient treatment. The study was approved by the Research Ethics Committee of IPEC/Fiocruz, and informed consent was obtained from all the patients.

### HIV diagnosis

HIV was diagnosed according to Brazilian Ministry of Health guidelines [37]. CD4 cell count and viral load were determined at the time of HIV diagnosis and were repeated

at four-month intervals, together with periodic clinical evaluation, to monitor the infection. Highly active antiretroviral therapy (HAART) was initiated when the CD4 cell count was 200 cells/ $\mu$ l or less, or when an opportunistic infection was diagnosed.

### Diagnosis of sporotrichosis

Isolation of *S. schenckii* from clinical specimens was used as the study's inclusion criterion, as described by Barros *et al.* [35]. The following biological samples were obtained on the basis of clinical condition, type of lesion, and availability at the time of the study: surface secretions, obtained with a swab from exudative lesions or draining tracts; purulent or seropurulent content, aspirated from non-ulcerated gummy lesions; and biopsy specimens from the borders of active lesions. Biopsy specimens were divided into two portions with one kept in sterile saline for mycological examination. The other was fixed in 10% buffered formalin, embedded in paraffin and stained with hematoxylin-eosin, Wade, periodic acid-Schiff, and Grocott stains for histopathological examination.

When the patient presented with clinical and laboratory signs of HIV-related immunodeficiency (CD4 count  $\leq$ 200 cells/ $\mu$ l), potential fungal dissemination was investigated by attempting to recover the etiologic agent in culture from samples of sputum, blood, urine, and cerebrospinal fluid (CSF). Blood specimens were collected in Myco/F-Lytic BD Bactec bottles (three samples; one collected every 24 h). Sputum, urine, and CSF specimens were recovered in sterile flasks and centrifuged at 1000 *g* for 10 min, and the pellet used for further processing.

All samples underwent routine mycological examination, which involved direct microscopy of wet mount preparations in 4% sodium hydroxide and inoculating samples on Sabouraud dextrose agar and mycobiotic agar (Difco), incubation at 25°C, and observation for four weeks for fungal growth. Suspected isolates were sub-cultured to potato dextrose agar medium (Difco) to be incubated at 25°C for macroscopic and microscopic morphological studies. Dimorphism was demonstrated by conversion to the yeast-like form on brain heart infusion (BHI) agar medium (Difco) at 37°C. Routine laboratory tests of the patients included fasting serum chemistry profile, i.e., glucose, creatinine, urea, aspartate aminotransferase, alanine aminotransferase,  $\gamma$ -glutamyltransferase, alkaline phosphatase, and hematological tests. These studies were repeated monthly for patients with the localized cutaneous form of sporotrichosis and according to the patient's clinical needs in cases of the other clinical presentations of the infection. Rhinolaryngoscopy, funduscopy, chest and facial sinus radiography, and abdominal ultrasonography were performed routinely, with other tests such as joint

radiography being conducted when indicated. Clinical cases of sporotrichosis were classified according to Sampaio *et al.* [38].

#### *Treatment of sporotrichosis*

Oral administration of itraconazole at a dose of 100–200 mg was the first-choice treatment for patients in good clinical condition. The dose was increased if the lesion remained unaltered or worsened after 1–2 months. Duration of treatment was determined by clinical cure (lesion healing defined as epithelization and absence of crusts, infiltrates, or erythema). Patients with the cutaneous forms who had undergone an overall decline in their health and patients with the disseminated form received amphotericin B at a total dose of 1–2.5 g. Clinical cure of extracutaneous sites was defined as the disappearance of preexisting lesions in cases of conjunctival, nasal, or oral mucosa involvement. Other criteria of cure were the disappearance or stabilization of lytic lesions upon bone radiography and tomography and sterilization of CSF accompanied by improvement of cellularity and biochemistry patterns in cases of meningitis. Patients with osteomyelitis and meningitis were treated for a minimum of 9–12 months. Patients with CD4 counts  $\leq 200$  cells/ $\mu\text{l}$  received additional suppressive therapy consisting of 200–400 mg itraconazole/day until the CD4 count reached higher levels. All patients except two (lost to follow-up) were followed for one year after completion of treatment.

#### *Data collection*

All data were collected by review of medical charts and were recorded on a standard case report form. This information included epidemiological, demographic, and clinical data and response to sporotrichosis therapy. Information regarding HIV infection included year of diagnosis, opportunistic infections, initiation of HAART, and other pertinent data.

## **Results**

#### *Patient series*

The sample represents 1.2% of all cases of sporotrichosis seen at IPEC from 1999–2009. Sixteen patients (76.2%) were males and five (23.8%) were females with a mean age of both sexes of 41.2 years (range: 24–59 years). Eleven cases (52.4%) were from the municipality of Rio de Janeiro (the northern and western districts of the city), nine (42.9%) from other municipalities in Greater Metropolitan Rio de Janeiro (Nova Iguaçu, Duque de Caxias, and São João de Meriti), and one (4.8%) from a rural county in the State of Rio de Janeiro (Bom Jesus do Itabapoana).

Fourteen patients (66.7%) were first diagnosed as HIV positive (mean time since diagnosis = 91.8 months; range: 6–192 months) before developing sporotrichosis. Twelve of these 14 (57.1% of the total 21 cases) were receiving HAART. The remaining seven patients (33.3%; cases 2, 9, 11, 13, 16, 18 and 20) were diagnosed as having sporotrichosis, and were also found to be HIV positive for whom HAART was initiated when indicated. Mean CD4 count was 346.4 cells/ $\mu\text{l}$  (range: 22–1100 cells/ $\mu\text{l}$ ). With regard to the presence of other infections, at the time of sporotrichosis diagnosis, five patients (23.8%) had oral candidiasis, two (9.5%) were infected with hepatitis C virus, and one (4.8%) had human T-lymphotropic virus type 1. One patient (case 2) was diagnosed with neurotoxoplasmosis during the course of treatment for sporotrichosis.

Four patients (cases 11–14) with sporotrichosis developed immune reconstitution inflammatory syndrome (IRIS) 2–5 weeks after initiating HAART. All four had been treatment-naïve individuals with CD4 counts of  $< 200$  cells/ $\mu\text{l}$ , high viral load, and who recovered immunologically under HAART therapy, as previously described [33,34].

#### *Professional activity*

One-third of patients (33.3%) performed domestic work or were unemployed or retired. Other occupations or activities included; administrative assistant, baker, bank clerk, beauty salon worker, bricklayer, cook, craftsman, hairdresser, street vendor, musician, and salesman.

#### *Sporotrichosis transmission*

Fourteen patients (66.7%) reported household contact with cats with sporotrichosis and six (28.6%) of these indicated a traumatic injury (scratch or bite) preceding the symptoms. One patient (4.8%) had household contact with an apparently healthy cat, and another reported contact with soil during his work as a bricklayer. Five patients (23.8%) failed to report any condition or risk factor that might explain transmission of the etiologic agent. Mean duration of symptoms before clinical care was 5.75 months (range: 0.5–60 months).

#### *Clinical presentation*

Table 1 shows the clinical presentations of the 21 patients, i.e., seven (33.3%) had the lymphocutaneous form, seven (33.3%) the disseminated form, five (23.8%) the widespread cutaneous form, and two (9.5%) the fixed form.

With regard to cutaneous involvement, all patients except one (case 2) presented cutaneous lesions, manifested mainly as ulcerated nodules in 11 patients (52.4%), ulcers in eight (38.1%), and cystic masses in one (4.8%).



Table 1 Patients: clinical features, CD4 cell count, treatment, and follow-up.

Case	Gender/age	Clinical form	Conditions/complications	CD4 cell count	Culture positive site(s) or specimens	Treatment/duration (months)	Outcome
1	M/42	Lymphocutaneous (left arm)	-	726	Skin exudate	ITC 100 mg/4	Cure
2	M/46	Disseminated (oral and nasal mucosa)	Nasal septum perforation	-	Nasal and oral biopsy	ITC 1/11	Cure
3	M/53	Lymphocutaneous (right arm)	-	307	Skin biopsy	ITC 2/12	Lost
4	F/46	Fixed (arm)	Erythema multiforme	237	Skin biopsy	ITC 100 mg/4	Cure
5	M/59	Disseminated (cutaneous + conjunctival mucosa)	-	488	Skin exudate + conjunctival swab	ITC 200 mg/6	Cure
6	M/24	Lymphocutaneous (abdomen)	-	483	Skin exudate	ITC 200 mg/2	Lost
7	F/29	Fixed (left arm)	Erythema multiforme	524	Skin exudate	ITC 100 mg/2	Cure
8	M/42	Widespread cutaneous (bilateral ear + neck)	Bilateral auricular chondritis	212	Skin biopsy	ITC 400 mg/4	Cure
9	F/45	Widespread cutaneous	-	111	Skin exudate	ITC 100 mg/5	Cure
10	M/38	Lymphocutaneous (right arm)	-	725	Skin exudate	ITC 100 mg/1	Cure
11	M/27	Disseminated (cutaneous and meningoencephalitis)	IRIS	97	Skin, CSF	ITC + AMB 2.5g + ITC/24 <sup>3</sup>	Relapse with Cure
12	F/46	Disseminated (cutaneous, osteoarticular, oral and nasal mucosa)	IRIS	70	Skin nasal biopsy	ITC + AMB 1g + ITC/60 <sup>3</sup>	Cure
13	M/26	Disseminated (cutaneous and meningoencephalitis)	IRIS	178	Skin biopsy + CSF + sputum + urine	ITC + AMB 2.5g + ITC/4 <sup>3</sup>	Death*
14	M/47	Disseminated (cutaneous and osteoarticular)	IRIS	157	Skin exudate	AMB 1g + ITC 400 mg/11	Cure
15	M/44	Disseminated (cutaneous, nasal mucosa)	Nasal septum perforation	22	Skin exudate, nasal swab	AMB 2.5g/5	Cure
16	M/44	Widespread cutaneous	-	110	Skin exudate	AMB 2.3g/7	Cure
17	M/41	Lymphocutaneous (left arm, axial)	-	201	Skin biopsy	AMB 0.4g + ITC + AMB 1.2g/7 <sup>4</sup>	Cure
18	M/39	Widespread cutaneous	Destruction of nares	86	Skin biopsy	AMB 2g/3	Cure
19	M/45	Lymphocutaneous (right arm)	-	747	Skin exudate	-	Cure
20	M/28	Widespread cutaneous	-	-	Skin exudate and biopsy + blood	-	Death**
21	F/55	Lymphocutaneous (right arm)	-	1100	Skin exudate	ITC 100 mg/3	Cure

M, male; F, female; ITC, itraconazole; AMB, amphotericin B (expressed as accumulated dose); IRIS, immune reconstitution inflammatory syndrome.

\*One dose up to 400 mg. <sup>2</sup>Probably poor compliance because doses up to 600 mg were used and plasma itraconazole levels were zero when measured. <sup>3</sup>These patients were started on ITC + HAART and developed IRIS. AMB was then administered until the total dose was reached. <sup>4</sup>AMB was discontinued due to renal failure. Treatment was changed to 100 mg ITC for 2 months with no response and AMB deoxycholate was then administered 3x/week for 2 months. \*Methicillin-resistant *Staphylococcus aureus* meningitis. \*\*Septic shock due to *Sporotrix schenckii*.

Twelve patients (57.1%) had up to 10 lesions, six (28.6%) had 11–20 lesions, one (4.8%) had 51 lesions (case 16), and one (4.8%) had 130 lesions (case 15; Fig. 1). Extensive lesions (>4 cm) were observed in eight patients (38.1%) (Fig. 2). Localized lesions were present on the upper limbs in eight patients (38.1%) and on the abdomen in one (4.8%), whereas the other cases had widespread cutaneous lesions.

Three patients (cases 2, 12, and 15) presented inflammatory nasal lesions, including two with nasal septum destruction (cases 2 and 15) and two with lesions of the oral mucosa (cases 2 and 12). The manifestations observed were rhinorrhea and dysphagia. Granulomatous conjunctivitis of the right eye was seen in case 5 (Fig. 3). Osteomyelitis was diagnosed in two patients (cases 12 and 14) affecting the ankle and knee (Case 12) and the left index finger, along with tenosynovitis in the left forearm (Case 14). Both cases were associated with IRIS [33].

Regarding central nervous system involvement, there were two cases of subacute meningoencephalitis associated with IRIS as previously described [34]. Both patients presented with fever, headache, and vomiting. Case 13 also had lethargy, seizures, and hydrocephalus (observed on a brain computed tomography scan). CSF abnormalities were consistent with aseptic/clear fluid meningitis. The criterion for diagnosis of IRIS was the onset of inflammatory sporotrichosis in case 14 after initiating antiretroviral therapy, accompanied by immune recovery (increase in CD4 cell count and viral load suppression). For the other patients who were already in treatment for sporotrichosis, IRIS was suggested by the worsening of the clinical status, such as the appearance of new lesions (cutaneous, nasal mucosa, and bone in case 12) and the onset of meningoencephalitis (cases 11 and 13) shortly after immunological improvement due to antiretroviral therapy. All four patients were previously antiretroviral-naïve.

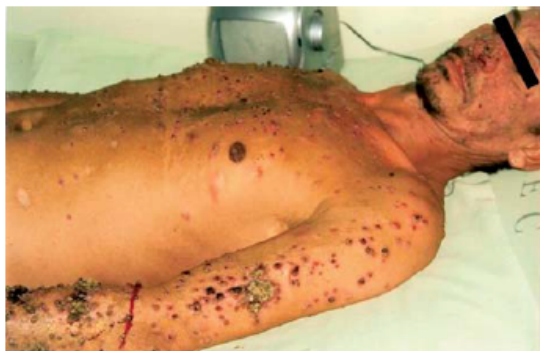

Fig. 1 Case 15 with severe immunosuppression presenting widespread cutaneous lesions. He also had nasal mucosa involvement.

With regard to signs and symptoms associated with sporotrichosis and/or AIDS, 10 patients (47.6%) reported fever and seven (33.3%) weight loss. Two patients (9.5%) presented erythema multiforme attributed to sporotrichosis, which improved with prednisone and itraconazole treatment (cases 4 and 7).

#### Laboratory diagnosis

Diagnosis of sporotrichosis was based on the microscopic observation of *S. schenckii* in the skin of 20 patients (95.2%) and in the nasal and oral mucosa of patient 2. The etiological agent was also isolated from samples of the nasal mucosa collected from three patients (14.3%), CSF of two patients (9.5%), and the conjunctival mucosa, urine, blood, and sputum collected from one of each of four separate patients.

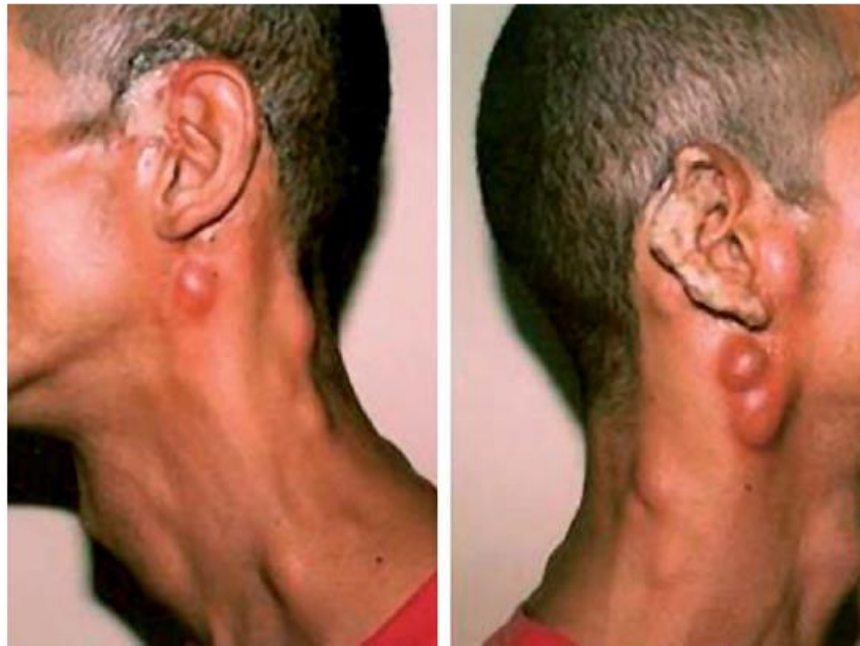A total of 12 specimens from 10 patients were submitted to histopathological examination. One specimen was very superficial, including only the epidermis, and was excluded from the histopathological results (case 21). In seven cases (2, 4, 8, 12, 16, 17, and 20) the inflammatory response was characterized by diffuse granulomatous dermatitis with giant cells, histiocytes, lymphocytes, plasma cells, and neutrophils. Suppurative granulomas were observed in five samples and necrosis in three. In all patients except one (case 4) the infectious agent appeared as numerous round or elongated cigar-shaped elliptical forms which were best visualized under silver staining (Fig. 4).

#### Treatment and outcome

Cure was achieved in 17 patients (81%). Itraconazole was well tolerated. Amphotericin B had to be discontinued in case 17 due to acute renal failure. One patient (case 20) died of sepsis before treatment. Two patients (cases 13 and 18) died during suppressive treatment, without any evidence of sporotrichosis activity (all cultures were negative). Case 13 died of methicillin-resistant *Staphylococcus aureus* meningitis secondary to lumbar puncture for the relief of hydrocephalus. Case 18 refused antiretroviral treatment and died of AIDS-related complications. In case 11, meningitis relapsed after 16 months, but definitive cure was achieved after retreatment with amphotericin B. Clinical follow-up ranged from 1–10 years.

#### Discussion

The large number of sporotrichosis cases associated with HIV infections seen at our institution is probably due to the occurrence of overlapping epidemics in the State of Rio de Janeiro [36], especially among low-income patients. For the period from 2005–2008, there was an



**Fig. 2** Case 8 presenting bilateral auricular lesions with chondritis and partial destruction of the right ear. He also had nodular and cystic lesions with neck lymphadenopathy.

increase of approximately 85% in the number of sporotrichosis cases per year as compared to the annual rate up to 2004. During this same period there was an increase of 126% in cases of sporotrichosis in HIV-infected patients. Thus, all patients except one came from areas with zoonotic sporotrichosis, and most cases (66.7%) presented an epidemiological history of transmission from cats with sporotrichosis. Some patients were working (in various occupations), but a full one-third (33.3%) remained largely at home (housewives, unemployed, retired subjects, students), thus increasing contact with their sick cats. As opposed to the common observation in cases of zoonotic sporotrichosis in Rio de Janeiro involved women aged 31–50 years [35,36], men from the same age bracket comprised the majority of patients in the present case series. This finding reflects the course of the AIDS epidemic in Brazil, where the male/female ratio is still 1.5, despite a decline in the number of new cases [37].

This study revealed a broad clinical spectrum of sporotrichosis, ranging from localized forms with spontaneous cure to disseminated and severe disease leading to death. In general, in HIV-positive patients without clinically defined AIDS (no clinical signs of immunodeficiency), sporotrichosis was manifested as the lymphocutaneous and fixed forms. In contrast, the disseminated and widespread cutaneous forms were observed in patients with AIDS

(CD4 count  $\leq 200$  cells/ $\mu$ l), sometimes with multisystem involvement, with single or associated lesions of the mucosa, CNS and bones. Case 5 was an exception, as he presented the disseminated form despite a CD4 count of 488 cells/ $\mu$ l, with multiple cutaneous lesions and conjunctival mucosa involvement. In addition, two patients (cases 4 and 7) showed an association between sporotrichosis and erythema multiforme as the result of a probable hypersensitivity reaction to *S. schenckii*. This has been previously described in zoonotic sporotrichosis in Rio de Janeiro, with favorable clinical outcome [35]. This clinical association can also be attributed to multiple inoculations during the transmission of sporotrichosis, since patients reported several scratches and bites by their cats.

Seven patients were unaware of their HIV infections prior to the diagnosis of sporotrichosis, with its opportunistic clinical presentation, suggesting the presence of underlying immunosuppression as previously reported by other investigators [5–7,11,19,20,24,29].

The skin was the most commonly affected site (95.2%) and was probably the portal of entry of the etiologic agent. Typical lesions were observed, except for case 13, who presented large cystic masses. Whereas, patients with clinically defined AIDS had larger and more numerous lesions. Al-Tawfiq and Wools [19] reported the presence of psoriasiform cutaneous lesions in patients with AIDS.

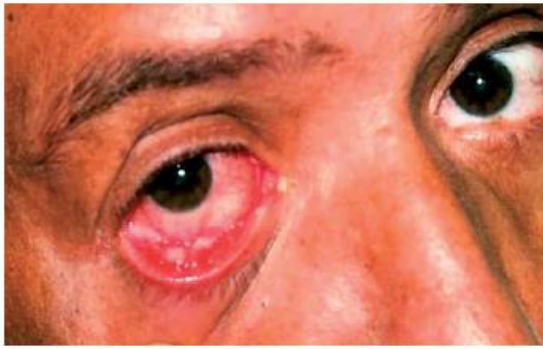

Fig. 3 Case 5 presenting right granulomatous conjunctivitis.

The nasal mucosa (14.3% of cases) was the most common extracutaneous site in the series. In sporotrichosis with or without HIV infection, involvement of the nasal or oral mucosa is attributed to dissemination of the fungus from cutaneous lesions and is rare as an isolated manifestation (seen only in case 2) [13,25]. This patient was a bricklayer and reported no contact with cats with sporotrichosis. Primary sinusitis was observed by Morgan and Reves [17] in AIDS patients. The authors suggested that inhalation or digital inoculation was the likely mode of entry of the fungus, as was observed in the present patient. Septum perforation and 'tapir nose', as observed in leishmaniasis, paracoccidioidomycosis, tuberculosis, and syphilis, had not been described as affecting the nasal cavity in sporotrichosis. This complication was probably a result of the HIV-related immunosuppression of the patient. However, the hypothesis that the *S. schenckii* strain involved in this case produced some virulence factors that may have

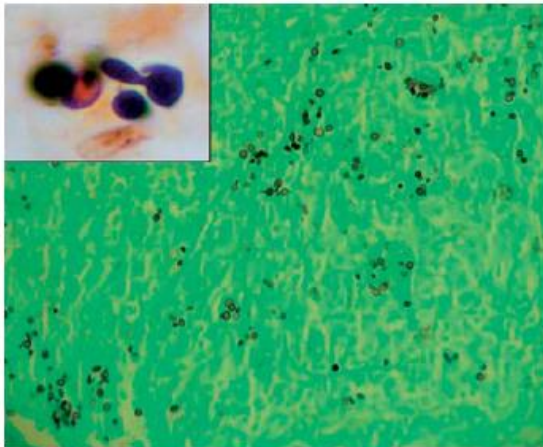


Fig. 4 Gomori's methenamine silver stain of cutaneous biopsy from case 20 showing numerous round shaped structures of *Sporothrix schenckii* (40 $\times$  and 100 $\times$ -spot).

avored the appearance of these destructive mucous lesions cannot be excluded. Our group is currently conducting further research on this issue. Neurotropism is an important aspect of *S. schenckii* infections in patients with AIDS, and systematic investigation of possible CNS involvement is mandatory. Seven of the 34 cases of sporotrichosis associated with HIV infections reported in the literature presented CNS involvement characterized by meningoencephalitis and hydrocephalus, causing death in some cases [10,12,13,15,16,29,30,32]. In the present series, the CNS was the second most frequently affected extracutaneous site. The number of CNS cases was the same as for osteoarticular sporotrichosis (with bones and joints as the classically affected site), and the death of case 13 was caused indirectly by sporotrichosis. Osteoarticular involvement was not associated with inoculation site and was characterized by phalanx and knee osteomyelitis and tenosynovitis. In contrast to the literature, isolated monoarthritis was not observed [3,4,8,11,23]. Both CNS and osteoarticular involvement were associated with IRIS.

As for the specimens and samples in which *S. schenckii* was detected, infection was diagnosed by isolation from skin exudates in most cases. Although the fungus was isolated from sputum and urine, no related clinical or radiological manifestations were observed. Histopathological analysis performed with specimens from 47.6% of the patients showed the formation of granulomas in the majority, despite the patients' immunodeficiency. Although detection of *S. schenckii* in histological sections is difficult, other authors have identified the fungus in patients with AIDS as observed in the present study, probably because of HIV-induced immunosuppression leading to high fungal burden. Importantly, transmission by direct contact with a cat with sporotrichosis might have contributed to this result [35].

In terms of clinical evolution and treatment response, most patients (81%) were cured regardless of clinical form and immune status. Many patients only received 100 mg itraconazole for treatment of both the localized and widespread cutaneous forms of the disease, with an excellent response. According to a previous study, the strains involved in the zoonotic sporotrichosis in Rio de Janeiro show high *in vitro* sensitivity to itraconazole [39]. Case 11 had a relapse in the CNS, a site characterized by poor permeability to antifungal agents. Spontaneous cure, as observed in case 19, has been reported to range from 11–18% among cases in this endemic area [35,36].

In conclusion, the good clinical results in this series were due to the appropriate management of the mycosis, including investigation of fungal dissemination in immunosuppressed patients and antifungal and antiretroviral therapy. The one patient who died (case 20) in whom the two infections were diagnosed simultaneously resembled

many cases from the pre-HAART era. HAART, although triggering IRIS in four patients, certainly improved the patients' prognosis. The results demonstrate the relevance of sporotrichosis as an opportunistic infection associated with AIDS in countries where the mycosis occurs.

### Acknowledgements

Maria Clara Gutierrez Galhardo received partial funding from the Brazilian National STD/AIDS Program, Ministry of Health, grant no. 46/CV079/2006.

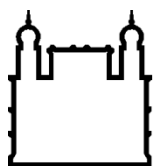
**Declaration of interest:** The authors report no conflicts of interest. The authors alone are responsible for the content and writing of the paper.

### References

- Rippon JW. Sporotrichosis. In: *Medical Mycology: The Pathogenic Fungi and Pathogenic Actinomycetes*. 3rd ed. Philadelphia: WB Saunders, 1988: 325–352.
- Kwon-Chung KJ, Bennett JE. Sporotrichosis. In: Cann C (ed). *Medical Mycology*. 2nd ed. Philadelphia: Lea & Febiger, 1992: 707–729.
- Matter SE, Bailey DM, Sexton DJ. Immune deficiency presenting as disseminated sporotrichosis. *J Okla State Med Assoc* 1984; **77**: 114–117.
- Lipstein-Kresch E, Isenberg HD, Singer C, Cooke O, Greenwald RA. Disseminated *Sporothrix schenckii* infection with arthritis in a patient with acquired immunodeficiency syndrome. *Rheumatol* 1985; **12**: 805–808.
- Bibler MR, Luber HJ, Glueck HI, Estes SA. Disseminated sporotrichosis in a patient with HIV infection after treatment for acquired factor VIII inhibitor. *JAMA* 1986; **256**: 3125–3126.
- Kurosawa A, Pollock SC, Collins MP, Kraff CR, Tso MOM. *Sporothrix schenckii* endophthalmitis in a patient with human immunodeficiency virus infection. *Arch Ophthalmol* 1988; **106**: 376–380.
- Fitzpatrick JE, Eubanks S. Acquired immunodeficiency syndrome presenting as disseminated cutaneous sporotrichosis. *Int J Dermatol* 1988; **27**: 406–407.
- Shaw JC, Levinson W, Montanaro A. Sporotrichosis in the acquired immunodeficiency syndrome. *J Am Acad Dermatol* 1989; **21**: 1145–1147.
- Keiser P, Whittle D. Sporotrichosis in human immunodeficiency virus-infected patients: report of a case. *Rev Infect Dis* 1991; **13**: 1027–1028.
- Heller HM, Fuhrer J. Disseminated sporotrichosis in patients with AIDS: case report and review of the literature. *AIDS* 1991; **5**: 1243–1246.
- Oscherwitz SL, Rinaldi MG. Disseminated sporotrichosis in a patient infected with human immunodeficiency virus. *Clin Infect Dis* 1992; **15**: 568–569.
- Penn CC, Goldstein E, Bartholomew WR. *Sporothrix schenckii* meningitis in a patient with AIDS. *Clin Infect Dis* 1992; **15**: 741–743.
- Donabedian H, O'Donnell E, Olszewski C, MacArthur RD, Budd N. Disseminated cutaneous and meningeal sporotrichosis in an AIDS patient. *Diagn Microbiol Infect Dis* 1994; **18**: 111–115.
- Bolao F, Podzameczer D, Ventin M, Gudiol F. Efficacy of acute phase and maintenance therapy with itraconazole in an AIDS patient with sporotrichosis. *Eur J Clin Microbiol Infect Dis* 1994; **13**: 609–612.
- Dong JA, Chren MM, Elewski BE. Bonsai tree: risk factor for disseminated sporotrichosis. *J Am Acad Dermatol* 1995; **33**: 839–840.
- Rotz LD, Slater LN, Wack MF, et al. Disseminated sporotrichosis with meningitis in a patient with AIDS. *Infect Dis Clin Pract* 1996; **5**: 556–558.
- Morgan M, Reves R. Invasive sinusitis due to *Sporothrix schenckii* in a patient with AIDS. *Clin Infect Dis* 1996; **23**: 1319–1320.
- Gori S, Lupetti A, Moscato G, Parenti M, Lofaro A. Pulmonary sporotrichosis with hyphae in a human immunodeficiency virus-infected patient. A case report. *Acta Cytol* 1997; **41**: 519–521.
- Al-Tawfiq JA, Wools KK. Disseminated sporotrichosis and *Sporothrix schenckii* fungemia as the initial presentation of human immunodeficiency virus infection. *Clin Infect Dis* 1998; **26**: 1403–1406.
- Neto RJP, Machado AA, Castro G, Quaglio ASS, Martinez R. Esporotricose cutânea disseminada como manifestação inicial da síndrome da imunodeficiência adquirida – relato de caso. *Rev Soc Bras Med Trop* 1999; **32**: 57–61.
- Ware AJ, Cockerell CJ, Skiest DJ, Kussman HM. Disseminated sporotrichosis with extensive cutaneous involvement in a patient with AIDS. *J Am Acad Dermatol* 1999; **40**: 350–355.
- Goldani LZ, Aquino VR, Dargel AA. Disseminated cutaneous sporotrichosis in an AIDS patient receiving maintenance therapy with fluconazole for previous cryptococcal meningitis. *Clin Infect Dis* 1999; **28**: 1337–1338.
- Edwards C, Reuther WL 3rd, Greer DL. Disseminated osteoarticular sporotrichosis: treatment in a patient with acquired immunodeficiency syndrome. *South Med J* 2000; **93**: 803–806.
- Bonifaz A, Peniche A, Mercadillo P, Saúl A. Successful treatment of AIDS-related disseminated cutaneous sporotrichosis with itraconazole. *AIDS Patient Care and STDs* 2001; **15**: 603–606.
- Aarestrup FM, Guerra RO, Vieira BJ, Cunha RMC. Oral manifestation of sporotrichosis in AIDS patients. *Oral Dis* 2001; **7**: 134–136.
- Rocha MM, Dassin T, Lira R, et al. Sporotrichosis in patients with AIDS: report of a case and review. *Ver Iberoam Micol* 2001; **18**: 133–136.
- Carvalho MTM, Castro AP, Baby C, et al. Disseminated cutaneous sporotrichosis in a patient with AIDS: report of a case. *Rev Soc Bras Med Trop* 2002; **35**: 1–5.
- Losman JA, Cavanaugh K. Cases from the Osler Medical Service at Johns Hopkins University. Diagnosis: *P. carinii* pneumonia and primary pulmonary sporotrichosis. *Am J Med* 2004; **117**: 353–356.
- Hardman S, Stephenson I, Jenkins DR, Wiselka MJ, Johnson EM. Disseminated *Sporothrix schenckii* in a patient with AIDS. *J Infect* 2005; **51**: e73–e77.
- Silva-Vergara ML, Maneira FRZ, Oliveira RM, et al. Multifocal sporotrichosis with meningeal involvement in a patient with AIDS. *Med Mycol* 2005; **43**: 187–190.
- Fontes PC, Kitakawa D, Carvalho YR, et al. Sporotrichosis in an HIV-positive man with oral lesions: case report. *Acta Cytol* 2007; **51**: 648–650.
- Vilela R, Souza GF, Fernandes G, Mendoza L. Cutaneous and meningeal sporotrichosis in a HIV patient. *Rev Iberoam Micol* 2007; **24**: 161–163.
- Gutierrez-Galhardo MC, do Valle AC, Fraga BLB, et al. Disseminated sporotrichosis as a manifestation of immune reconstitution inflammatory syndrome. *Mycoses* 2010; **53**: 78–80.

- 34 Gutierrez-Galhardo MC, Silva MT, Lima MA, et al. *Sporothrix schenckii* meningitis in AIDS during immune reconstitution syndrome. *J Neurol Neurosurg Psychiatry* 2010; **81**: 696–699.
- 35 Barros MB, Schubach AO, do Valle AC, et al. Cat-transmitted sporotrichosis epidemic in Rio de Janeiro, Brazil: description of a series of cases. *Clin Infect Dis* 2004; **38**: 529–535.
- 36 Freitas DFS, do Valle ACF, Almeida-Paes R, Bastos FI, Galhardo MCG. Zoonotic sporotrichosis in Rio de Janeiro, Brazil: a protracted epidemic yet to be curbed. *Clin Infect Dis* 2010; **50**: 453.
- 37 Ministério da Saúde [homepage on the Internet]. Boletim Epidemiológico DST/Aids [accessed 2010 May 19]. Available from: <http://www.aids.gov.br>.
- 38 Sampaio SAP, Lacaz CS, Almeida F. Aspectos clínicos da esporotricose em São Paulo. *Rev Hosp Clin Fac Med São Paulo* 1954; **9**: 391–402.
- 39 Galhardo MC, De Oliveira RM, Valle AC, et al. Molecular epidemiology and antifungal susceptibility patterns of *Sporothrix schenckii* isolates from a cat-transmitted epidemic of sporotrichosis in Rio de Janeiro, Brazil. *Med Mycol* 2008; **46**: 141–151.

This paper was first published online on Early Online on 22 August 2011.



Ministério da Saúde

**FIOCRUZ**  
**Fundação Oswaldo Cruz**

Brazil, February 9<sup>th</sup>, 2014.

Editor, *PLOS Neglected Tropical Diseases*,

Please find attached the presubmission for the manuscript **“Sporotrichosis: An Emerging Neglected Opportunistic Infection in HIV-infected Patients in Rio de Janeiro, Brazil”** which we would like to submit to the *PLOS Neglected Tropical Diseases Journal*.

With the occurrence of the Zoonotic Sporotrichosis Epidemics in Rio de Janeiro, Brazil, since 1998, our group has accumulated a vast experience in accompanying patients with this mycosis and has published articles on its features, regarding its particularities of less common outcomes and complications, as well.

Sporotrichosis is not equally distributed worldwide, but mainly in tropical and temperate regions of the Globe. In Rio metropolitan area we face hyperendemic levels of sporotrichosis and this endangers underserved populations, among whom sporotrichosis has been propagated with different transmissible (e.g. HIV) and non-transmissible diseases. In 2012, we published a case series of 21 patients with sporotrichosis co-infected with HIV, followed up in our institute until 2009, but this number is still increasing. Up to March 2013, this reference center for infectious diseases, which is responsible for ~70% of sporotrichosis cases in Rio de Janeiro state has accumulated 3,618 adult patients with this mycosis, of whom 48 were co-infected with HIV. In this particular subgroup, sporotrichosis has assumed severe presentations and has elicited the suspicion for AIDS. Nineteen patients (40%) from this group were still unaware of the HIV infection, and sporotrichosis behaved similar to classic opportunistic diseases, with severe disseminated clinical presentations, a strong need for hospitalizations and deaths.

The control of both infections, HIV and sporotrichosis, seems possible since both are preventable conditions. Nevertheless, this is far beyond our reality, in a scenario where the access to public health is not easy to many at-risk populations, and behavior changes both from the population in general, and from the authorities are mandatory.

As the *PLOS Neglected Tropical Diseases Journal* reaches a large number of physicians worldwide, we find important the publication of our results in this prestigious journal as a way of calling the attention for this superposition. Sporotrichosis is not in the main scope of the Journal, but it has really been shown an increase in the number of cases, notably in some developing countries, including India, China and Brazil.

All the authors have seen and approved the content and have contributed significantly to this work.

Yours sincerely,

**Dayvison Francis Saraiva Freitas, MD**

PhD Student in Tropical Medicine  
Instituto Oswaldo Cruz / Fiocruz  
Rio de Janeiro, RJ, Brazil  
# +55 21 99674 5084  
[dayvison.freitas@ipecc.fiocruz.br](mailto:dayvison.freitas@ipecc.fiocruz.br)



Assunto **Your presubmission inquiry**  
De PLOS Neglected Tropical Diseases <plosntds@plos.org>  
Remetente <m.pntd.0.391145.803d4346@editorialmanager.com>  
Para Dayvison FS Freitas <dayvison.freitas@ipecc.fiocruz.br>  
Data 10-02-2014 17:23



---

Dear Dr. Freitas

Thank you very much for your presubmission inquiry to PLoS Neglected Tropical Diseases.

We are interested in your work, "Sporotrichosis: An Emerging Neglected Opportunistic Infection in HIV-infected Patients in Rio de Janeiro, Brazil," and its relevance to neglected tropical diseases. The Editorial Board would like to invite you to submit your manuscript for full consideration at:

<http://www.editorialmanager.com/pntd>

This decision reflects the Board's interest in the study you have described. However, please understand that the editorial decision to send a paper out for peer-review can only be made after we have the opportunity to evaluate the full-length manuscript.

When you do submit, please include mention of this presubmission inquiry and the manuscript number (PNTD-D-14-00229) in the "Previous Interactions" section of the submission form.

We look forward to receiving your paper.

Sincerely,

Peter Hotez  
Editor-in-Chief

1 **Sporotrichosis: An Emerging Neglected Opportunistic Infection in HIV-infected**  
2 **Patients in Rio de Janeiro, Brazil**

3

4 **Sporotrichosis & HIV: A Key Neglected Challenge**

5

6 Dayvison Francis Saraiva Freitas<sup>1</sup>, Antonio Carlos Francesconi do Valle<sup>1</sup>, Margarete  
7 Bernardo Tavares da Silva<sup>1</sup>, Dayse Pereira Campos<sup>1</sup>, Marcelo Rosandiski Lyra<sup>1</sup>,  
8 Rogerio Valls de Souza<sup>1</sup>, Valdiléa Gonçalves Veloso<sup>1</sup>, Rosely Maria Zancopé-  
9 Oliveira<sup>1</sup>, Francisco Inácio Bastos<sup>2</sup>, Maria Clara Gutierrez Galhardo<sup>1</sup>

10

11 <sup>1</sup>Instituto de Pesquisa Clínica Evandro Chagas, <sup>2</sup>Instituto de Comunicação e  
12 Informação Científica e Tecnológica em Saúde, Fundação Oswaldo Cruz, Rio de  
13 Janeiro, Brazil

14

15 **Correspondence:** Dayvison F. S. Freitas, PhD Student in Tropical Medicine  
16 Instituto Oswaldo Cruz – IOC / Fiocruz - Av. Brasil, 4365 - Manguinhos  
17 21040-360 - Rio de Janeiro – Brazil - [dayvison.freitas@ipecc.fiocruz.br](mailto:dayvison.freitas@ipecc.fiocruz.br) / Phone:+55  
18 21 996745084

19

20

21 **Abstract**

22

23 Sporotrichosis associated with zoonotic transmission remains a relevant public  
24 health problem in Rio de Janeiro, Brazil, affecting a large at-risk population, which  
25 includes HIV-infected individuals. We assessed patients co-infected by *Sporothrix*  
26 spp. and HIV over time in the context of an unabated sporotrichosis epidemic.

27 A comprehensive search of a National reference institute for infectious  
28 diseases' database retrieved information regarding 48 patients with sporotrichosis-  
29 HIV co-infection (group 1), as well as 3,570 patients with sporotrichosis (group 2),  
30 from 1987 through March 2013. Most patients from group 1 were male (68.8%),  
31 whereas women were predominant in group 2 (69.1%;  $p < 0.0001$ ). Patients from  
32 group 1 were younger than those from group 2 ( $\mu = 38.38 \pm 10.17$  vs.  $46.34 \pm 15.85$ ;  
33  $p < 0.001$ ) and differed from group 2 in terms of their race/ethnic background, with  
34 70.8% non-white patients in group 1 vs. 38.6% from group 2 ( $p < 0.0001$ ). Close to  
35 half (~44%) of the patients from group 1 were hospitalized due to sporotrichosis over  
36 time, whereas hospitalization was very unlikely in group 2, among whom  
37 approximately 1% were hospitalized over time. Dissemination of sporotrichosis was  
38 the main cause of hospitalization in both groups, although it was more common  
39 among hospitalized patients from group 1 (19/21 [90.5%] vs. 16/37 [43.2%];  
40  $p < 0.001$ ). Over the period under analysis, eight patients died due to sporotrichosis  
41 (3/48 vs. 5/3,570). The diagnosis of sporotrichosis elicited HIV testing and  
42 subsequent diagnosis in 19/48 patients, whereas 23/48 patients were simultaneously  
43 diagnosed with the two infections.

44 HIV infection aggravates sporotrichosis, with a higher incidence of severe  
45 disseminated cases and a higher number of hospitalizations and deaths.  
46 Underserved populations, among whom sporotrichosis has been propagated, have  
47 been affected by different transmissible (e.g., HIV) and non-transmissible diseases.  
48 These populations should be targeted by community development programs and  
49 entitled to integrated management and care of their superimposed burdens.

50

51 **Author Summary**

52

53 Sporotrichosis is a subcutaneous, worldwide-distributed mycosis, endemic in  
54 some areas and is caused by dimorphic fungi from the complex *Sporothrix schenckii*.  
55 Its association with zoonotic transmission remains a relevant public health problem in  
56 Rio de Janeiro, Brazil, affecting a large at-risk population, which includes HIV-  
57 infected individuals. A comprehensive search of a National reference institute for  
58 infectious diseases' database retrieved information regarding 48 patients with  
59 sporotrichosis-HIV co-infection (group 1), as well as 3,570 patients with  
60 sporotrichosis (group 2), registered from 1987 through March 2013. Group 1 mainly  
61 comprised young, non-white men, while group 2 was predominantly comprised of  
62 white middle-aged women. HIV infection aggravates sporotrichosis, as seen with  
63 patients from group 1, who presented more severe disseminated sporotrichosis, a  
64 higher need for hospitalization and risk of death due this mycosis. Due to its  
65 aggressive presentation, sporotrichosis elicited HIV testing and subsequent diagnosis  
66 in 19/48 patients. Underserved populations, among whom sporotrichosis has  
67 propagated, have been affected by different transmissible (e.g., HIV) and non-  
68 transmissible diseases. These populations should be targeted by community  
69 development programs and entitled to integrated management and care of their  
70 superimposed burdens.

71

72

73 **Introduction**

74

75 Sporotrichosis is a subcutaneous mycosis with a worldwide distribution that is  
76 endemic in some areas of Latin America. The infection is caused by a dimorphic  
77 fungus previously described as a single species, *Sporothrix schenckii* [1], that is now  
78 understood as a complex of different species of clinical interest [2]. Molecular studies  
79 have identified *Sporothrix globosa*, *Sporothrix mexicana*, *Sporothrix brasiliensis* and  
80 *S. schenckii* as responsible for sporotrichosis in different regions [2-7]. The classical  
81 infection is associated with traumatic subcutaneous inoculation of soil, plants, and  
82 organic matter contaminated with fungus, with rare cases of transmission from  
83 infected animals [1]. Most patients with sporotrichosis have a localized disease  
84 limited to the skin and subcutaneous tissue (lymphocutaneous and cutaneous fixed

85 forms), comprising up to 95% of cases. Dissemination to various organs and systems  
86 occurs in rare cases, mainly in immunosuppressed individuals [8].

87 In Rio de Janeiro state, Brazil, sporotrichosis has become an urban  
88 endemic/epidemic phenomenon, with transmission from infected cats to humans in  
89 ~91% of human cases [9]. These cases came from the greater metropolitan area of  
90 Rio de Janeiro (the capital city of Rio de Janeiro state), forming a sporotrichosis belt.  
91 These areas are low-income, underserved areas, with scarce and inadequate health  
92 services [9-10].

93 The increase in the number of cases of the disease has been continuous for  
94 more than 15 years and remains on the rise, affecting vulnerable groups of humans,  
95 as well as domestic and stray cats [10]. In 2012, Freitas et al. [8] described the  
96 clinical manifestations and evolution of sporotrichosis in human immunodeficiency  
97 virus (HIV)-infected patients in the largest case series reported to date worldwide.

98 In Brazil, the HIV/AIDS epidemic has been stable and concentrated in some  
99 urban areas, mostly affecting men who have sex with men and female sex workers.  
100 The overall epidemic dynamics have switched from a population of higher  
101 socioeconomic status to individuals from low-middle and lower socioeconomic strata  
102 [11]. These dynamics favor a superposition of HIV spread with other infections such  
103 as tuberculosis and leprosy, which have been uniquely prevalent in contexts of  
104 poverty and pronounced socioeconomic and social geographic inequality [12, 13].

105 The present study summarizes data from a large dataset of sporotrichosis  
106 cases, consisting of 3,570 patients registered from 1987 up to March 2013, as well as  
107 48 patients co-infected by HIV and sporotrichosis, who sought care at a reference  
108 infectious disease unit located in Rio de Janeiro, Brazil.

109

110

## 111 **Methods**

112

113 **Study site.** Instituto de Pesquisa Clínica Evandro Chagas (IPEC) is a National  
114 reference center for infectious diseases. Since the beginning of the sporotrichosis  
115 epidemic in Rio de Janeiro in 1998, this center has been the main referral center for  
116 the treatment of this mycosis in the state due to its certified laboratory and the  
117 optimal infrastructure of its clinical and ancillary services. All services are delivered  
118 free of charge, and referral is agile. Patients may be referred to IPEC from any health  
119 service (public or private) or may spontaneously seek care. In addition, the AIDS

120 program at IPEC began in 1986 and is currently one of the largest providers of  
121 primary, specialty, and tertiary care for HIV-infected individuals and AIDS patients in  
122 Rio de Janeiro State.

123 **Study design.** A systematic search of IPEC's clinical database was  
124 conducted to identify cases of sporotrichosis-HIV co-infection that were registered  
125 from 1987 through March 2013, as well as sporotrichosis cases, overall. All patients  
126 diagnosed with sporotrichosis confirmed by laboratory tests were included, as well as  
127 patients living with HIV under follow-up in the institute's cohort. Patients with  
128 sporotrichosis co-infected with HIV (hereafter denominated "group 1") and patients  
129 with sporotrichosis ("group 2") constituted the groups under analysis. Additional  
130 analyses were conducted on patients from the IPEC HIV/AIDS cohort who were  
131 diagnosed with the following opportunistic mycoses: histoplasmosis, cryptococcosis  
132 and paracoccidioidomycosis. Only patients aged 18 years old or more at the time of  
133 registration were included in the study.

134 **HIV diagnosis.** The diagnosis of HIV infection followed Brazilian Ministry of  
135 Health regulations, which are summarized as follows: an immune-enzymatic method  
136 (ELISA) test plus immune-fluorescence or western blot. HIV serology was conducted  
137 in all cases of disseminated cutaneous and disseminated cases of sporotrichosis or  
138 evidence of HIV signs or symptoms. A non-paired random HIV test was performed  
139 with the stored blood samples of 850 patients from group 2 who were registered from  
140 2000 through 2008.

141 **Sporotrichosis diagnosis.** Isolation of *Sporothrix* spp. from clinical  
142 specimens was used as the study's key inclusion criterion, as previously described  
143 by Barros et al. [14]. When the patient had clinical or laboratory signs of HIV-related  
144 immunodeficiency ( $CD4^+$  count  $< 200$  cells/ $\mu$ L), fungal dissemination was  
145 investigated by culturing his/her sputum, blood, urine, and cerebrospinal fluid (CSF)  
146 samples, as well as by endoscopic and imaging studies, as previously described by  
147 Freitas et al. [8]. Clinical cases of sporotrichosis were classified as localized  
148 (lymphocutaneous and fixed forms), cutaneous disseminated and disseminated  
149 forms. This last form may involve extracutaneous tissues such as the skeletal  
150 system, lungs, testis, nervous system, and mucous membranes [15].

151 **Data collection.** Demographic data included the following categories: gender,  
152 age, ethnicity/color, city of residence and education. Ethnicity/color was established  
153 as white or non-white (brown [mulatto] and black were grouped together here) by the  
154 administrative staff at the time of registration in the institute until the year 2005, after

155 which this information was then self-reported by the patients. The clinical  
156 characteristics of sporotrichosis, as well as the associated morbidity and mortality,  
157 were summarized by the variables as follows: “date of diagnosis of HIV infection” for  
158 patients from group 1; “date of diagnosis of sporotrichosis”; “hospitalization due to  
159 sporotrichosis” (yes/no); main cause for hospitalization among those hospitalized as  
160 a consequence of sporotrichosis (dissemination, secondary bacterial infection,  
161 hypersensitivity reaction [erythema multiforme or erythema nodosum], and local  
162 worsening); comorbidities (cardiovascular disease [ICD-10:I51.6], diabetes [ICD-  
163 10:E10-E14], chronic obstructive pulmonary disease (COPD) [ICD-10:J44], and  
164 alcoholism [ICD-10:F10]); number and length of hospitalizations due to  
165 sporotrichosis; as well as deaths secondary to sporotrichosis.

166 Additional analyses took into consideration the year of occurrence of  
167 opportunistic mycoses (histoplasmosis, cryptococcosis and paracoccidioidomycosis)  
168 in patients from the IPEC HIV/AIDS cohort.

169 Sociodemographic, clinical and laboratory data were entered into contingency  
170 tables and cross-compared using parametric and non-parametric tests (e.g., chi-  
171 square or Fisher’s exact tests for categorical variables, and t-tests or the Wilcoxon-  
172 Mann-Whitney test for means for continuous variables). A p-value lower than 0.05  
173 was defined as statistically significant for the sake of our analyses. Analyses were  
174 carried out with the help of SPSS (17.0), R (version 2.15.3) and Microsoft Office  
175 Excel 2013.

176 The Research Ethics Committee of IPEC/Fundação Oswaldo Cruz (Fiocruz),  
177 RJ, Brazil, approved this study under the protocol number 0001.0.009.000-06.

178  
179

## 180 **Results**

181

182 From 1987 through March 2013, 3,618 patients were diagnosed with  
183 sporotrichosis at IPEC and 48 of them were co-infected with HIV (Figure 1). The main  
184 sociodemographic aspects of the patients with sporotrichosis are summarized in  
185 Table 1.

186 When cross-comparing patients from groups 1 and 2, some interesting  
187 differences were evident. Individuals from both groups clustered in the same  
188 geographic area, i.e., the outskirts and impoverished neighborhoods of the  
189 metropolitan region of Rio de Janeiro (95.8% and 97.2%, respectively) and had a

190 similar low educational background. Among the patients from group 1, approximately  
191 40% of patients had more than 8 years of schooling and a slightly higher proportion  
192 of patients from group 2 (50.6%) had a similar educational level (this difference was  
193 not statistically significant;  $p>0.2$ ).

194 Most patients from group 1 were male (68.8%), whereas women predominated  
195 in group 2 (69.1%;  $p<0.0001$ ). Patients from group 1 were younger than those from  
196 group 2 (mean age =  $38.38 \pm 10.17$  years vs.  $46.34 \pm 15.85$  years;  $p<0.001$ ) and  
197 differed from those from group 2 in terms of their race/ethnic background, with 70.8%  
198 non-whites in group 1 vs. 38.6% from group 2 ( $p<0.0001$ ).

199 Sporotrichosis has been associated with some major harms and risks. There  
200 were 69 hospitalization events due to sporotrichosis among 58 patients (i.e., some of  
201 them were hospitalized more than once; Table 2). However, the proportion of patients  
202 who required hospitalizations over time markedly differed between groups. Close to  
203 half (~44%) of the patients from group 1 were hospitalized over time, whereas  
204 hospitalization was a very unlikely event among patients from group 2, among whom  
205 approximately 1% were hospitalized over time as a consequence of conditions  
206 directly or indirectly associated with sporotrichosis. In addition to the fact that they  
207 were much more frequent, hospitalizations were longer among patients from group 1  
208 compared to group 2 (37 days vs. 21 days; not statistically significant, as expected  
209 for such small figures). Among patients from group 1, the need for hospitalization due  
210 to sporotrichosis was 42 times higher than among those from group 2. This difference  
211 becomes even more pronounced (greater than 50 times higher) when successive  
212 hospitalizations to perform complex or extensive diagnostic and therapeutic  
213 procedures, such as parenteral antifungal treatment, supportive therapy and its  
214 associated monitoring, are taken into consideration (Table 2).

215 Dissemination of sporotrichosis was the main cause for hospitalization in both  
216 groups, although it was more common among hospitalized patients from group 1  
217 (19/21 [90.5%] vs. 16/37 [43.2%];  $p<0.001$ ). On the other hand, local and/or  
218 hypersensitivity manifestations of sporotrichosis were predominant in hospitalized  
219 patients from group 2 ( $p<0.001$ ). At least one comorbidity was present in 54.1%  
220 (20/37) of the hospitalized patients from group 2, but this was a relatively rare event  
221 (3/21 [14.3%]) among hospitalized patients from group 1 ( $p<0.01$ ) (see Table 2). This  
222 difference was mainly due to cardiovascular diseases ( $p<0.05$ ), whereas the  
223 prevalence of diabetes was relatively similar in both groups. Three hospitalized  
224 patients belonging to group 1 had other opportunistic infections at the time of



225 hospitalization: one patient had pulmonary tuberculosis, another patient had  
226 cryptococcal meningitis and another had cytomegalovirus retinitis.

227         During the period under analysis, eight patients died due to sporotrichosis  
228 (3/48 vs. 5/3,570); thus, death attributed to sporotrichosis occurred 45 times more  
229 frequently in patients from group 1.

230         Sporotrichosis elicited HIV testing and subsequent diagnosis, due to its severe  
231 clinical presentation, in 19 patients who were unaware of their HIV status. Four other  
232 patients were simultaneously diagnosed with the two infections. However, three of  
233 them presented localized disease and HIV-related conditions (chronic seborrheic  
234 dermatitis, herpes zoster, weight loss and dyspnea) and one had sporotrichosis  
235 exclusively, with lymph node involvement a few days after the diagnosis of the HIV  
236 infection. In total, 23 patients were simultaneously diagnosed with the two infections.  
237 Among the remaining 25 patients, 13 were under follow-up in the HIV/AIDS cohort  
238 and 12 were referred by other HIV/AIDS clinical providers.

239         In the non-paired random HIV testing performed among 850 patients from  
240 group 2, 1 sample was positive (0.12%).

241         In an effort to better understand the role of sporotrichosis vis-à-vis other  
242 endemic or classic opportunistic mycoses affecting patients with HIV/AIDS belonging  
243 to the IPEC HIV/AIDS cohort, an additional search of the institution's database was  
244 performed. It included 5,385 patients living with HIV/AIDS and focused on diagnoses  
245 of histoplasmosis, cryptococcosis and paracoccidioidomycosis reported among  
246 patients living with HIV/AIDS since 1987 (Table 3, see also Supporting Information).

247         In recent years, cases of sporotrichosis have been on the rise, whereas  
248 figures for histoplasmosis, cryptococcosis and paracoccidioidomycosis have been  
249 low or declining (Table 3).

250

251

## 252 **Discussion**

253

254         The first case of sporotrichosis and HIV co-infection diagnosed at IPEC was  
255 reported in 1999, roughly coinciding with the emergence of sporotrichosis as a public  
256 health issue in Rio de Janeiro [16]. Since then, the increase in the number of patients  
257 with this co-infection was roughly proportional to the overall increase in the number of  
258 sporotrichosis cases over time, with the exception of 2005. During this year, the  
259 specialized outpatient service's staff was dramatically reduced by a combination of

260 factors. This anomaly certainly biased our time series, the clientele's demands that  
261 year could not be properly addressed. As of early 2006, the service regained its full  
262 working capacity.

263 A greater than proportional increase in patients with sporotrichosis co-infected  
264 with HIV has been documented in recent years. This may be explained by an actual  
265 acceleration of the propagation of sporotrichosis in the last seven years, by a  
266 comprehensive HIV screening by clinicians aware of the possibility of co-infection  
267 and the seriousness of this type of double health burden, or a combination of both  
268 factors. A possible bias to be pointed is the fact that the most severe cases are prone  
269 to be referred to IPEC even more frequently than the regular cases of sporotrichosis.  
270 In the context of the stability of the HIV/AIDS epidemic, it is unlikely that a local  
271 outbreak of HIV has been taking place among people with sporotrichosis. The  
272 modest prevalence of other fungal co-infections and their decline in recent years  
273 speak in favor of a unique pattern followed by sporotrichosis, which may or may not  
274 be associated with HIV/AIDS.

275 According to the norms issued by the Brazilian Ministry of Health,  
276 sporotrichosis does not constitute a condition for which provider-initiated testing and  
277 counseling for HIV is mandatory or strongly recommended (such as for patients  
278 diagnosed with tuberculosis). As the clinical forms of sporotrichosis in HIV-infected  
279 patients varied according to the patients' immune status, we might be missing  
280 asymptomatic seropositive patients from group 2 who would present benign forms of  
281 sporotrichosis (lymphocutaneous and fixed), which correspond to ~90% of the clinical  
282 presentation of sporotrichosis cases among our patients overall [9, 14]. Because of  
283 this possibility, we performed a non-paired random HIV testing in approximately one-  
284 quarter of the blood samples collected from patients from this group. Despite the  
285 limitations intrinsic to this type of strategy (besides the fact that this strategy is the  
286 only one that could be accomplished retrospectively), the low prevalence (0.12%)  
287 speaks in favor of a modest degree of misclassification (i.e., people assigned to  
288 group 2 who actually belong to group 1). Obviously, misclassification constitutes a  
289 bias that may compromise any cross-comparative analysis. In this specific study, one  
290 tends to overestimate harms and risks associated with co-infection because cases  
291 who did not present any evident clinical problem tend to be erroneously included in  
292 group 2.

293 The sociodemographic characteristics of group 1, which is composed of a  
294 majority of young males, differ from group 2, which is mostly composed of middle-

295 aged women engaged in domestic duties as previously described in this epidemic [9,  
296 14]. This finding may reflect the dynamics of the HIV/AIDS epidemic in Brazil. Recent  
297 studies have shown that the number of affected men is still increasing, especially  
298 among young men who have sex with men (MSM). At the end of 2012, the estimated  
299 overall prevalence of HIV in Brazil was 0.4% but reached 10.5% among MSM [11].

300 Most of the patients in group 1 and almost half of the patients from group 2  
301 had eight years or less of education. Neglected diseases are often found in poor,  
302 marginalized sections of the population who have restricted access to formal  
303 education [17]. Furthermore, non-white ethnicity/color was prevalent only in group 1.  
304 This finding could point to a subgroup with worse social and economic conditions,  
305 which historically reflects inequality in access to health services that tends to be  
306 secondary to multiple partially overlapping factors, such as social status, gender,  
307 race/ethnicity, place of residence, etc. [18]. However, a misreporting of this variable  
308 cannot be ruled out because in Brazil, there is a large degree of miscegenation and  
309 the registered ethnicity/color was based on skin color instead of proxies of genetic  
310 ancestry [19].

311 As previously described, HIV clearly modifies the natural history of  
312 sporotrichosis and is associated with a broad spectrum of this mycosis. We support  
313 this conclusion, as we have shown that it causes a much higher incidence of severe  
314 disseminated cases and a greater number of hospitalizations and deaths. This  
315 increase may represent a serious issue to the public health and to the economy of  
316 the region.

317 Moreover, we should keep in mind that sporotrichosis is not always a benign  
318 disease and can lead to hospitalization and death even in patients without  
319 immunosuppression. Since July 2013, sporotrichosis was included among the  
320 conditions for which a formal report to the State Health Secretariat is mandatory. This  
321 change is an auspicious one, which may contribute to much more accurate reports in  
322 the near future.

323 Secondary bacterial infection and hypersensitivity reactions were found to be  
324 relevant causes of hospitalization among patients from group 2. In this group, the  
325 presence of comorbidities was key in terms of more serious conditions and more  
326 frequent hospitalizations. *S. brasiliensis*, the main etiologic agent of this specific  
327 epidemic, seems to be more virulent than other species of the *S. schenckii* complex  
328 [20] and may cause pronounced hypersensitivity reactions.

329 It is remarkable that 47.9% of patients were simultaneously diagnosed with the  
330 two infections due to the presence of opportunistic sporotrichosis or other HIV-related  
331 conditions. It is clear that this subgroup of patients did not have adequate access to  
332 the early diagnosis of HIV infection and have entered into HIV care relatively late,  
333 which seems to have increased their chance of acquiring additional infections and  
334 the risk of dying as a consequence of AIDS in the first year of diagnosis [21].

335 Unlike sporotrichosis, which has been a sustained and protracted threat in  
336 recent years, highly active antiretroviral therapy has been associated with a  
337 stabilization of the number of classical opportunistic mycoses, such as  
338 histoplasmosis and cryptococcosis [22], as documented in our database.

339 Sporotrichosis incidence among HIV-infected patients has been increasing on  
340 a continuous basis, and at the end of the study period, the incidence was roughly  
341 comparable to that of histoplasmosis and cryptococcosis. In contrast,  
342 paracoccidioidomycosis does not seem to be associated with HIV infection.

343 Since the beginning of the sporotrichosis zoonotic epidemic in Rio de Janeiro,  
344 IPEC has been the main regional reference center for this mycosis. The same does  
345 not apply to the management of classical opportunistic mycoses; therefore, the IPEC  
346 figures for sporotrichosis tend to be close to the actual number of cases in the  
347 metropolitan area of Rio de Janeiro, but IPEC figures certainly underestimate  
348 classical opportunistic mycoses that are usually managed by clinicians and infectious  
349 diseases from a large network of primary and secondary HIV/AIDS care locations.

350 In 2012, the clinical profiles of 21 of these 48 patients of group 1 who were  
351 followed up in 1999-2009 were analyzed by our team [8]. A search for international  
352 reports in English at that time accounted for 34 cases historically reported. The  
353 present study updated this information up to March 2013, making this case series the  
354 largest worldwide to the best of our knowledge.

355 The harms and risks associated with the propagation of sporotrichosis in a  
356 disenfranchised population affected by different medical and social conditions are of  
357 concern. Among these multiple, partially superimposed burdens, sporotrichosis and  
358 HIV co-infection is of great concern. Both infections are preventable and should be  
359 targeted by integrated programs. It would be naïve to suppose that these deprived  
360 and underserved communities do not face other major overlapping problems, such as  
361 substance misuse, crime, and a myriad of other problems associated with inadequate  
362 sanitation, waste disposal, access to healthy food, etc. Community development and  
363 structural changes fostered by comprehensive public policies and private-public

364 partnerships remain the only real alternative to permit these communities to regain  
365 full citizenship and acceptable standards of life. The unabated spread of  
366 sporotrichosis in the second largest and most industrialized metropolitan area in  
367 Brazil, for more than a decade, is evidence that we are unfortunately far from  
368 reaching these goals.

369

370

## 371 **Acknowledgments**

372

373 Thanks to the staff of the Laboratory of Mycology, IPEC/Fiocruz.

374 Financial support: FAPERJ/Rio de Janeiro, Brazil (grant proc. E-  
375 26/110.619/2012) and PAPES VI – CNPq/Fiocruz (grant proc. 407693/2012-2).

376 Dayvison Francis Saraiva Freitas received financial support from CNPq and  
377 CAPES.

378 Rosely Maria Zancopé-Oliveira was supported in part by CNPq (350338/2000-  
379 0) and FAPERJ (E-26/103.157/2011).

380 Maria Clara Gutierrez Galhardo received partial funding from the Brazilian  
381 National STD/AIDS Program, Ministry of Health (46/CV079/2006).

382

383 **Declaration of conflicts of interest.** The authors report no conflicts of  
384 interest. The authors alone are responsible for the content and writing of the paper.

385

386

## 387 **References**

388

389 1. Barros MB, de Almeida-Paes R, Schubach AO (2011) *Sporothrix schenckii*  
390 and Sporotrichosis. Clin Microbiol Rev 24(4): 633–654. doi: 10.1128/CMR.00007-11

391

392 2. Marimon R, Cano J, Gené J, Sutton DA, Kawasaki M, et al. (2007) *Sporothrix*  
393 *brasiliensis*, *S. globosa*, and *S. mexicana*, three new *Sporothrix* species of clinical  
394 interest. J Clin Microbiol 45: 3198-3206. doi: 10.1128/JCM.00808-07

395

396 3. Madrid H, Cano J, Gene J, Bonifaz A, Toriello C, et al. (2009) *Sporothrix*  
397 *globosa*, a pathogenic fungus with widespread geographical distribution. Rev  
398 Iberoam Micol 26: 218–222. doi: 10.1016/j.riam.2009.02.005

399

400 4. Oliveira MM, Almeida-Paes R, Muniz MM, Gutierrez-Galhardo MC, Zancopé-  
401 Oliveira RM (2011) Phenotypic and molecular identification of *Sporothrix* isolates  
402 from an epidemic area of sporotrichosis in Brazil. Mycopathologia 172: 257–267. doi:  
403 10.1007/s11046-011-9437-3

404

- 405 5. Rodrigues AM, de Hoog S, de Camargo ZP (2013) Emergence of  
406 pathogenicity in the *Sporothrix schenckii* complex. *Med Mycol* 51: 405–412.  
407 doi:10.3109/13693786.2012.719648  
408
- 409 6. Yu X, Wan Z, Zhang Z, Li F, Li R, et al. (2013) Phenotypic and molecular  
410 identification of *Sporothrix* isolates of clinical origin in Northeast China.  
411 *Mycopathologia* 176: 67–74. doi: 10.1007/s11046-013-9668-6  
412
- 413 7. Rodrigues AM, Teixeira MdM, de Hoog GS, Schubach TMP, Pereira SA, et al.  
414 (2013) Phylogenetic Analysis Reveals a High Prevalence of *Sporothrix brasiliensis* in  
415 Feline Sporotrichosis Outbreaks. *PLoS Negl Trop Dis* 7(6): e2281.  
416 doi:10.1371/journal.pntd.0002281  
417
- 418 8. Freitas DF, Siqueira Hoagland B, Valle AC, Fraga BB, Barros MB, et al. (2012)  
419 Sporotrichosis in HIV-infected patients: report of 21 cases of endemic sporotrichosis  
420 in Rio de Janeiro, Brazil. *Med Mycol* 50: 170-178. doi:  
421 10.3109/13693786.2011.596288  
422
- 423 9. Freitas DFS, Valle ACF, Almeida-Paes R, Bastos FI, Galhardo MCG (2010)  
424 Zoonotic sporotrichosis in Rio de Janeiro, Brazil: a protracted epidemic yet to be  
425 curbed. *Clin Infect Dis* 50: 453. doi: 10.1086/649891  
426
- 427 10. Silva MB, Costa MM, Torres CC, Galhardo MC, Valle AC, et al. (2012) Urban  
428 sporotrichosis: a neglected epidemic in Rio de Janeiro, Brazil [in Portuguese]. *Cad*  
429 *Saude Publica* 28: 1867-1880.  
430
- 431 11. Ministério da Saúde do Brasil, Secretaria de Vigilância em Saúde (2013)  
432 Boletim Epidemiológico Aids e DST [in Portuguese]. Available:  
433 <http://www.aids.gov.br/publicacao/2013/boletim-epidemiologico-aids-e-dst-2013>.  
434 Accessed December 12 2013.  
435
- 436 12. Menezes VM, Nery JAC, Sales AM, Miranda A, Galhardo MCG, et al. (2013)  
437 Epidemiological and clinical patterns of 92 patients co-infected with HIV and  
438 *Mycobacterium leprae* from Rio de Janeiro State, Brazil. *Trans R Soc Trop Med Hyg*  
439 108(2): 63-70. doi: 10.1093/trstmh/trt113  
440
- 441 13. San Pedro A, Oliveira RM (2013) Tuberculose e indicadores  
442 socioeconômicos: revisão sistemática da literatura [in Portuguese]. *Rev Panam*  
443 *Salud Publica* 33(4): 294–301.  
444
- 445 14. Barros MB, Schubach Ade O, do Valle AC, Gutierrez-Galhardo MC,  
446 Conceicao-Silva F, et al. (2004) Cat-transmitted sporotrichosis epidemic in Rio de  
447 Janeiro, Brazil: Description of a series of cases. *Clin Infect Dis* 38: 529–535. doi:  
448 10.1086/381200  
449
- 450 15. Sampaio SAP, Lacaz CS, Almeida F (1954) Aspectos clínicos da  
451 esporotricose em São Paulo [in Portuguese]. *Rev Hosp Clin Fac Med São Paulo*  
452 9(6): 391-402.  
453
- 454 16. Schubach AO, Schubach TM, Barros MB (2005) Epidemic cat-  
455 transmitted sporotrichosis. *N Engl J Med* 353(11): 1185-1186.  
456

- 457 17. Schneider MC, Aguilera XP, Barbosa da Silva Junior J, Ault SK, Najera P, et  
458 al. (2011) Elimination of neglected diseases in Latin America and the Caribbean: a  
459 mapping of selected diseases. PLoS Negl Trop Dis 5(2): e964.  
460 doi:10.1371/journal.pntd.0000964  
461
- 462 18. Travassos C, Laguardia J, Marques PM, Mota JC, Szwarcwald CL (2011)  
463 Comparison between two race/skin color classifications in relation to health-  
464 related outcomes in Brazil. Int J Equity Health 10: 35. doi: 10.1186/1475-9276-10-35  
465
- 466 19. Pena SDJ, Di Pietro G, Fuchshuber-Moraes M, Genro JP, Hutz MH, et al.  
467 (2011) The Genomic Ancestry of Individuals from Different Geographical Regions of  
468 Brazil Is More Uniform Than Expected. PLoS ONE 6(2): e17063. doi:  
469 10.1371/journal.pone.0017063  
470
- 471 20. Arrillaga-Moncrieff I, Capilla J, Mayayo E, Marimon R, Marine´ M, et al. (2009)  
472 Different virulence levels of the species of *Sporothrix* in a murine model. Clin  
473 Microbiol Infect 15: 651–655. doi: 10.1111/j.1469-0691.2009.02824.x  
474
- 475 21. Grangeiro A, Escuder MM, Menezes PR, Alencar R, Ayres de Castilho E  
476 (2011) Late Entry into HIV Care: Estimated Impact on AIDS Mortality Rates in Brazil,  
477 2003–2006. PLoS ONE 6(1): e14585. doi:10.1371/journal.pone.0014585  
478
- 479 22. Ramos-e-Silva M, Lima CM, Schechtman RC, Trope BM, Carneiro S (2012)  
480 Systemic mycoses in immunodepressed patients (AIDS). Clinics in Dermatology 30:  
481 616–627. doi: 10.1016/j.clindermatol.2012.01.008  
482
- 483

484 Table 1. Demographics of the patients diagnosed with sporotrichosis at IPEC from  
 485 1987 through March 2013.

Variable	Category	Group 1	Group 2	p-value
<b>Sample</b>		48	3570	
<b>Gender</b>	Male	33 (68.8%)	1102 (30.9%)	<0.0001
	Female	15 (31.2%)	2468 (69.1%)	
<b>Age</b>	Mean	38.4	46.3	<0.001
<b>Ethnicity/color</b>	White	14 (29.2%)	2148 (60.2%)	<0.0001
	Non-white	34 (70.8%)	1380 (38.7%)	
	Unknown	-	42 (1.1%)	
<b>Place of Residence</b>	Hyperendemic <sup>1</sup>	46 (95.8%)	3469 (97.2%)	>0.60
	Non-hyperendemic	2 (4.2%)	101 (2.8%)	
<b>Education</b>	0-8 years	28 (58.3%)	1712 (48.0%)	>0.20
	> 8 years	19 (39.6%)	1806 (50.6%)	
	Unknown	1 (2.1%)	52 (1.4%)	

486 <sup>1</sup>Hyperendemic: Rio de Janeiro metropolitan region.

487  
 488 Table 2. Hospitalization of patients with sporotrichosis at IPEC from 1999 through  
 489 March 2013.

	Group 1	Group 2	p-value	
<b>Sample</b>	48	3570		
<b>Hospitalized</b>	21 (43.75%)	37 (1.04%)	<0.0001	
<b>No of hospitalizations<sup>1</sup></b>	28	41	<0.0001	
<b>Mean length of hospitalization (days)</b>	37	21	>0.05	
<b>Main cause for hospitalization</b>				
<b>Dissemination</b>	19	16	<0.001	
<b>Other<sup>3</sup></b>	2	21	<0.001	
	<b>Secondary bacterial infection</b>	1		14
	<b>Hypersensitivity reaction</b>	1		5
	<b>Local worsening</b>	-		2
<b>Comorbidity</b>	3	20	<0.01	
<b>Cardiovascular</b>	1	12	<0.05	
<b>Diabetes</b>	2	4		
<b>COPD<sup>2</sup></b>	-	2		
<b>Alcoholism</b>	-	2		

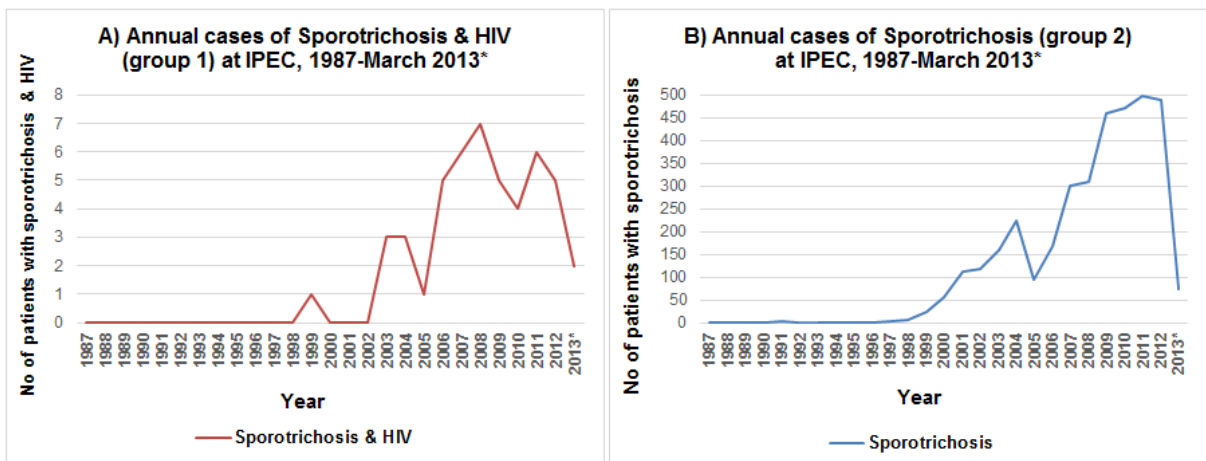
490 <sup>1</sup>Four HIV patients had two hospitalizations and one had four hospitalizations, whereas four non-HIV  
 491 patients had two hospitalizations. <sup>2</sup>COPD: Chronic Obstructive Pulmonary Disease. <sup>3</sup>p-value for the  
 492 other causes of hospitalization grouped (secondary bacterial infection, hypersensitivity reaction, local  
 493 worsening).  
 494

495 Table 3. Annual diagnosis of opportunistic mycoses in patients with HIV at IPEC from  
 496 1987 through March 2013.

Year	Cryptococcosis		Histoplasmosis		Paracoccidioidomycosis		Sporotrichosis	
	No	% Increment	No	% Increment	No	% Increment	No	% Increment
<b>≤ 1992</b>	15	-	10	-	2	-	-	-
<b>1993-1996</b>	16	6,67%	16	60,00%	1	-50,00%	-	-
<b>1997-2000</b>	5	-68,75%	14	-12,50%	1	0,00%	1	-
<b>2001-2004</b>	10	100,00%	15	7,14%	4	300,00%	6	500,00%
<b>2005-2008</b>	9	-10,00%	12	-20,00%	4	0,00%	19	216,67%
<b>2009-2013</b>	18	100,00%	22	83,33%	7	75,00%	20	5,26%
<b>Total</b>	73		89		19		48	

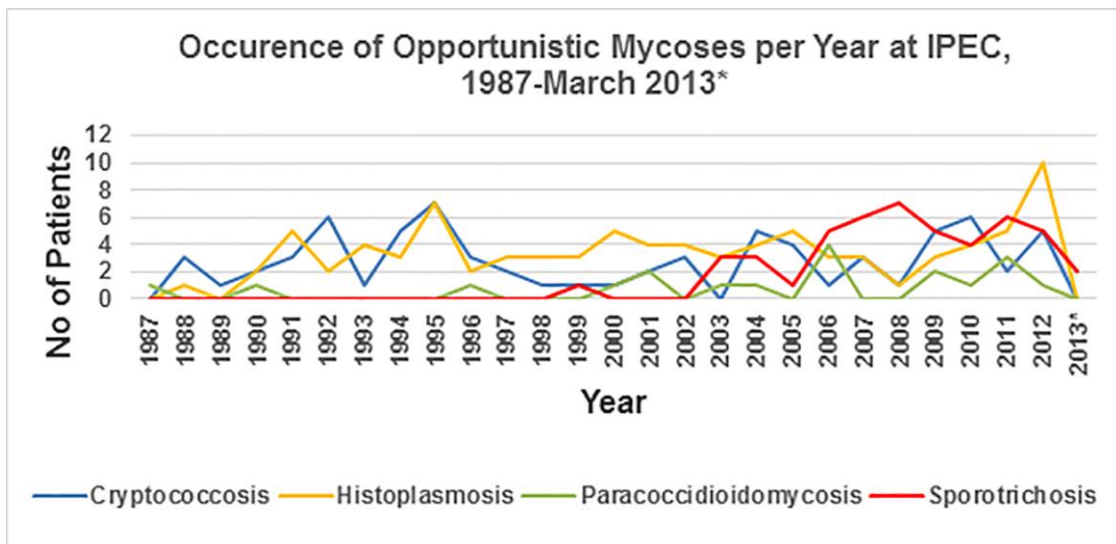
497





498  
499  
500  
501  
502  
503

**Figure 1. Annual number of patients with sporotrichosis at IPEC from 1987 through March 2013. A) Sporotrichosis and HIV (group 1) and B) Sporotrichosis (group 2).**



504  
505  
506

**Supporting Information. Annual occurrence of opportunistic mycoses in HIV-infected patients at IPEC from 1987 through March 2013\*.**

## 6. CAPÍTULO 3 – INFLUÊNCIA GENOTÍPICA E VIRULÊNCIA FÚNGICA NAS APRESENTAÇÕES CLÍNICAS

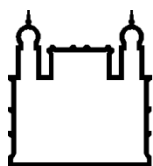
Neste capítulo, um trabalho submetido e outro em fase de elaboração são apresentados.

No início dos anos 2000, ainda no começo da epidemia zoonótica de esporotricose na região metropolitana do Rio de Janeiro, alguns estudos apontavam para um perfil genotípico distinto dos isolados obtidos em seres humanos e em gatos domésticos com esta micose. Em 2007, um grupo de pesquisadores propôs a criação de um complexo *Sporothrix schenckii* que englobaria espécies de interesse clínico, com denominação da espécie encontrada em alguns pacientes desta epidemia, de *S. brasiliensis*.

Alguns isolados fúngicos obtidos de pacientes com aspectos clínicos curiosamente comuns, e outros exclusivos desta epidemia, foram fenotípica e genotipicamente analisados. Pudemos, então, detectar que *S. brasiliensis* esteve associado a estas formas outrora menos comuns ou inexistentes, como os quadros de esporotricose disseminada e as apresentações com hipersensibilidade.

O paciente com mais tempo de doença em atividade que acompanhamos, com quadro crônico disseminado e destrutivo, sem um retrospecto clínico condizente com tamanha exuberância nos intrigou. Graças à colaboração clínico-laboratorial, avaliamos cinco isolados obtidos deste paciente ao longo de cinco anos e constatamos que o fungo, da espécie *S. brasiliensis*, conseguiu se tornar mais virulento. Isto contribuiu para o entendimento, ainda que parcial, do desfecho desfavorável deste paciente com difícil manejo terapêutico.

A junção destes novos dados contribuiu para o conhecimento de que a espécie envolvida nesta epidemia tem comportamento singular e é diretamente responsável por novos aspectos clínicos observados.



Ministério da Saúde

**FIOCRUZ**  
**Fundação Oswaldo Cruz**

To the

***PLoS Neglected Tropical Diseases Editorial Board***

Rio de Janeiro, February 4<sup>th</sup>, 2014

Dear Sir,

It is our pleasure to submit our manuscript entitled “**Sporotrichosis in Rio de Janeiro, Brazil: Association of *Sporothrix brasiliensis* with unusual clinical presentations**” to the presubmission inquiry of the PLoS Neglected Tropical Diseases editorial board.

The genus *Sporothrix* comprises human thermal dimorphic fungi causing sporotrichosis, a worldwide distributed mycosis with areas of high endemicity in tropical and subtropical countries. This disease is considered the most prevalent systemic fungal infection in Brazil, especially in Rio de Janeiro, where the zoonotic transmission of this infection is out of control.

We have found that that sporotrichosis in Rio de Janeiro is a protracted epidemic yet to be curbed. More than 4,100 cases have been diagnosed in only one health institution of this state since 1998. Most patients are children and housewives living in contact with domestic or stray cats. They usually live under poverty conditions and we observed that the cases are concentrated in suburban regions of the metropolitan area lacking some basic health or sanitary conditions. For instance, most patients report that they need to have cats into their houses as a control for rodent population. Notification of sporotrichosis cases is not mandatory in many

countries. These factors appoint this infection as an important neglected disease in our countries.

Since the discovery of the cryptic species in the genus *Sporothrix* causing sporotrichosis, several basic studies have been performed with these species, especially *Sporothrix brasiliensis*, which is highly associated to the zoonotic endemic area of sporotrichosis that we previously described. Given the nomenclatural changes and advances in molecular taxonomy of *Sporothrix*, it is important to understand the clinical implications of these advances.

Our manuscript describes interesting aspects of sporotrichosis, regarding the newly described species in the *S. schenckii* complex, linking the species *S. brasiliensis* to several unusual manifestations of sporotrichosis and describing some treatment aspects of sporotrichosis caused by different *Sporothrix* species. The obtained data comprise the first comprehensive analysis of *S. brasiliensis* causing sporotrichosis and allow some analyses of pathological processes in sporotrichosis.

This article is part of our work on the endemic zoonotic of sporotrichosis. Our published experience has helped other Brazilian states and other countries as well, to control small outbreaks of cat-transmitted sporotrichosis, therefore keeping under control the sporotrichosis cases in these places. We believe that this manuscript represents a great contribution to those involved in this area, especially clinicians, with benefits to the patients with sporotrichosis.

We hope to hear from you soon.

Sincerely,

**Rodrigo de Almeida Paes, PhD**

Laboratório de Micologia / Instituto de Pesquisa Clínica Evandro Chagas

Fundação Oswaldo Cruz

Rio de Janeiro, RJ, Brazil

Tel: 55-21-38659642

e-mail: [rodrigo.paes@ipecc.fiocruz.br](mailto:rodrigo.paes@ipecc.fiocruz.br)

**Assun Your presubmission inquiry**

**De** PLOS Neglected Tropical Diseases <plosntds@plos.org>  
**Remet** <em.pntd.0.38f036.8f358c56@editorialmanager.com>  
**Para** Rodrigo Almeida-Paes <rodrigo.paes@ipec.fiocruz.br>  
**Data** 04-02-2014 20:20



---

Dear Dr. Almeida-Paes

Thank you very much for your presubmission inquiry to PLoS Neglected Tropical Diseases.

We are interested in your work, "Sporotrichosis in Rio de Janeiro, Brazil: Association of Sporothrix brasiliensis with unusual clinical presentations," and its relevance to neglected tropical diseases. The Editorial Board would like to invite you to submit your manuscript for full consideration at:  
<http://www.editorialmanager.com/pntd>

This decision reflects the Board's interest in the study you have described. However, please understand that the editorial decision to send a paper out for peer-review can only be made after we have the opportunity to evaluate the full-length manuscript.

When you do submit, please include mention of this presubmission inquiry and the manuscript number (PNTD-D-14-00198) in the "Previous Interactions" section of the submission form.

We look forward to receiving your paper.

Sincerely,

Peter Hotez  
Editor-in-Chief



24

25

### Abstract

26 In last years, several changes on *Sporothrix schenckii* taxonomy and clinical aspects of  
27 sporotrichosis have been reported. This study aims to determine the *Sporothrix* species  
28 associated with some classic and unusual clinical aspects of sporotrichosis observed at the  
29 endemic area of sporotrichosis in Rio de Janeiro, Brazil. To verify whether *S. brasiliensis* is  
30 associated with clinical manifestations of sporotrichosis, a cross-sectional study was  
31 performed in which 50 patients with different symptoms were analysed and their *Sporothrix*  
32 strains studied by phenotypic and genotypic methods. Data from these patients revealed a  
33 distinct clinical picture and therapeutic response in infections caused by *Sporothrix*  
34 *brasiliensis* (n=45) or *S. schenckii* sensu strictu (n=5). *S. brasiliensis* was associated with  
35 disseminated cutaneous infection without underlying disease, hypersensitivity reactions, and  
36 mucosal infection, whereas *S. schenckii* cases were related to a milder clinical presentation,  
37 similar to the majority of previously described sporotrichosis cases. In contrast, *S.*  
38 *brasiliensis*-infected patients seemed to respond better to antimycotic treatment with  
39 itraconazole. These findings suggest that *Sporothrix* species are linked to different clinical  
40 manifestations of sporotrichosis.

41

42

43

### **Author summary**

44 *Sporothrix brasiliensis* is a dimorphic fungus that is responsible for an endemic of cat-  
45 transmitted sporotrichosis in Rio de Janeiro, Brazil. Sporotrichosis in Rio de Janeiro is a  
46 protracted epidemic yet to be curbed. More than 4,100 human cases have been diagnosed in  
47 only one health institution since 1998. Most patients are children and housewives living in  
48 contact with domestic or stray cats. They usually live under poverty conditions and we  
49 observed that the cases are concentrated in suburban regions of the metropolitan area lacking  
50 some basic health or sanitary conditions. For instance, most patients report that they need to  
51 have cats into their houses as a control for rodent population. It is important to study the  
52 clinical aspects of the infection caused by this particular agent for better patient management,  
53 with improved therapeutic and profilatic approaches. We have found that this species is  
54 responsible for some unusual clinical manifestations of sporotrichosis, such as disseminated  
55 infection in immunocompetent patients and hypersensitivity reactions. Also, treatment with  
56 itraconazole appears to be extremely effective in most cases of infection by this agent. Our  
57 study will contribute for the management of the infection caused by *S. brasiliensis*, bringing  
58 benefits to the patients with sporotrichosis.

59

60

61



62

## Introduction

63 Sporotrichosis is a subcutaneous mycosis with a worldwide distribution that is currently  
64 notable for areas of especially high endemicity in Latin America [1-3]. Some authors classify  
65 sporotrichosis as an implantation mycosis, because this infection may also involve other sites  
66 like lymphatic vessels, muscles, fascia, cartilage, and bones, beyond the skin and the  
67 subcutaneous tissues [3]. This infection is caused by the dimorphic fungi previously described  
68 as the single species *Sporothrix schenckii* [1]. However, Marimon and coworkers [4], based  
69 on phenotypic and genotypic analyses, have suggested that several *Sporothrix* species cause  
70 sporotrichosis. They described four new species in the *Sporothrix* complex: (i) *S. globosa*, a  
71 globally distributed fungus [5-7]; (ii) *S. brasiliensis*, the species related to the zoonotic  
72 epidemic of sporotrichosis in Rio de Janeiro, Brazil [8]; (iii) *S. mexicana*, initially limited to  
73 Mexico [4], but with recent cases reported in other regions [9,10]; and (iv) *S. luriei*, formerly  
74 *S. schenckii* var. *luriei* [11].

75 Classical infection is associated with traumatic subcutaneous inoculation of soil, plants, or  
76 organic matter contaminated with fungus, with rare cases of transmission occurring from  
77 infected animals [1]. However in Rio de Janeiro state, Brazil, sporotrichosis is currently  
78 largely occurring via transmission from infected cats to humans [12]. Recently, our group  
79 performed a georeferencing survey of sporotrichosis cases that revealed a transmission belt  
80 along the border between Rio de Janeiro city and adjacent counties in the Greater  
81 Metropolitan Area [13]. Genotypic analyses show that isolates from the Rio de Janeiro  
82 epidemic have a high genetic similarity, which is suggestive of a common niche [14,15].

83 Although some studies have described several clinical aspects of this epidemic [12,16,17],  
84 taxonomic analyses have not been correlated with disease presentations. Therefore, the main  
85 purpose of this study was to investigate a possible association between manifestations of  
86 sporotrichosis and the different genomic species of *S. schenckii* sensu lato.

87

88 **Materials and Methods**

89 **Patients:** A cross-sectional study was performed in 50 patients with different clinical forms of  
90 sporotrichosis. They were selected from a database of 246 patients [8] who had *Sporothrix*  
91 strains obtained and stored from clinical specimens, and which were part of a cohort of 1,563  
92 patients with sporotrichosis treated from 1999 to 2008 at Instituto de Pesquisa Clínica  
93 Evandro Chagas (IPEC). Patients were submitted to a protocol that included clinical  
94 evaluation, mycological examination of clinical specimens and blood tests (blood count,  
95 biochemistry and liver function). First-choice treatment included oral itraconazole 100  
96 mg/day. If the lesions worsened or remained unchanged after eight weeks, higher doses were  
97 prescribed. Duration of treatment was determined by clinical cure (lesion healing defined as  
98 epithelization and absence of crusts, infiltrates, or erythema). Patients with the disseminated  
99 form to internal organs received amphotericin B at a total dose of 1 – 2.5 g. Clinical cure of  
100 extracutaneous sites was defined as the disappearance of preexisting lesions in cases of  
101 conjunctival, nasal, or oral mucosa involvement. Other criteria of cure were the disappearance  
102 or stabilization of lytic lesions upon bone radiography and tomography and sterilization of  
103 cerebrospinal fluid accompanied by improvement of cellularity and biochemistry patterns in  
104 the case of meningitis. HIV patients with CD4 counts  $\leq 200$  cells/ $\mu$ L received additional  
105 suppressive therapy. Follow-up was 4-12 weeks after clinical cure. The data were collected by  
106 review of medical charts and were recorded on a standardized case report form. These data  
107 included information concerning residence, demographics, duration of symptoms,  
108 occupational and other exposure risk factors, history of trauma, clinical findings, associated  
109 diseases, laboratory diagnosis and complementary test results, treatment schedule, response to  
110 therapy, and any other pertinent data.

111 Since the Rio de Janeiro sporotrichosis outbreak is massive, we had to establish some criteria  
112 to select patients related to common and unusual manifestations of sporotrichosis. Inclusion  
113 criteria for selection in this study were: patients who lived in Rio de Janeiro city or in other

114 cities from Rio de Janeiro state in Brazil, patients with common (fixed cutaneous and  
115 lymphocutaneous) and unusual (disseminated cutaneous, extracutaneous, and disseminated)  
116 clinical forms of sporotrichosis [1], patients with and without hypersensitivity manifestations  
117 (erythema nodosum or multiforme), HIV patients, patients that underwent itraconazole and  
118 patients with spontaneous regression of lesions. Patients are representative of each group.  
119 However, for the less common variables (e.g., patients outside the endemic area) all available  
120 cases were included. This study was approved by the Research Ethics Committee of Fundação  
121 Oswaldo Cruz (FIOCRUZ).

122 **Strains:** Fungal strains were isolated from different body sites of these patients such as skin,  
123 eyes, nose, or cerebrospinal fluid. They were previously identified by classical  
124 microbiological phenotypic techniques as *S. schenckii* sensu lato and they are maintained at  
125 the Pathogenic Fungal Collection of the Laboratório de Micologia at IPEC. Additionally,  
126 control strains CBS 120339 (*S. brasiliensis*) [4], ATCC 16345 (*S. schenckii*), IPEC 27135 (*S.*  
127 *globosa*) [7], and MUM 11.02 (*S. mexicana*) [9] were included in identification tests.

128 **Phenotypic Characterization:** Filamentous fungal colonies grown on Sabouraud Dextrose  
129 Agar were visually examined and slide cultures were mounted with Lactophenol Cotton Blue  
130 (Fluka Analytied, France) for *Sporothrix* identification [4]. Dimorphism was demonstrated by  
131 conversion to the yeast-like form on Brain Heart Infusion Agar slants for 7 days at 37°C.  
132 Furthermore, colonies were sub-cultured on Potato Dextrose Agar plates and Corn Meal Agar  
133 slants, and incubated at 30 and 37°C in the dark to study fungal growth and sporulation  
134 respectively [4,8]. Carbohydrate assimilation tests were performed using freshly prepared  
135 yeast nitrogen base (YNB) medium supplemented with sucrose or raffinose, using YNB  
136 supplemented with glucose as positive control and YNB without carbohydrates as a negative  
137 control. Experiments were performed at least three times on different days and, in case of  
138 discordant results, repeated two additional times. All culture media were from Difco (Becton,

139 Dickinson and Company / Sparks MD, USA). Results were interpreted according to the  
140 identification key detailed by Marimon and coworkers [11].

141 **Molecular Identification:** Genomic DNA was extracted and purified from *Sporothrix* spp  
142 mycelial phase by chloroform/isoamyl alcohol method as described [7]. The gene encoding  
143 for the nuclear calmodulin was used for molecular differentiation of the species because this  
144 locus has a high number of parsimony informative sites, allowing *Sporothrix* differentiation in  
145 several genotypes [18]. For partial sequencing of the nuclear calmodulin (CAL) gene, we used  
146 the primers CL1 (5'-GA(GA)T(AT)CAAGGAGGCCTTCTC-3'), and CL2A (5'-  
147 TTTTTCATCATGAGTTGGAC-3') under previously described conditions [7]. Automated  
148 sequencing was done using the Sequencing Platform at PDTIS/FIOCRUZ, Brazil [19].  
149 Sequences from both DNA strands were generated and edited with the Sequencher ver. 4.6  
150 software package (Genes Codes Corporation, USA), followed by alignment with Mega  
151 version 4.0.2 software. Our sequences were compared by BLAST (Basic Local Alignment  
152 Search Tool) with sequences available from NCBI GenBank (*Sporothrix* AM 398382.1 / AM  
153 398393.1 / AM 117444.1 / AM 116899.1 / AM 116908.1). All phylogenetic analyses were  
154 performed as previously described [7,8].

155 **Nucleotide sequence accession numbers:** All sequences from isolates included in genotypic  
156 analysis were deposited in the GenBank database under accession numbers GU456632,  
157 HQ426928 to HQ426962, and KC463890 to KC463903.

158 **Statistics:** Data were processed and analysed using the SPSS 17.0 software. Frequencies and  
159 median values were calculated for each group of this study.

160

## 161 **Results**

162 **Patients:** During the study period, 1,563 patients were diagnosed with sporotrichosis at our  
163 institution [12]. From these patients, we were able to retrieve a viable isolated *Sporothrix* spp.  
164 strain for 246 patients [8]. Fifty patients with complete clinical informations were selected

165 from them and included in the analyses of this work. They comprise 16 male and 34 female  
166 patients, with ages that ranged from 9 to 83 years (median=47). Lesions were located at upper  
167 limbs (n=31, 62%), lower limbs (n=6, 12%), face (n=1, 2%), trunk (n=1, 2%), and more than  
168 one segment (n=11, 22%). Fifteen patients (30%) presented the fixed cutaneous form, 24  
169 (48%) lymphocutaneous form, 6 (12%) disseminated cutaneous form, and 5 (10%)  
170 disseminated sporotrichosis. Additionally, six of these patients also presented erythema  
171 nodosum and four presented erythema multiforme associated to sporotrichosis. Table 1  
172 summarizes the clinical and mycological information for each patient.

173 **Mycological identification:** Of the 50 strains, 45 (90%) were classified by molecular  
174 methods as *S. brasiliensis* and 5 (10%) as *S. schenckii*. In 21 (42%) isolates, results from  
175 phenotypic tests analysed according to Marimon and coworkers [11] were inconclusive,  
176 precluding species differentiation; these strains were phenotypically classified as *Sporothrix*  
177 spp. Phenotypic identification of 10 (20%) isolates did not match to the genotypic results. In  
178 eight (16%) strains phenotypically classified as *S. schenckii*, DNA sequencing clustered them  
179 amid *S. brasiliensis*. The strain phenotypically classified as *S. mexicana* was genotypically  
180 identified as *S. schenckii*, and one *S. brasiliensis* was classified as *S. schenckii* by CAL  
181 sequencing.

182 **Mycological, clinical and epidemiological data:** Forty-two (93.3%) of the strains identified  
183 taxonomically as *S. brasiliensis* were from the Rio de Janeiro endemic area of sporotrichosis,  
184 that comprises beyond the Rio de Janeiro city, Duque de Caxias, Belford Roxo, Sao João de  
185 Meriti, Nova Iguaçu, Nilópolis, and Mesquita (Fig. 1). The other three (6.7%) *S. brasiliensis*  
186 strains were isolated from patients who lived in Teresópolis, a county 91 km away from Rio  
187 de Janeiro city. We observed a predominance of women infected with this species (n=32).  
188 The majority (n=40, 88.9%) was isolated from patients who had clear contact with cats. On  
189 the other hand, two *S. brasiliensis*-infected patients (4.4%) reported plant and glass trauma  
190 preceding sporotrichosis.

191 With respect to the five *S. schenckii*, four of them (80%) were isolated from patients who  
192 lived in three different rural regions and one urban area (in Itaboraí, Barra do Piraí, Casimiro  
193 de Abreu, and Teresópolis, respectively; 45, 100, 127, and 91 km away from Rio de Janeiro  
194 city) located in counties outside the endemic area. One strain of *S. schenckii* was isolated from  
195 a patient who lived within the zoonotic endemic sporotrichosis area in Rio de Janeiro. Three  
196 patients were male and two female.

197 Hypersensitivity reactions such as erythema nodosum or multiforme (10 cases), disseminated  
198 cutaneous forms (6 cases), and all but one case of lymphocutaneous sporotrichosis were all  
199 attributed to *S. brasiliensis*. Localized cutaneous forms were observed in patients infected  
200 with either *S. brasiliensis* (n=12, 26.7%) or *S. schenckii* (n=3, 60%). Disseminated disease  
201 occurred due to *S. schenckii* in one patient with AIDS, *S. brasiliensis* in two AIDS patients,  
202 and *S. brasiliensis* in one patient without any history of immunosuppression. Finally, there  
203 was one case of fixed cutaneous sporotrichosis caused by *S. brasiliensis* in a HIV infected  
204 patient with CD4>200 cells/ $\mu$ L.

205 **Treatment:** Four patients infected with *S. brasiliensis* were lost to follow-up, 3 after 4 weeks  
206 and the other after 12 weeks. The three AIDS patients with disseminated disease were  
207 excluded from analysis since they received amphotericin B as part of their antifungal regimen;  
208 however, these individuals were treated for more than 24 weeks. Spontaneous regression was  
209 observed in one patient infected with *S. schenckii* (fixed form) and three with *S. brasiliensis*  
210 (two fixed and one disseminated cutaneous forms). The remaining 3 cases of *S. schenckii*  
211 required 24 or 36 weeks of treatment. Two of these cases required increased itraconazole  
212 doses (200 and 400 mg/day). Most of the 35 patients infected by *S. brasiliensis* included in  
213 this analysis (82.9%) resolved with less than 24 weeks of treatment, despite their clinical  
214 form. For 8 *S. brasiliensis*-infected patients, up to 400 mg/day itraconazole were necessary for  
215 clinical cure. Among the patients with hypersensitivity associated to sporotrichosis, we  
216 observed equal medians for the time of treatment (16 weeks), when compared to the patients

217 without this manifestation. All of them were treated with 100 mg/day itraconazole, and  
218 increased doses were not necessary for clinical cure.

219

## 220 **Discussion**

221 Correlation between *S. schenckii* genotypes and clinical forms of sporotrichosis has been  
222 demonstrated by Kong and collaborators [20]. However, the relationship between genotypic  
223 results and treatment outcome or other unusual manifestations were not performed. To the  
224 best of our knowledge, this is the first work to present association between genotypic  
225 identification of *Sporothrix* species and several clinical aspects of sporotrichosis. Given the  
226 nomenclatural changes and advances in molecular taxonomy of *Sporothrix*, it is important to  
227 understand the clinical implications of these advances [21].

228 As expected, the majority of our isolates were now identified as *S. brasiliensis* by DNA  
229 analyses. Our group has previously characterized *S. brasiliensis* in 230 (93.5%) of 246  
230 isolates obtained from this endemic zoonotic transmission area [8]. Marimon and coworkers  
231 studying *Sporothrix* strains from several parts of the world reported only *S. brasiliensis*  
232 among the tested isolates from Rio de Janeiro [4]. There are a few reports of *S. brasiliensis* in  
233 Brazilian states other than Rio de Janeiro [10,22,23], but in these states, the frequency of *S.*  
234 *brasiliensis* appears to be lower than other *Sporothrix* species, with *S. schenckii*  
235 predominating [22].

236 The *S. brasiliensis* genotype was associated to the most frequent clinical forms of  
237 sporotrichosis (lymphocutaneous and fixed cutaneous). In the same vein, we confirm the  
238 unusual clinical forms of sporotrichosis like disseminated cutaneous sporotrichosis, without  
239 an underlying immunosuppressive condition, and mucosal involvement affecting nasal cavity  
240 or conjunctiva associated to this genotype. We were also able to correlate the previously  
241 reported cases of hypersensitivity manifestations (erythema nodosum and erythema  
242 multiforme) associated with zoonotic sporotrichosis [24,25] to *S. brasiliensis*. Recently,

243 Sweet syndrome was also described in patients with sporotrichosis [26], and studies are  
244 underway to confirm by calmodulin sequencing the species involved in these three cases.

245 Barros and coworkers [27] studied the treatment of cutaneous sporotrichosis with itraconazole  
246 of 645 patients from this epidemic, being 87 with erythema nodosum or erythema multiforme.  
247 They observed that these manifestations of hypersensitivity were associated with more rapid  
248 evolution for healing, compared with patients without these conditions. In this study the  
249 number of patients with this condition was small, because we could not retrieve viable strains  
250 from all these patients, and we did not find differences regarding treatment between the  
251 groups. However, most of these patients presented fixed cutaneous sporotrichosis. Although  
252 we could not prove in this study, we believe that hypersensitivity reactions may play a  
253 protective role in sporotrichosis, as observed in coccidioidomycosis [28].

254 The small number of *S. schenckii* related cases of sporotrichosis in our study brings some  
255 important information about the infection caused by this species. The majority of these cases  
256 occurred in rural counties where inhabitants develop agricultural activities, and therefore have  
257 contact with soil most frequently. Moreover, in two of these cases, patients denied cat contact.

258 It is worth mentioning that, in our previously reported case of *S. globosa*-related  
259 sporotrichosis, patient also denied cat contact [7]. Nevertheless, *S. schenckii* genotype was  
260 also identified in a case from the endemic zoonotic transmission area of sporotrichosis. In  
261 addition, we previously reported that 6.0% of 246 isolates obtained from Rio de Janeiro were  
262 characterized as *S. schenckii* by their phenotype [8]. Our results suggest that *S. schenckii* also  
263 circulates, in minor proportions, in this endemic area. In the same way, the only case of  
264 dissemination due to this species was associated to the immune status of the host that  
265 presented AIDS as an underlying immunosuppressive condition.

266 Several factors could influence the different outcomes of sporotrichosis, such as the size of  
267 initial inoculum, the host immune response status, depth of traumatic inoculation and fungal  
268 virulence [29]. Virulence studies have shown that only *S. brasiliensis* is able to kill



269 immunocompetent mice with a low fungal inoculum [30]. This same study concludes that  
270 lesional mechanisms could be species-specific, which is corroborated by our results. Zoonotic  
271 transmission of sporotrichosis by cats provides a high *Sporothrix* inoculum for humans, since  
272 these animals present a high fungal burden [31]. In some cases, fungal inoculation is  
273 repetitive, due to constant bites and scratches suffered by owners during cat treatment [32].  
274 These factors, coupled to the probable high virulence of *S. brasiliensis* [30], could account for  
275 the unusual clinical manifestations observed with this species.

276 Itraconazole is the drug of choice for sporotrichosis treatment [27]. It is interesting to note  
277 that, regardless the clinical form, there was a trend for a shorter treatment of the cases of  
278 sporotrichosis caused by *S. brasiliensis*, (median = 16 weeks) than the cases due to *S.*  
279 *schenckii* (median = 24 weeks), for our study. We are aware that the number of our *S.*  
280 *schenckii* sporotrichosis cases is scarce, but this finding might have a therapeutic implication.

281 It has been reported that *S. brasiliensis* is more susceptible to antifungal drugs, such as  
282 itraconazole, posaconazole, and ravuconazole, than *S. schenckii* [33]. Moreover, previous  
283 results of our group, which included eight *S. brasiliensis* from this study, showed a higher  
284 susceptibility of strains from the zoonotic endemic area [14]. Clinical, randomized studies  
285 should be performed to confirm these findings.

286 Since different *Sporothrix* species could be related to distinct clinical manifestations and  
287 outcomes, phenotypic and genotypic methods are important in the diagnosis. Phenotypic  
288 fungal identification is easier than molecular methods to apply in clinical laboratory routine  
289 tests. However, in a previous study from our group [8] as well as in studies from other groups  
290 [10], some discrepancies between these two methods of *Sporothrix* classification were  
291 observed. Since the differences between the species of the *S. schenckii* complex were  
292 observed at the molecular level [18], we considered DNA sequencing as the gold standard on  
293 species identification in the cases of this study, which included all discordant results from our  
294 previous work [8]. However, DNA sequencing is not a suitable methodology for routine

295 clinical laboratories. We recently described a simple and reliable T3B DNA fingerprinting  
296 methodology to identify the *S. schenckii* species complex at the DNA level [34], making it an  
297 alternative identification methodology for clinical microbiology laboratories.

298 In conclusion, we were able to confirm in this study by molecular analysis that *S. brasiliensis*  
299 is associated to classic and unusual manifestations of sporotrichosis, whereas our *S. schenckii*  
300 cases present a rather uniform clinical picture, comparable to that described on classic  
301 literature [1].

302

303 **Acknowledgements:** The authors thank Dr. Joshua Nosanchuk for his editorial assistance.  
304 Automated sequencing was done using the genomic platform/DNA sequencing platform at  
305 Fundação Oswaldo Cruz - PDTIS/FIOCRUZ (RPT01A), Brazil. This work was supported by  
306 Fundação de Amparo à Pesquisa do Estado do Rio de Janeiro [E-26/110.619/2012 and E-  
307 26/103.157/2011 to R.M.Z-O.], Conselho Nacional de Desenvolvimento Científico e  
308 Tecnológico [350338/2000-0 to R.M.Z-O.], and Coordenação de Aperfeiçoamento de Pessoal  
309 de Nível Superior [2445/11-5 to M.M.E.O.].

310

311

312

### 313 **References**

- 314 1. Barros MBL, Almeida-Paes R, Schubach AO (2011) *Sporothrix schenckii* and  
315 Sporotrichosis. Clin Microbiol Rev 24: 633-654.
- 316 2. Conti Diaz IA (1989) Epidemiology of sporotrichosis in Latin America. Mycopathologia  
317 108: 113-116.
- 318 3. Queiroz-Telles F, Nucci M, Colombo AL, Tobon A, Restrepo A (2011) Mycoses of  
319 implantation in Latin America: an overview of epidemiology, clinical manifestations,  
320 diagnosis and treatment. Med Mycol 49: 225-236.

- 321 4. Marimon R, Cano J, Gene J, Sutton DA, Kawasaki M, et al. (2007) *Sporothrix*  
322 *brasiliensis*, *S. globosa*, and *S. mexicana*, three new *Sporothrix* species of clinical  
323 interest. J Clin Microbiol 45: 3198-3206.
- 324 5. Cruz R, Vieille P, Oschilewski D (2012) Aislamiento ambiental de *Sporothrix globosa* en  
325 relación a un caso de esporotricosis linfo-cutánea. Rev Chilena Infectol 29: 401-405.
- 326 6. Madrid H, Cano J, Gene J, Bonifaz A, Toriello C, et al. (2009) *Sporothrix globosa*, a  
327 pathogenic fungus with widespread geographical distribution. Rev Iberoam Micol 26:  
328 218-222.
- 329 7. Oliveira MME, Almeida-Paes R, Muniz MM, Barros MBL, Gutierrez-Galhardo MC, et  
330 al. (2010) Sporotrichosis caused by *Sporothrix globosa* in Rio de Janeiro, Brazil: case  
331 report. Mycopathologia 169: 359-363.
- 332 8. Oliveira MME, Almeida-Paes R, Muniz MM, Gutierrez-Galhardo MC, Zancoppe-Oliveira  
333 RM (2011) Phenotypic and molecular identification of *Sporothrix* isolates from an  
334 epidemic area of sporotrichosis in Brazil. Mycopathologia 172: 257-267.
- 335 9. Dias NM, Oliveira MME, Santos C, Zancoppe-Oliveira RM, Lima N (2011)  
336 Sporotrichosis caused by *Sporothrix mexicana*, Portugal. Emerg Infect Dis 17: 1975-  
337 1976.
- 338 10. Rodrigues AM, de Hoog S, Camargo ZP (2013) Emergence of pathogenicity in the  
339 *Sporothrix schenckii* complex. Med Mycol 51: 405-412.
- 340 11. Marimon R, Gene J, Cano J, Guarro J (2008) *Sporothrix luriei*: a rare fungus from  
341 clinical origin. Med Mycol 46: 621-625.
- 342 12. Freitas DFS, Valle ACF, Almeida Paes R, Bastos FI, Gutierrez-Galhardo MC (2010)  
343 Zoonotic Sporotrichosis in Rio de Janeiro, Brazil: a protracted epidemic yet to be curbed.  
344 Clin Infect Dis 50: 453.

- 345 13. Silva MB, Costa MM, Torres CC, Gutierrez-Galhardo MC, Valle ACF, et al. (2012)  
346 Esporotricose urbana: epidemia negligenciada no Rio de Janeiro, Brasil. Cad Saude  
347 Publica 28: 1867-1880.
- 348 14. Gutierrez-Galhardo MC, Zancopé-Oliveira RM, Valle ACF, Almeida-Paes R, Tavares  
349 PMS, et al. (2008) Molecular epidemiology and antifungal susceptibility patterns of  
350 *Sporothrix schenckii* isolates from a cat-transmitted epidemic of sporotrichosis in Rio de  
351 Janeiro, Brazil. Med Mycol 46: 141-151.
- 352 15. Reis RS, Almeida-Paes R, Muniz MM, Tavares PMS, Monteiro PCF, et al. (2009)  
353 Molecular characterisation of *Sporothrix schenckii* isolates from humans and cats  
354 involved in the sporotrichosis epidemic in Rio de Janeiro, Brazil. Mem Inst Oswaldo  
355 Cruz 104: 769-774.
- 356 16. Barros MBL, Schubach AO, Schubach TMP, Wanke B, Lambert-Passos SR. (2008) An  
357 epidemic of sporotrichosis in Rio de Janeiro, Brazil: epidemiological aspects of a series  
358 of cases. Epidemiol Infect 136: 1192-1196.
- 359 17. Barros MBL, Schubach TMP, Gutierrez-Galhardo MC, Schubach AO, Monteiro PCF, et  
360 al. (2001) Sporotrichosis: an emergent zoonosis in Rio de Janeiro. Mem Inst Oswaldo  
361 Cruz 96: 777-779.
- 362 18. Marimon R, Gene J, Cano J, Trilles L, Lazera MS, et al. (2006) Molecular phylogeny of  
363 *Sporothrix schenckii*. J Clin Microbiol 44: 3251-3256.
- 364 19. Otto TD, Vasconcellos EA, Gomes LH, Moreira AS, Degraeve WM, et al. (2008)  
365 ChromaPipe: a pipeline for analysis, quality control and management for a DNA  
366 sequencing facility. Genet Mol Res 7: 861-871.
- 367 20. Kong X, Xiao T, Lin J, Wang Y, Chen HD (2006) Relationships among genotypes,  
368 virulence and clinical forms of *Sporothrix schenckii* infection. Clin Microbiol Infect 12:  
369 1077-1081.

- 370 21. de Hoog GS, Haase G, Chaturvedi V, Walsh TJ, Meyer W, et al. (2013) Taxonomy of  
371 medically important fungi in the molecular era. *Lancet Infect Dis* 13: 385-386.
- 372 22. Oliveira DC, Lopes PG, Spader TB, Mahl CD, Tronco-Alves GR, et al. (2011)  
373 Antifungal susceptibilities of *Sporothrix albicans*, *S. brasiliensis*, and *S. luriei* of the *S.*  
374 *schenckii* complex identified in Brazil. *J Clin Microbiol* 49: 3047-3049.
- 375 23. Silva-Vergara ML, Camargo ZP, Silva PF, Abdalla MR, Sgarbieri RN, et al. (2012)  
376 Disseminated *Sporothrix brasiliensis* infection with endocardial and ocular involvement  
377 in an HIV-infected patient. *Am J Trop Med Hyg* 86: 477-480.
- 378 24. Gutierrez-Galhardo MC, Barros MBL, Schubach AO, Cuzzi T, Schubach TMP, et al.  
379 (2005) Erythema multiforme associated with sporotrichosis. *J Eur Acad Dermatol*  
380 *Venereol* 19: 507-509.
- 381 25. Gutierrez-Galhardo MC, Schubach AO, Barros MBL, Moita-Blanco TC, Cuzzi-Maya T,  
382 et al. (2002) Erythema nodosum associated with sporotrichosis. *Int J Dermatol* 41: 114-  
383 116.
- 384 26. Freitas DFS, Valle ACF, Cuzzi T, Brandao LG, Zancope-Oliveira RM, et al. (2012)  
385 Sweet syndrome associated with sporotrichosis. *Br J Dermatol* 166: 212-213.
- 386 27. Barros MBL, Schubach AO, Oliveira RVC, Martins EB, Teixeira JL, et al. (2011)  
387 Treatment of cutaneous sporotrichosis with itraconazole - study of 645 patients. *Clin*  
388 *Infect Dis* 52: e200-206.
- 389 28. Arsura EL, Kilgore WB, Ratnayake SN (1998) Erythema nodosum in pregnant patients  
390 with coccidioidomycosis. *Clin Infect Dis* 27: 1201-1203.
- 391 29. Carlos IZ, Sassa MF, Sgarbi DBG, Placeres MC, Maia DC (2009) Current research on  
392 the immune response to experimental sporotrichosis. *Mycopathologia* 168: 1-10.
- 393 30. Arrillaga-Moncrieff I, Capilla J, Mayayo E, Marimon R, Marine M, et al. (2009)  
394 Different virulence levels of the species of *Sporothrix* in a murine model. *Clin Microbiol*  
395 *Infect* 15: 651-655.

- 396 31. Schubach TMP, Schubach AO, Okamoto T, Barros MBL, Figueiredo FB, et al. (2004)  
397 Evaluation of an epidemic of sporotrichosis in cats: 347 cases (1998-2001). J Am Vet  
398 Med Assoc 224: 1623-1629.
- 399 32. Schubach AO, Schubach TMP, Barros MBL (2005) Epidemic cat-transmitted  
400 sporotrichosis. N Engl J Med 353: 1185-1186.
- 401 33. Marimon R, Serena C, Gene J, Cano J, Guarro J (2008) In vitro antifungal susceptibilities  
402 of five species of *Sporothrix*. Antimicrob Agents Chemother 52: 732-734.
- 403 34. Oliveira MME, Sampaio P, Almeida-Paes R, Pais C, Gutierrez-Galhardo MC, et al.  
404 (2012) Rapid identification of *Sporothrix* species by T3B fingerprinting. J Clin Microbiol  
405 50: 2159-2162.  
406

407 **Table 1:** Clinical, epidemiological, and mycological aspects of 50 sporotrichosis cases.

Strain	Cat	Clinical form	Erythema	Treatment (weeks)	Phenotypic identification	Genotypic characterization		
						Final identification	Genbank n°	References
16490	Yes	Lymphocutaneous		13	<i>S. brasiliensis</i>	<i>S. brasiliensis</i>	AM116899	19
16919	Yes	Lymphocutaneous		16	<i>S. brasiliensis</i>	<i>S. brasiliensis</i>	HQ426930	24
17307	Yes	Disseminated Cutaneous		20	<i>S. schenckii</i>	<i>S. brasiliensis</i>	KC463892	This study
17331	Yes	Disseminated Cutaneous		36	<i>S. brasiliensis</i>	<i>S. brasiliensis</i>	HQ426929	This study
17521	Yes	Lymphocutaneous		36	<i>S. brasiliensis</i>	<i>S. schenckii</i>	KC463901	This study
17585	Yes	Fixed		24	<i>S. schenckii</i>	<i>S. schenckii</i>	KC463902	This study
17786	Yes	Lymphocutaneous		36	<i>Sporothrix spp.</i>	<i>S. brasiliensis</i>	HQ426931	This study
17878	Yes	Fixed	EN <sup>a</sup>	12	<i>Sporothrix spp.</i>	<i>S. brasiliensis</i>	HQ426932	24
24372	No	Disseminated		44 (AIDS)	<i>S. schenckii</i>	<i>S. schenckii</i>	KC463903	This study
25011	Yes	Fixed	EM <sup>b</sup>	16	<i>S. brasiliensis</i>	<i>S. brasiliensis</i>	HQ426935	24
25303	No	Disseminated		260 (AIDS)	<i>S. schenckii</i>	<i>S. brasiliensis</i>	KC463891	This study
25374	Yes	Lymphocutaneous	EN	Lost	<i>S. brasiliensis</i>	<i>S. brasiliensis</i>	KC463894	This study
25457	Yes	Lymphocutaneous		Lost	<i>S. brasiliensis</i>	<i>S. brasiliensis</i>	KC463890	This study
25521	Yes	Disseminated		20	<i>Sporothrix spp.</i>	<i>S. brasiliensis</i>	HQ426936	24
25758	Yes	Lymphocutaneous		16	<i>S. brasiliensis</i>	<i>S. brasiliensis</i>	KC463895	This study
26611	Yes	Fixed	EM	16 (HIV)	<i>Sporothrix spp.</i>	<i>S. brasiliensis</i>	HQ426937	24
26938	Yes	Fixed		48	<i>Sporothrix spp.</i>	<i>S. brasiliensis</i>	HQ426938	25
26945	No	Lymphocutaneous		14	<i>Sporothrix spp.</i>	<i>S. brasiliensis</i>	HQ426939	25
26961	No	Fixed		24	<i>S. schenckii</i>	<i>S. schenckii</i>	JN995605	25

27022	Yes	Disseminated Cutaneous		8	<i>S. brasiliensis</i>	<i>S. brasiliensis</i>	HQ426940	24
27052	No	Fixed	EN	12	<i>Sporothrix spp.</i>	<i>S. brasiliensis</i>	HQ426941	25
27087	Yes	Lymphocutaneous		64	<i>S. brasiliensis</i>	<i>S. brasiliensis</i>	HQ426942	25
27100	Yes	Fixed		36	<i>S. schenckii</i>	<i>S. brasiliensis</i>	JN995609	25
27130	Yes	Lymphocutaneous		16	<i>Sporothrix spp.</i>	<i>S. brasiliensis</i>	HQ426943	24
27133	Yes	Fixed		Lost	<i>S. schenckii</i>	<i>S. brasiliensis</i>	JN995608	25
27177	Yes	Lymphocutaneous		6	<i>Sporothrix spp.</i>	<i>S. brasiliensis</i>	HQ426944	24
27209	Yes	Lymphocutaneous		12	<i>Sporothrix spp.</i>	<i>S. brasiliensis</i>	HQ426946	25
27288	Yes	Lymphocutaneous		104	<i>Sporothrix spp.</i>	<i>S. brasiliensis</i>	HQ426945	25
27372	Yes	Fixed	EM	12	<i>Sporothrix spp.</i>	<i>S. brasiliensis</i>	HQ426947	25
27375	Yes	Fixed	EN	SR <sup>c</sup>	<i>S. schenckii</i>	<i>S. brasiliensis</i>	KC463898	This study
27387	Yes	Lymphocutaneous		12	<i>Sporothrix spp.</i>	<i>S. brasiliensis</i>	HQ426948	24
27417	No	Lymphocutaneous		16	<i>Sporothrix spp.</i>	<i>S. brasiliensis</i>	HQ426949	25
27445	Yes	Disseminated Cutaneous		SR	<i>S. brasiliensis</i>	<i>S. brasiliensis</i>	HQ426950	25
27454	Yes	Lymphocutaneous		22	<i>S. brasiliensis</i>	<i>S. brasiliensis</i>	KC463896	This study
27558	Yes	Fixed		12	<i>S. schenckii</i>	<i>S. brasiliensis</i>	KC463899	This study
27722	No	Fixed		SR	<i>S. mexicana</i>	<i>S. schenckii</i>	HQ426961	24
27930	No	Lymphocutaneous		10	<i>Sporothrix spp.</i>	<i>S. brasiliensis</i>	HQ426951	24
28329	Yes	Lymphocutaneous		16	<i>S. schenckii</i>	<i>S. brasiliensis</i>	JN995610	25
28403	Yes	Lymphocutaneous		10	<i>Sporothrix spp.</i>	<i>S. brasiliensis</i>	KC463900	This study
28487	Yes	Disseminated Cutaneous	EN	16	<i>S. brasiliensis</i>	<i>S. brasiliensis</i>	HQ426928	24
28604	Yes	Lymphocutaneous		10	<i>S. brasiliensis</i>	<i>S. brasiliensis</i>	HQ426953	24
28665	Yes	Fixed		SR	<i>S. brasiliensis</i>	<i>S. brasiliensis</i>	JN995606	25
28701	Yes	Disseminated Cutaneous		20	<i>Sporothrix spp.</i>	<i>S. brasiliensis</i>	HQ426954	24
28772	Yes	Lymphocutaneous		12	<i>Sporothrix spp.</i>	<i>S. brasiliensis</i>	HQ426955	24
28790	Yes	Lymphocutaneous		4	<i>S. brasiliensis</i>	<i>S. brasiliensis</i>	HQ426956	24



28988	Yes	Lymphocutaneous	EM	12	<i>S. schenckii</i>	<i>S. brasiliensis</i>	KC463897	This study
30650	Yes	Disseminated	EN	16	<i>S. brasiliensis</i>	<i>S. brasiliensis</i>	KC463893	This study
33605	Yes	Disseminated		34 (AIDS)	<i>Sporothrix spp.</i>	<i>S. brasiliensis</i>	HQ426957	24
33722	Yes	Lymphocutaneous		12	<i>Sporothrix spp.</i>	<i>S. brasiliensis</i>	HQ426958	24
34007	Yes	Fixed		Lost	<i>Sporothrix spp.</i>	<i>S. brasiliensis</i>	HQ426959	24

408

409 <sup>a</sup> EN: erythema nodosum

410 <sup>b</sup> EM : erythema multiforme

411 <sup>c</sup> SR: spontaneous regression of lesions

412

413

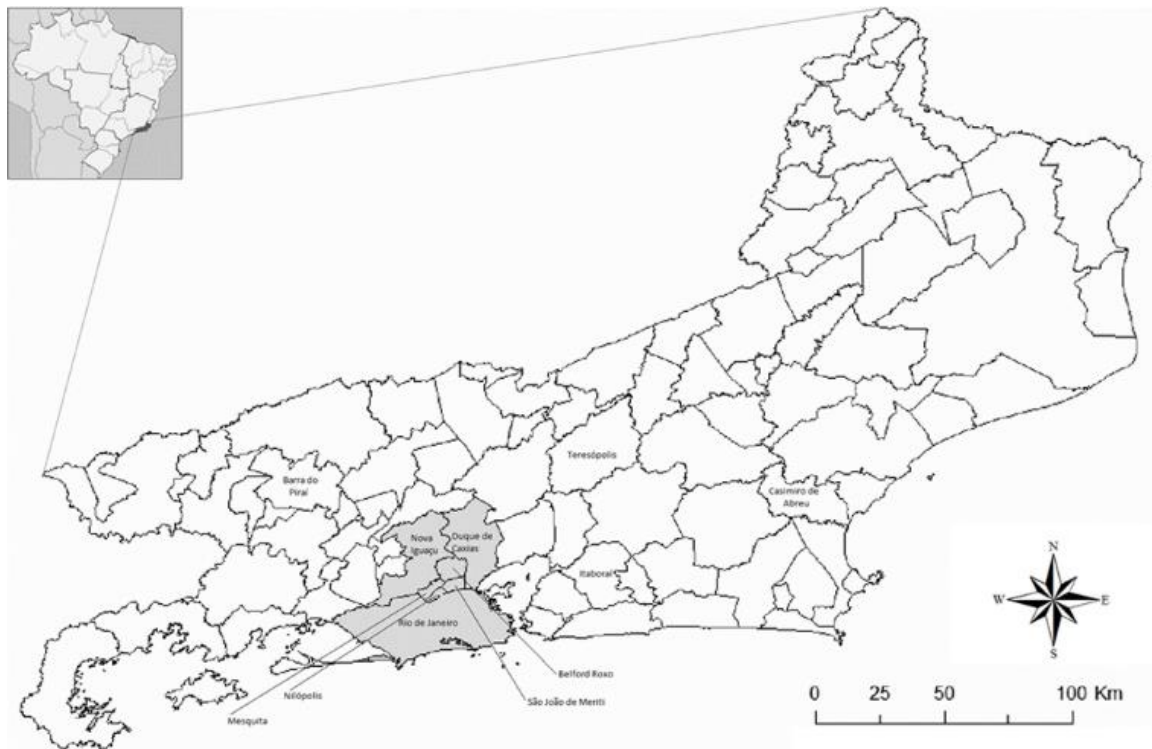
414

415

416 **Figure legends**

417

418 **Fig. 1: Map of Rio de Janeiro state, Brazil.** Names of the cities of origin of the 50 patients  
419 included in this study are indicated. Cities in gray, which comprise the Rio de Janeiro  
420 metropolitan area, are related to the zoonotic endemic area of sporotrichosis.



421

## Increase in virulence of *Sporothrix brasiliensis* over five years in a patient with chronic disseminated sporotrichosis

**Running title:** Increase in virulence of *Sporothrix brasiliensis*

Dayvison Francis Saraiva Freitas<sup>1,3</sup>, Suelen Silvana dos Santos<sup>2,3</sup>, Rodrigo Almeida-Paes<sup>1</sup>, Manoel Marques Evangelista de Oliveira<sup>1</sup>, Antônio Carlos Francesconi do Valle<sup>1</sup>, Maria Clara Gutierrez-Galhardo<sup>1</sup>, Rosely Maria Zancopé-Oliveira<sup>1</sup>, Joshua D. Nosanchuk<sup>3</sup>

<sup>1</sup>Instituto de Pesquisa Clínica Evandro Chagas, Fiocruz, Rio de Janeiro, RJ, Brazil.

<sup>2</sup>Faculdade de Ciências Farmacêuticas, Universidade de São Paulo, São Paulo, SP, Brazil.

<sup>3</sup>Albert Einstein College of Medicine, New York, NY, USA.

Correspondence: Dayvison F. S. Freitas, PhD Student in Tropical Medicine  
Instituto Oswaldo Cruz – IOC / Fiocruz - Av. Brasil, 4365 - Manguinhos  
21040-360 - Rio de Janeiro – Brazil - [dayvison.freitas@ipecc.fiocruz.br](mailto:dayvison.freitas@ipecc.fiocruz.br) / Phone:+55 21  
996745084

### Abstract

**Background:** The metropolitan region of Rio de Janeiro is hyperendemic for cat-associated sporotrichosis. Patients have presented with fixed and lymphangitic sporotrichosis, disseminated disease, involvement of the conjunctival mucosa and manifestations of hypersensitivity, and patients have also had chronic forms and relapses. The current study aimed to assess the virulence of different fungal isolates from a patient with chronic, destructive disseminated sporotrichosis.

**Methodology/Principal Findings:** The patient, a 61-year-old male retired bricklayer with diabetes and hypertension, was referred to the laboratory of dermatology at the Instituto de Pesquisa Clínica Evandro Chagas due to a 6-year history of cutaneous lesions. He had multiple scars on all extremities, and an exudative small ulcerated lesion on the dorsum of the left wrist. There was ankylosis of the left wrist and knees. Previously, he had received five months of potassium iodide, with healing of some lesions, but others relapsed. Radiographs showed lytic lesions and sclerosis at the knees and left wrist. *Sporothrix* was cultured from skin exudates and bone samples. He was treated with terbinafine 500 mg/day for 32 months, until the skin healed and the radiographic patterns stabilized. Eleven months later, the skin lesions reappeared on his left forearm and treatment was restarted. We

analyzed five isolates collected from this patient over a five-year period, and all were molecularly identified as *Sporothrix brasiliensis*. No differences in virulence were detected by *in vitro* assays, but *in vivo* studies in *Galleria mellonella* larvae revealed an increase in virulence of the later isolate.

**Conclusions/Significance:** We concluded that *S. brasiliensis* may increase in virulence *in vivo*, promoting its survival under parasitic conditions.

**Key words:** Virulence; *Sporothrix brasiliensis*; sporotrichosis; disseminated; *Galleria mellonella*; Rio de Janeiro; Brazil.

## Introduction

Sporotrichosis is a subcutaneous mycosis caused by the dimorphic fungus previously described as the single species *Sporothrix schenckii*, now understood as a complex with different species of clinical interest (Marimon et al., 2007). Molecular studies have identified *Sporothrix globosa*, *Sporothrix mexicana*, *Sporothrix brasiliensis* and *S. schenckii* as responsible to sporotrichosis in different regions (Marimon et al., 2007; Madrid et al., 2009; Oliveira et al., 2011; Rodrigues et al., 2013a, 2013b; Yu et al., 2013; Liu et al., 2014).

The metropolitan region of Rio de Janeiro is hyperendemic for cat-associated sporotrichosis. Patients have presented with fixed and lymphangitic sporotrichosis, disseminated disease, involvement of the conjunctival mucosa and manifestations of hypersensitivity, and patients have also had chronic forms and relapses (Freitas et al., 2010; Barros et al., 2011). Disseminated cases without immunosuppression have been more common than usually reported for other regions, and possible explanations for that are the multiple and deep inoculums that a cat can promote when transmitting the fungus to a human (Freitas et al., 2012), and a higher virulence of the pathogen (Arrillaga-Moncrieff et al., 2009). Molecular and phenotypic studies showed the association of *Sporothrix brasiliensis* with this epidemic (Marimon et al., 2007; Oliveira et al., 2011).

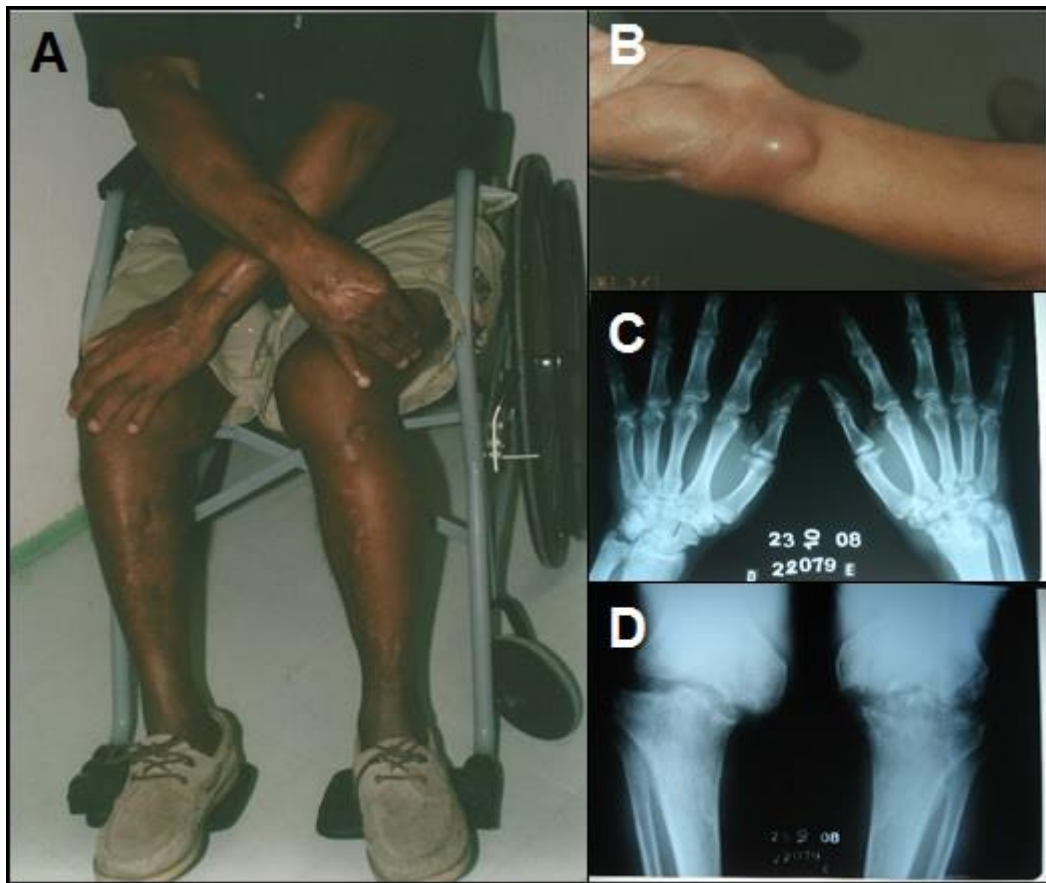
The host-pathogen interaction is of importance when analyzing these unusual cases. Candidate factors from the pathogen to make the infection more successful are the size of inoculum, thermotolerance, production of enzymes and other molecules, resistance to oxidative stress and to antifungals. There is some

information about virulence of *S. brasiliensis* (Arrillaga-Moncricieff et al., 2009; Almeida-Paes et al., 2009; 2012; Fernandes et al., 2013), but still scarce.

The aim of this study is to describe the virulence of different fungal isolates from a patient with chronic, destructive disseminated sporotrichosis.

## Case Report

A 61-year-old retired bricklayer with diabetes and hypertension was referred to the laboratory of infectious dermatology at the Instituto de Pesquisa Clínica Evandro Chagas (IPEC) due to a 6-year history of cutaneous lesions. He had multiple scars on the limbs, an exudative small ulcerated lesion and a cystic lesion on the dorsum of the left wrist (**Figure 1A-B**). There was ankylosis of the left wrist and knees. Previously, he had received five months of potassium iodide, and referred healing of the lesions, but others relapsed. Radiographs showed lytic lesions and sclerosis at the knees and left wrist (**Figure 1C-D**). Tests for HIV and HTLV were negative. The total lymphocyte count was 1,470/ $\mu\text{L}$  and the T CD4<sup>+</sup> count was 554/ $\mu\text{L}$ , both normal. The number of naïve T cells was considerably low (24/ $\mu\text{L}$ ). *Sporothrix* spp. was cultured from a skin lesion on the left wrist and serology for sporotrichosis was positive (2.548 / Cut-Off: 0.605). Due to possible harmful interactions of his regular drugs with itraconazole, he was treated with terbinafine 500 mg/day for 32 months, until the skin healed and the radiographic patterns stabilized. Eleven months after the suspension of the treatment, the skin lesions reappeared on his left forearm and treatment was restarted, with healing of this lesion, but a new cutaneous ulcerated nodule appeared on the left knee. New skin samples were collected over the years, from the left forearm and the left knee, as well as a biopsy sample from the left knee bone. Nowadays he is still under treatment with terbinafine 500 mg/day, no cutaneous lesions, but with altered radiographs of the knees and left wrist (confirmed by magnetic resonance), and a permanent need for a wheelchair.



**Figure 1.** A) Multiple scars on the limbs, where previously the cutaneous lesions were. B) Inflammatory cyst on the left wrist. The first three isolates were collected from that lesion, by puncture with fine needle in different time points, across six months. C-D) Radiographs showed lytic lesions and sclerosis at the left wrist and knees.

## Materials and Methods

### Clinical specimens

Five samples were collected from the lesions of the aforementioned patient, over a 5-year-period. The first three samples (IPEC32742, IPEC33070 and IPEC33718, thereafter denominated “1”, “2” and “3”, respectively) were collected by sterile puncture with a fine needle from a cystic lesion on the left wrist between September 2007 and March 2008; the fourth sample (IPEC33946, thereafter denominated “4”) was from a bone biopsy of the left knee in April 2008; and the fifth sample (IPEC43174, thereafter denominated “5”) was from an ulcerated nodule on the skin of the left knee in February 2012.

### **Sporotrichosis diagnosis**

Clinical specimens were kept in a sterile flask with saline. All samples underwent routine mycological examination, which involved direct microscopy of wet mount preparations with 10% potassium hydroxide and seeding on Sabouraud dextrose agar, modified and mycobiotic agar (Difco), incubation at 25°C, and observation during four weeks for fungal growth. Suspected isolates were sub-cultivated on potato dextrose agar medium (Difco) at 25°C for macroscopic and microscopic morphological studies, and dimorphism was demonstrated by conversion to the yeast-like form on brain heart infusion (BHI) agar medium (Difco) at 37°C. The isolates were stored at the laboratory of mycological diagnosis of IPEC.

### **Molecular identification**

Genomic DNA was extracted from the yeast phase of the five *Sporothrix* isolates by the method of phenol-chloroform, and a polymerase chain reaction (PCR) was performed with the primer T3B (5'-AGGTCGCGGGTTCGAATCC-3'), as previously described for the rapid identification of species of the *Sporothrix schenckii* complex, (Oliveira et al., 2012). Amplification of the samples was confirmed by viewing the amplicons after electrophoresis on 1% agarose gel (Agarose Ultra-Pure - Invitrogen) in 0.5X TBE (0.1 M Tris, 0.09 M boric acid, 0.001 M EDTA, pH 8.4). Five microliters of the PCR products were added to each well of the gel, electrophoresis was conducted at 80V for 45 to 60 minutes, the gel was stained with ethidium bromide 0.5 µg/mL for 30 minutes and washed with distilled water 30 minutes before being examined under UV transilluminator - Hoefer Scientific Inc. The strains used for controls were *S. brasiliensis* (CBS120339), *S. mexicana* (MUM11.02), *S. Schenckii* (IPEC36277) and *S. globosa* (IPEC27135).

### **Growth curves**

Yeasts of each of the five isolates were obtained after 3 days of growth on BHI broth (Difco) at 37°C. A Bioscreen C Microbiological Growth Analyser (Labsystems, Helsinki, Finland) was used for the measurement of the turbidity, adapted from the described by Medina et al. (2011). Nonstandard, 100-well microtitre plates specifically manufactured for this machine were loaded with  $2 \times 10^4$  yeasts in 200 µL BHI broth (Difco), in quadruplicates. The O.D. was recorded every 30 min using the 600 nm filter over a 3-day period. Experiments were conducted at 37°C, with constant shaking. The control wells contained only the culture medium. Data were

recorded using the software Easy Bioscreen Experiment (EZExperiment) provided by the manufacturer.

### **Macrophage assays**

*In vitro* virulence assays with J774 macrophages were performed to determine the ability of the macrophages to phagocytose and kill the *Sporothrix* yeasts, as well as the viability of the macrophages after this interaction (Nicola; Casadevall, 2012). Macrophages of the J774 lineage were grown in monolayer in culture plates, in a medium containing 10% fetal bovine serum, 10% NCTC-109, 1% non-essential amino acids and 1% penicillin/streptomycin diluted in Dulbecco's Modified Eagle's medium (DMEM), at 37°C, 10% CO<sub>2</sub>, and split onto 96-well plates. Yeasts of the five *Sporothrix* isolates, previously opsonized for 30 min by incubation with Guinea pig serum complement were added to the monolayer of the macrophages, in a 5:1 ratio.

To characterize the virulence of the isolates, three different experiments were performed:

a. Phagocytosis assays to measure and compare the ability of the macrophages to phagocytose the yeasts. After 2 h of interaction, the medium was removed, the cells washed twice with PBS (phosphate-buffered saline) 1X, fixed with methanol at -20°C for 30 min, and stained with 20X-diluted Giemsa at 4°C. After an overnight incubation, macrophages interacting with yeast cells (adherent or ingested) and the total number of macrophages were counted, to calculate the ratio between them.

b. Fungal killing assay (or fungicidal ability of macrophages) – for this experiment, the same yeast-macrophage interaction was performed, however, after 2 h, the wells were washed and the medium was changed so that only yeasts attached to, or ingested by macrophages remained. Then, after 18 h of interaction, cells were removed from the wells, macrophages were lysed to release the yeasts from inside by addition of sterile distilled water, the contents were diluted serially and plated on BHI agar to determine fungal viability, by colony-forming units (CFUs). Controls obtained from wells without macrophages were also plated to determine the number of CFUs and consequent percentage of fungicidal activity of macrophages for each isolate.

c. Viability of macrophages - after the same yeast-macrophage interaction, as described above, wells were washed and stained with trypan blue, a vital stain that does not penetrate the viable macrophages, although it stains in blue



dead macrophages. Thus, it was possible to determine the percentage of live macrophages after 18 h of interaction with the different yeast isolates and compare them.

### ***In vivo* experiments**

To assess the virulence *in vivo*, larvae of the lepidoptera *Galleria mellonella* were inoculated using 25  $\mu$ L Hamilton® syringes with  $10^4$ ,  $10^6$  or  $10^7$  yeasts of one of the five *Sporothrix* isolates and the survival rate was analyzed (Thomaz et al., 2013). As a control, another group of larvae was inoculated with the reference strain of *S. brasiliensis* (CBS120339). The inoculums were diluted in 10  $\mu$ L PBS. Two negative control groups were made. One, designated “Control”, was constituted by larvae without any inoculation and another, designated “PBS”, was made by inoculating larvae with 10  $\mu$ L sterile PBS. These experiments were performed in triplicate on different days. Each group of larvae had 20 individuals, stored in 90 mm Petri dishes at 37°C and was accompanied by daily count, to check survival. The groups were photographed (Canon EOS DIGITAL REBEL) at days 0 (day of inoculation) and 2 (48 h after inoculation). Dead individuals (recognized by absence of active or touch-induced movement and usually dark-colored) were removed from the group and discarded, until the last remaining. Survival curves were obtained in order to compare the effect of the isolates on the larvae.

Parallel groups, of 10 larvae each, under the same conditions were followed. Three larvae from each group were sacrificed after three or six days of inoculation. The internal content was macerated and homogenized in 2 mL PBS, and then filtered through 40  $\mu$ m-cell strainers. An aliquot of 100  $\mu$ L of this homogenate was plated onto BHI agar with 0.4 g / L cycloheximide and 1% penicillin / streptomycin to prevent growth of contaminants, and incubated at 37°C. After five days, the CFUs were counted.

### **Production of virulence factors**

**Urease.** To verify the urease production, 0.5 mL of a suspension equivalent to a 2.0 McFarland scale of yeast cells of each isolate was inoculated in 4.5 mL of Christensen urea broth (Christensen, 1946; Kane; Fischer, 1971), and incubated at 37°C. After four and seven days, the tubes were centrifuged and 100  $\mu$ L of the supernatant transferred in triplicate to a 96-well polystyrene flat bottom-plate (Corning, Tewksbury, USA). Strains of *Cryptococcus neoformans* and *Candida*

*parapsilosis* were used as negative and positive controls, respectively. The O.D. of the samples was obtained using a Biotek spectrophotometer, Epoch model, at wavelengths of 432 nm and 559 nm, which correspond to the absorption peaks of negative and positive samples, respectively.

**Proteinase.** For the measurement of proteinase activity, a technique used by Chen et al. (1996) with *C. neoformans* was used. The following mixture was formulated: 2% agar, 15 mM glucose, 13 mM glycine, 29.4 mM KH<sub>2</sub>PO<sub>4</sub>, 10 mM MgSO<sub>4</sub>, 3 mM thiamine, 0.1% azoalbumin (pH 4.5). For protein agar clearance, the five isolates on its yeast phase were plated through puncture on this mixture and incubated at 37°C for 21 days. After the incubation, each plate was inspected for the production of a degradation halo of azoalbumin around the colonies. When a proteolytic activity was observed, the diameter of the colony (p) and the diameter of the halo of azoalbumin degradation (z) were measured with a millimeter ruler, and the value p/z was calculated as the ratio between the two diameters.

**Melanin.** Melanin ghosts were obtained according to described by Almeida-Paes et al. (2012). In summary, to separate the 1,8-dihydroxynaphthalene (DHN)-melanin particles, each of the five isolates were incubated for 7 days in 150 mL of BHI broth at 37°C with constant shaking (150 rpm). The yeast cells were collected by centrifugation at 1,575 g (Centrifuge 5804R, Eppendorf) for 5 min and dried overnight to obtain the dry weight of the yeasts. Then, they were suspended and washed three times in PBS, pH 7.2, followed by a suspension in 1.0 M sorbitol – 0.1 M sodium citrate, pH 5.5. The same centrifugation protocol was used in between the steps. Protoplasts were generated by incubating cells at 30°C in 10 mg/mL of cell wall-lysing enzymes (from *Trichoderma harzianum*; Sigma Chemical Co.) for 1 h at room temperature (RT). Protoplasts were then collected by centrifugation, washed with PBS, and incubated in 4.0 M guanidine thiocyanate for 1 h at RT with frequent vortexing. The resulting material was washed again in PBS, collected by centrifugation, and boiled in 6.0 M hydrochloric acid for 1 h to hydrolyze cellular contaminants associated with melanin. The debris were collected by centrifugation and washed exhaustively with PBS. After the final centrifugation, the pellet was dried overnight and weighed, to obtain the dry weight of DHN-melanin. The proportion of DHN-melanin per isolate was then calculated by simple ratio DHN-melanin/yeasts (w/w).

### **Thermotolerance**

Yeasts of each of the five isolates were grown at 37°C in BHI broth and, after three days, 2mL of the solution of yeasts were centrifuged, suspended in PBS and serially diluted to obtain three different dilutions. Drops of 2.5 µL were inoculated on BHI Agar plates and incubated at 35, 37 or 39°C on a Type 37900 Culture Incubator. After three and six days, the plates were verified to determine the presence or absence of growth, in a qualitative manner.

### **Susceptibility to oxidants**

Fungal cells ( $1 \times 10^7$  yeasts) of each isolate were harvested after five days of growth on BHI agar slants at 37°C, washed three times with PBS, and submitted to chemically generated oxidants, as previously described (Almeida-Paes et al., 2012). In brief, nitric oxide and reactive nitrogen intermediates were generated in a solution containing 0.5 mM NaNO<sub>2</sub> and 25 mM succinic acid (pH 4.0), and oxygen-derived oxidants were generated in a solution containing 0.5 mM ferric ammonium sulfate, 61.8 µM hydrogen peroxide, and 1.0 mM epinephrine bitartrate. All chemicals were purchased from Sigma-Aldrich. After 1, 2, 3, and 4 h of incubation at 37°C with the above-mentioned oxidants, the yeasts were plated onto plate count agar (PCA) (Bio-Rad) to determine viability by CFUs counting. Aliquots of untreated cells were also plated as controls. The final viability for each isolate at a time-point was the ratio CFU count at that time / CFU count for the control, expressed in percentage.

### **Antifungal tests**

The susceptibility of the five isolates to amphotericin B, ketoconazole, itraconazole, voriconazole and terbinafine was studied using the microdilution method for filamentous fungi described by the Clinical and Laboratory Standards Institute, M38-A2 (CLSI, 2008). The antifungal agents were placed in distinct sterile 96-well round bottom plates, in serial dilution (0.016-8 µg/mL), first in dimethyl sulfoxide and then in RPMI 1640 culture medium. The control for sterility was RPMI 1640 alone, and the control for growth was the inoculum alone. For the inoculums, conidia from the five isolates were suspended in sterile saline in order to obtain a turbidity correspondent to 0.5 of the McFarland scale. The plates were incubated at 37°C, for 72 h. The reading was visual, by verifying any turbidity and comparing it at each concentration of the drugs in relation to the growth control. For amphotericin B, itraconazole and voriconazole, the minimum inhibitory concentration (MIC) endpoint

was the lowest concentration that produced complete inhibition of growth. For ketoconazole, MIC was the lowest concentration producing a 50% reduction in growth, and for terbinafine it was the lowest concentration producing at least 80% of reduction in growth.

### **Statistics tests**

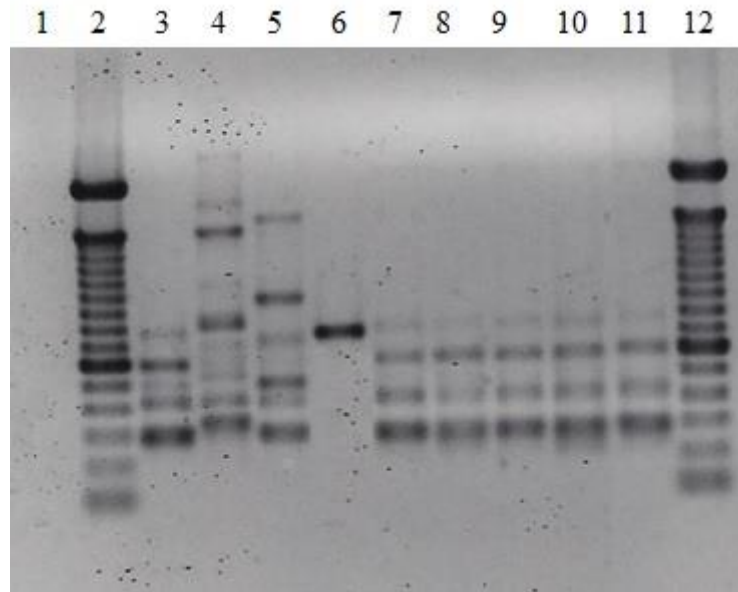
Non-parametric tests (e.g., Kruskal-Wallis test to compare the growth curves and CFUs, Kaplan-Meier estimator for the survival of *G. mellonella* and Log-rank (Mantel-Cox) test for the comparison of the survival curves) were used in the analyses to compare the five isolates and a p-value < 0.05 was considered significant. GraphPad Prism 6 for Windows, GraphPad Software, Inc., was used for the graph and for the statistics. Microsoft Excel 2010/2013 (Microsoft Corporation, Redmond, Washington, USA) was used for calculations and analyses.

## **Results**

For all the experiments, but the antifungal tests, the five isolates were kept in their yeast phase, in order to mimic the host *in vivo* conditions. The growth curves of the five isolates in BHI medium were quite similar, with no statistical difference among them.

T3B PCR fingerprinting of the five isolates showed profiles with DNA fragments ranging from 300 to 800 bp that allowed a clear identification by similarity with the profile obtained by *S. brasiliensis* control strain (**Figure 2**).

To characterize their virulence, *in vitro* assays using J774 macrophages were performed, in three steps: phagocytosis, fungal killing and macrophage viability assays. Again, no differences among the isolates were noted, and the same was seen for the reference strain of *S. brasiliensis*. The phagocytosis index after 2 h of yeasts-macrophages interaction was around 90%, but the killing capacity after 18 h was close to null, never surpassing 10%. The macrophages were viable after this full interaction (around 90% for all the conditions).

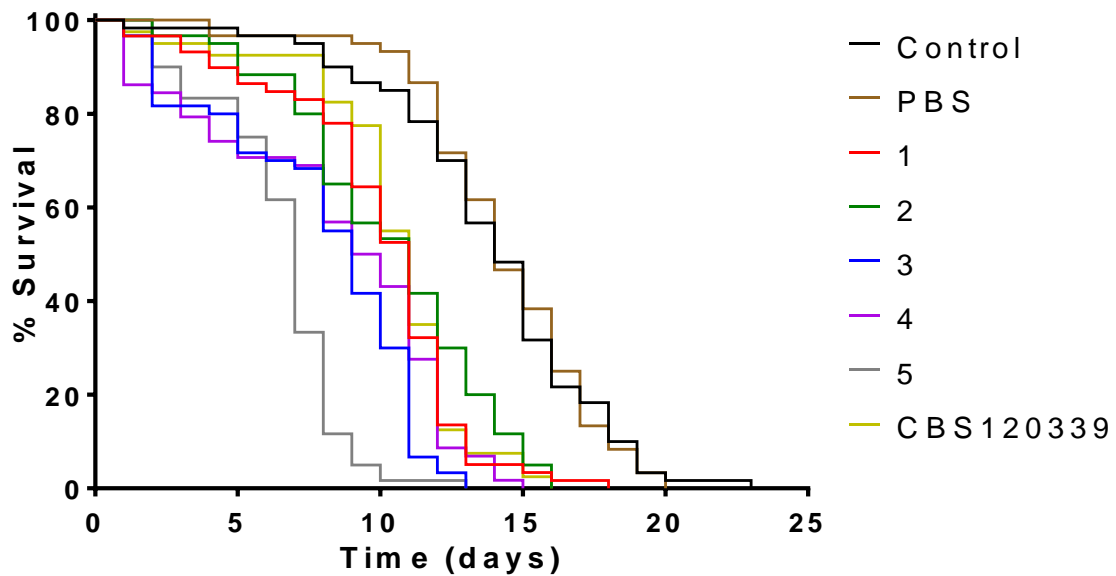


**Figure 2.** Representative T3B PCR fingerprinting profiles of the five *Sporothrix* strains. (1) Negative control. (2 and 12) Molecular marker DNA ladder, 100 bp (Invitrogen). (3) *S. brasiliensis* (CBS120339). (4) *S. mexicana* (MUM11.02). (5) *S. Schenckii* (IPEC36277). (6) *S. globosa* (IPEC27135). (7) IPEC32742. (8) IPEC33070. (9) IPEC33718. (10) IPEC33946. (11) IPEC43174.


*In vivo* assays with larvae of *Galleria mellonella* were performed. For that, each larva was inoculated with  $10^7$  yeasts. Previously, pilot experiments with  $10^4$  and  $10^6$  yeasts were run, but this amount was not enough to change the survival of the larvae, compared to the controls (data not shown). The survival curve was obtained after three experiments and the results were joined. All the isolates reduced the survival of the larvae, compared to the controls, but this reduction was higher for the larvae injected with the isolate 5, compared to any other group (median survival = 7 days;  $p < 0.0001$ ; **Figure 3**).

The isolate 4 presented the lowest number of CFUs obtained after six days of inoculation and differed from the isolates 3 ( $p = 0.0078$ ) and 5 ( $p = 0.0132$ ). The other isolates did not present differences for this variable (data not shown).

The faster darkening of individuals inoculated with yeasts compared to controls could be observed (**Figure 4**). Subjectively, a lethargic behavior of infected individuals was also noticed. Dead larvae were identified by the absence of motion, even when touch-stimulated and/or blackening of the body. The partial darkening (melanization) is usually associated with illness or aging.



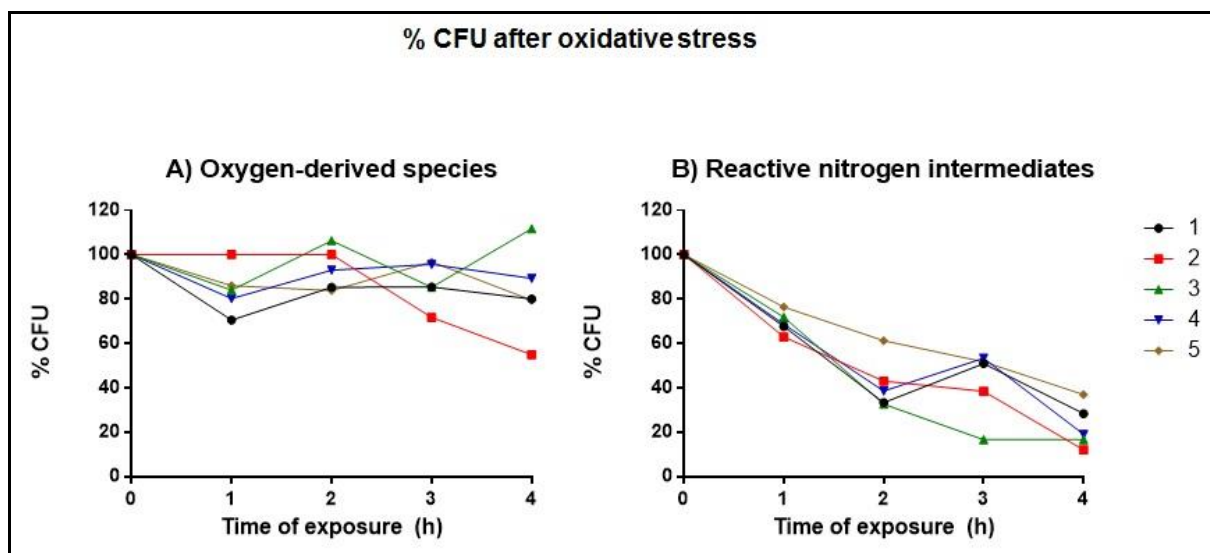
**Figure 3.** Survival curve of the larvae of *Galleria mellonella*. Lines represent the percentage of live individuals over the days. Control: larvae without any inoculum; PBS: larvae inoculated with 10 $\mu$ L sterile PBS; numeric codes: larvae inoculated with 10<sup>7</sup> yeasts of each isolate, or with the reference CBS strain of *S. brasiliensis* in 10 $\mu$ L sterile PBS. The larvae were maintained at 37°C, with daily count of the living individuals and removal of the dead ones. N = 60 larvae per group.



**Figure 4.** Photographs of two groups of larvae (PBS [left] and isolate 5 [right]), right after the inoculation (Day 0) and two days later (Day 2). The five dark brown / black larvae were dead and were removed after the count.

To determine which possible factor was related to the difference in virulence, seen *in vivo* with the larvae of *G. mellonella*, other experiments were performed. The production of urease using Christensen's urea broth at 37°C was positive for the five

isolates, after four and seven days, with no difference in the mean absorbance at 559 nm. The proteinase activity, determined by the measurement of the azoalbumin degradation halo on agar, ranged from 0.6 to 0.76, with a higher activity by the isolate 1 ( $p/z = 0.6$ ). This isolate differed significantly from the isolates 2 ( $p=0.0161$ ) and 4 ( $p=0.0005$ ). The proportion of DHN melanin for the isolates, obtained by the ratio of dry DHN melanin / dry mass of yeasts, showed no statistical differences. All the isolates grew at 35 and 37°C, and none grew at 39°C. Although the isolate 2 presented the highest inhibition of growth and had a median 55% survival after 4 h of exposure to oxygen-derived species, there were no significant differences among the five isolates for this evaluation of survival at each time point (**Figure 5A**). The exposure to reactive nitrogen intermediates promoted a higher reduction in survival of the isolates, which ranged from a minimum median 12% for the isolate 2 to a maximum median 37% for the isolate 5 after 4 h of exposure. Nevertheless, these differences in the reduction of survival were not significant (**Figure 5B**).



**Figure 5.** Percentage of viable yeasts after 4 h of exposure to different oxidative stress media. A) Exposure to oxygen-derived species. B) Exposure to reactive nitrogen intermediates. The five isolates ( $10^7$  yeasts / mL) were challenged to the media at 37°C and after each time point samples of 100  $\mu$ L were plated onto PCA for a future CFU count. Points represent medians ( $n=9$ ).

The antifungal tests were also similar for all the isolates, and showed a lower MIC for terbinafine (0.06  $\mu$ g/mL), intermediate for itraconazole (1.0  $\mu$ g/mL), and ketoconazole and amphotericin (2.0  $\mu$ g/mL), and a higher MIC for voriconazole ( $\geq 8 \mu$ g/mL).

## Discussion

The clinical aggressiveness and therapeutic difficulties in a patient with sporotrichosis for eleven years, with dissemination to skin and bones, caught our attention. Despite having comorbidities, the patient was clinically controlled, and tests performed in a search for a possible immunosuppression did not show abnormalities. The reduction of naïve T cells may be related to the constant stimulation of the lymphocytes due to the chronic infection, inducing their differentiation.

The five *Sporothrix* isolates from this patient, collected over five years and reflecting the active disease despite of treatment, point to thinking of reinfection, superinfection, or even a change in virulence over time. The molecular profile of *S. brasiliensis* was confirmed in all isolates, which was somewhat surprising, given that there was no epidemiological link with cats' transmission and the patient lived in a municipality outside of the "belt" of sporotrichosis in Rio de Janeiro (Silva et al., 2012). These isolates did not show differences in the pattern of bands in the fingerprinting PCR, suggesting that they do not present significant genetic variances.

Virulence assays demonstrated a high virulence of *S. brasiliensis*, compared to other species of the *S. schenckii* complex (Arrillaga-Moncrieff et al., 2009). *In vitro* assays with macrophages did not show difference in virulence among the five isolates of our study: the macrophages could phagocytose the yeasts but were not able to kill them, nor died, as happened for the control strain. However, *in vivo* assays using larvae of *G. mellonella* pointed to a consistent higher mortality among larvae inoculated with the isolate 5, which was obtained after 5 years of follow-up at IPEC (a total of 11 years of disease), an evidence for a greater virulence of this isolate. This virulence experimental model has been successfully used in other fungi and bacteria, and now in *S. brasiliensis*. It has advantages such as low cost, ease of storage and handling, in addition to favorable ethical aspects (Mylonakis, 2008; García-Rodas et al., 2011; Thomaz et al., 2013).

Assays to measure the urease and DHN melanin production, and to assess thermotolerance showed no difference among the isolates. Proteinase activity was not uniform, but the higher activity measured for the isolate 1 was not consistent in comparison with all the other isolates and it does not seem to have implied in an increase in virulence of this isolate, as proved by the virulence assays. The antifungal susceptibility was the same for all the isolates, with the drugs tested. Comparing the MICs found here with the known susceptibility profile for *S. brasiliensis* (Gutierrez-



Galhardo et al., 2008; Marimon et al., 2008), only terbinafine showed a good *in vitro* efficacy against the isolates, while the azoles and amphotericin B had poor and intermediate efficacies, respectively. We highlight the great sensitivity to terbinafine in all isolates, the drug used for the treatment of this patient over the years.

Finally, tests to assess the susceptibility to oxidative stress revealed that the isolates were more susceptible to reactive nitrogen intermediates than to oxygen-derived species and that the same isolate that promoted a faster death of the larvae (isolate 5) showed a trend to resist longer in the presence of reactive nitrogen intermediates, although not statistically proven. The advantage of resisting adverse conditions similar to those found within lysosomes in macrophages could explain the higher virulence of this isolate; however, this cannot be concluded by our results.

We conclude that this patient has had the same fungus over all these years. Despite its sensitivity to terbinafine *in vitro*, it may have acquired means to remain in the host by evading his immune system in order to maintain the infection. It is possible that other factors associated with this change in the parasite-host relationship, not studied here, have also contributed to this increased virulence. We consider this study, *in vivo* and *in vitro*, singular, since it demonstrates the evolution of virulence of *Sporothrix brasiliensis* in a host with chronic and disseminated sporotrichosis.

## **Acknowledgements**

Thanks to David Alejandro Sanchez for the help with the virulence experiments and to Dr. Otávio Espíndola for the flow cytometry analysis.

Financial support: FAPERJ/Rio de Janeiro, Brazil (grant proc. E-26/110.619/2012) and PAPES VI – CNPq/Fiocruz (grant proc. 407693/2012-2).

DFSF received financial support from CNPq, CAPES and Fogarty International Center.

RMZ-O was supported in part by CNPq 350338/2000-0 and FAPERJ E-26/103.157/2011.

## References

- Almeida-Paes R, Frases S, Monteiro PCF, Gutierrez-Galhardo MC, Zancopé-Oliveira RM, et al. (2009) Growth conditions influence melanization of Brazilian clinical *Sporothrix schenckii* isolates. *Microbes Infect* 11: 554-562. doi: 10.1016/j.micinf.2009.03.002
- Almeida-Paes R, Frases S, Araújo Gde S, de Oliveira MM, Gerfen GJ, et al. (2012) Biosynthesis and functions of a melanoid pigment produced by species of the *Sporothrix* complex in the presence of L-tyrosine. *Appl Environ Microbiol* 78(24): 8623-8630. doi: 10.1128/AEM.02414-12
- Arrillaga-Moncrieff I, Capilla J, Mayayo E, Marimon R, Marine´ M, et al. (2009) Different virulence levels of the species of *Sporothrix* in a murine model. *Clin Microbiol Infect* 15: 651–655. doi: 10.1111/j.1469-0691.2009.02824.x
- Barros MB, de Almeida-Paes R, Schubach AO (2011) *Sporothrix schenckii* and Sporotrichosis. *Clin Microbiol Rev* 24(4): 633–654. doi: 10.1128/CMR.00007-11
- Chen LC, Blank ES, Casadevall A (1996) Extracellular proteinase activity of *Cryptococcus neoformans*. *Clin Diagn Lab Immunol* 3: 570-574.
- Christensen WB (1946) Urea decomposition as a means of differentiating *Proteus* and paracolon cultures from each other and from *Salmonella* and *Shigella*. *J Bacteriol* 52: 461-466.
- CLSI (2008) Reference method for broth dilution antifungal susceptibility testing of filamentous fungi; approved standard – second edition. CLSI document M38-A2. Wayne, PA: Clinical and Laboratory Standards Institute.
- Fernandes GF, dos Santos PO, Rodrigues AM, Sasaki AA, Burger E, et al. (2013) Characterization of virulence profile, protein secretion and immunogenicity of different *Sporothrix schenckii sensu stricto* isolates compared with *S. globosa* and *S. brasiliensis* species. *Virulence* 4(3): 241-249. doi: 10.4161/viru.23112
- Freitas DFS, Valle ACF, Almeida-Paes R, Bastos FI, Galhardo MCG (2010) Zoonotic sporotrichosis in Rio de Janeiro, Brazil: a protracted epidemic yet to be curbed. *Clin Infect Dis* 50: 453. doi: 10.1086/649891
- Freitas DF, de Siqueira Hoagland B, do Valle AC, Fraga BB, de Barros MB, et al. (2012) Sporotrichosis in HIV-Infected patients: report of 21 cases of endemic sporotrichosis in Rio de Janeiro, Brazil. *Med Mycol* 50: 170–178. doi: 10.3109/13693786.2011.596288
- García-Rodas R, Casadevall A, Rodríguez-Tudela JL, Cuenca-Estrella M, Zaragoza O (2011) *Cryptococcus neoformans* capsular enlargement and cellular gigantism during *Galleria mellonella* infection. *PLoS ONE* 6(9): e24485. doi:10.1371/journal.pone.0024485
- Gutierrez-Galhardo MC, Oliveira RMZ, Valle ACF, Paes RA, Silvatavares PM, et al. (2008) Molecular epidemiology and antifungal susceptibility patterns of *Sporothrix schenckii* isolates from a cat-transmitted epidemic of sporotrichosis in Rio de Janeiro, Brazil. *Medical Mycology* 46: 141-151. doi: 10.1080/13693780701742399
- Kane J, Fischer JB (1971) The differentiation of *T. rubrum* and *T. mentagrophytes* by use of Christensen’s urea broth. *Can J Microbiol* 17: 911-913.

- Liu TT, Zhang K, Zhou X (2014) Molecular identification of *Sporothrix* clinical isolates in China. *J Zhejiang Univ Sci B* 15(1): 100-108. doi: 10.1631/jzus.B1300136
- Madrid H, Cano J, Gene J, Bonifaz A, Toriello C, et al. (2009) *Sporothrix globosa*, a pathogenic fungus with widespread geographical distribution. *Rev Iberoam Micol* 26: 218–222. doi: 10.1016/j.riam.2009.02.005
- Marimon R, Cano J, Gené J, Sutton DA, Kawasaki M, et al. (2007) *Sporothrix brasiliensis*, *S. globosa*, and *S. mexicana*, three new *Sporothrix* species of clinical interest. *J Clin Microbiol* 45: 3198-3206. doi: 10.1128/JCM.00808-07
- Marimon R, Serena C, Gené J, Cano J, Guarro J (2008) *In vitro* antifungal susceptibilities of five species of *Sporothrix*. *Antimicrob Agents Chemother* 52: 732-734. doi: 10.1128/AAC.01012-07
- Medina A, Lambert RJ, Magan N (2012) Rapid throughput analysis of filamentous fungal growth using turbidimetric measurements with the Bioscreen C: a tool for screening antifungal compounds. *Fungal Biol* 116(1): 161-169. doi: 10.1016/j.funbio.2011.11.001
- Mylonakis E (2008) *Galleria mellonella* and the Study of Fungal Pathogenesis: Making the Case for Another Genetically Tractable Model Host. *Mycopathologia* 165: 1–3.
- Nicola AM and Casadevall A (2012) *In Vitro* Measurement of Phagocytosis and Killing of *Cryptococcus neoformans* by Macrophages. *Methods Mol Biol* 844: 189-197. doi: 10.1007/978-1-61779-527-5\_14
- Oliveira MM, Almeida-Paes R, Muniz MM, Gutierrez-Galhardo MC, Zancope-Oliveira RM (2011) Phenotypic and molecular identification of *Sporothrix* isolates from an epidemic area of sporotrichosis in Brazil. *Mycopathologia* 172: 257–267. doi: 10.1007/s11046-011-9437-3
- Oliveira MME, Sampaio P, Almeida-Paes R, Pais C, Gutierrez-Galhardo MC, et al. (2012) Rapid Identification of *Sporothrix* Species by T3B Fingerprinting. *J Clin Microbiol* 50: 2159-2162. doi: 10.1128/JCM.00450-12
- Rodrigues AM, de Hoog S, de Camargo ZP (2013a) Emergence of pathogenicity in the *Sporothrix schenckii* complex. *Med Mycol* 51: 405–412. doi:10.3109/13693786.2012.719648
- Rodrigues AM, Teixeira MdM, de Hoog GS, Schubach TMP, Pereira SA, et al. (2013b) Phylogenetic Analysis Reveals a High Prevalence of *Sporothrix brasiliensis* in Feline Sporotrichosis Outbreaks. *PLoS Negl Trop Dis* 7(6): e2281. doi:10.1371/journal.pntd.0002281
- Silva MB, Costa MM, Torres CC, Galhardo MC, Valle AC, et al. (2012) Urban sporotrichosis: a neglected epidemic in Rio de Janeiro, Brazil. *Cad Saude Publica* 28: 1867-1880.
- Thomaz L, García-Rodas R, Guimarães AJ, Taborda CP, Zaragoza O, et al. (2013) *Galleria mellonella* as a model host to study *Paracoccidioides lutzii* and *Histoplasma capsulatum*. *Virulence* 4: 139–146. doi: 10.4161/viru.23047
- Yu X, Wan Z, Zhang Z, Li F, Li R, et al. (2013) Phenotypic and molecular identification of *Sporothrix* isolates of clinical origin in Northeast China. *Mycopathologia* 176: 67–74. doi: 10.1007/s11046-013-9668-6

## 7. DISCUSSÃO

A esporotricose de transmissão zoonótica é hiperendêmica no Rio de Janeiro. A doença ainda é negligenciada e carece de medidas robustas de saúde pública para seu controle. Geograficamente podemos observar um cinturão da esporotricose em áreas mais carentes, que se mesclam a uma urbanização recente ainda com vegetação, possibilitando a perpetuação da doença (Silva et al., 2012). Desde o início da epidemia, o IPEC foi pioneiro no reconhecimento do aumento do número de casos e tratamento destes pacientes. Isso nos possibilitou a observação da dinâmica da infecção culminando em uma grande casuística com características peculiares ao longo destes anos.

Barros et al. (2004) publicaram 178 casos humanos de esporotricose diagnosticados no IPEC entre 1998-2001, em seguida Martins (2006) contabilizou 572 casos entre 2002-2004 em sua dissertação de mestrado. Em 2010, como resultado de meus estudos de mestrado, publicamos 804 novos casos diagnosticados entre 2005-2008 (Freitas et al., 2010). Nos três períodos, formas clínicas clássicas (fixa e linfocutânea) permaneceram preponderantes, entretanto casos com disseminação cutânea e extracutânea foram mais frequentes do que o classicamente relatado em casuísticas sem transmissão zoonótica (Barros et al., 2004, 2011a; Freitas et al., 2010). Subgrupos de pacientes chamaram atenção, como gestantes, crianças, portadores de reações de hipersensibilidade e coinfectados por HIV. Da mesma forma uma proposta de mudança taxonômica de *Sporothrix* spp. (Marimon et al., 2007), com novas espécies de importância clínica, apontando *S. brasiliensis* como responsável pelos casos epidêmicos no Rio de Janeiro (Oliveira et al., 2011), nos levaram a realizar os estudos aqui apresentados com o intuito de descrever e aprofundar o conhecimento da esporotricose.

Por isso, neste trabalho foram apresentadas amostras envolvendo diferentes períodos. Casuística histórica, desde o início da epidemia até o fechamento do trabalho em questão, como nos dois estudos com pacientes com esporotricose coinfectados por HIV. Períodos selecionados em função de uma padronização de dados disponíveis, para responder o objetivo do estudo. Para relato de casos, motivados pela ocorrência singular destes, menores amostragens foram adotadas, como nos casos de Síndrome de Sweet, dacriocistite e da descrição do grupo de gestantes com esporotricose. Por fim, nos casos envolvendo análise genotípica de

isolados clínicos de pacientes, amostras representativas por conveniência foram utilizadas e motivaram um estudo laboratorial mais detalhado.

Relatamos três casos de pacientes com esporotricose que desenvolveram Síndrome de Sweet no curso da infecção fúngica (Capítulo 1). Esta síndrome é uma vasculite neutrofílica decorrente de hipersensibilidade e se associa, em geral, a infecções e outras doenças subjacentes (von den Driesch, 1994; Cohen, 2007), entretanto associação com esporotricose ainda não havia sido relatada na literatura. Neste relato de três casos, dois em mulheres de meia-idade e um, em idosa, há uma semelhança com o perfil de pacientes afetados por esta vasculite neutrofílica.

Manifestações de hipersensibilidade, como eritema nodoso e eritema multiforme, já haviam sido descritas pela primeira vez relacionadas à esporotricose mais precocemente nesta epidemia (Gutierrez-Galhardo et al., 2002, 2005). Barros et al. (2004) relataram um percentual elevado de queixas articulares associadas (29,8%) nos pacientes com esporotricose, característica reforçada em 2010 em uma descrição de um caso de esporotricose com artrite reativa associada (Orofino-Costa et al., 2010). Estas manifestações têm em comum a hipersensibilidade, de causa multifatorial, com a presença de citocinas inflamatórias e fisiopatogenia pouco conhecida. Acreditamos que a forma de transmissão zoonótica pelo gato no intra ou peridomicílio favoreça à exposição diária ao fungo, com cargas parasitárias elevadas, quadros de inoculações múltiplas (arranhaduras, mordeduras) e desencadeamento de hipersensibilidade no hospedeiro suscetível. O eritema nodoso observado em determinadas doenças como a coccidioidomicose e a sarcoidose parece estar associado a um efeito protetor (Gutierrez-Galhardo et al., 2002). Barros et al. (2011b) avaliaram o tratamento da esporotricose cutânea com itraconazol em 645 pacientes desta epidemia, sendo 87 com eritema nodoso ou multiforme. Eles observaram que estas manifestações de hipersensibilidade estiveram associadas a uma evolução mais rápida na cicatrização das lesões, comparado aos pacientes sem estas manifestações. Geralmente quadros de hipersensibilidade, como os apresentados nestes três casos, e nos demais descritos anteriormente, caracterizam-se por quadro com pequenas lesões de esporotricose localizada, entretanto, com intensa reação inflamatória em outros sítios. Como exposto no Capítulo 3 desta tese, todos os 10 pacientes que tiveram manifestações de hipersensibilidade, em 50 casos avaliados, tinham infecção pela espécie *S. brasiliensis* (artigo da tese). Os isolados obtidos nos casos de síndrome de Sweet serão estudados quanto ao genótipo. Acreditamos que a forma de transmissão

zoonótica, a nova espécie (*S. brasiliensis*), assim como o hospedeiro suscetível, contribuam para estes quadros inflamatórios.

Casos de esporotricose ocular, em geral manifestos por conjuntivite granulomatosa, são descritos em várias casuísticas e não são uma particularidade desta epidemia. Barros et al. (2008), analisando o perfil clínico da esporotricose em 81 crianças abaixo de 15 anos de idade, atendidas entre 1998-2004, observaram 1 caso de dacriocistite. Esta observação nos alertou para a ocorrência desta apresentação incomum. Apoiados em uma constatação do surgimento de novos casos, conjunta com o Laboratório de Doenças Infecciosas em Oftalmologia, fizemos uma análise de uma amostragem de 2.146 pacientes com esporotricose atendidos no IPEC entre julho de 2008 e julho de 2010. Daí resultou o relato de quatro pacientes (1,2% da amostra) com dacriocistite aguda em decorrência de esporotricose, mais uma manifestação clínica até então inédita. Salientamos o grau de morbidade desta forma de apresentação, já que uma paciente desenvolveu fístula como complicação e três evoluíram com dacriocistite crônica, necessitando de reparação cirúrgica em todos os casos. Sugerimos também que as crianças são mais acometidas (três em quatro casos no período analisado). A presença de sinais respiratórios é frequente em gatos com esporotricose, principalmente espirros, os quais geralmente estão associados a lesões na região nasal e na mucosa nasal (Schubach et al., 2004). É possível que a pele fina e delicada da face das crianças favoreça o surgimento de lesões, mesmo na ausência de trauma, ou ainda que estas não percebam nem relatem pequenos traumas enquanto brincam com os animais (da Rosa et al., 2005). Formas extracutâneas da esporotricose, tais como as doenças que afetam os olhos e os anexos, podem levar a complicações graves e crônicas, lembrando que a esporotricose nem sempre tem uma evolução benigna. Os médicos responsáveis pela assistência em áreas de alta endemicidade devem estar cientes das diversas manifestações de esporotricose. Os isolados destes pacientes não foram genotipados, mas as evidências da análise molecular de outros vários isolados desta epidemia (Oliveira et al., 2011), sugerem que *S. brasiliensis* também esteja relacionado ao surgimento desta rara forma clínica.

Dentre alguns grupos de pacientes envolvidos nesta epidemia, as gestantes mereceram especial atenção, uma vez que os fármacos de eleição no tratamento da esporotricose, itraconazol e terbinafina, são contraindicados na gravidez (Barros et al., 2011a). Como mostrado no terceiro artigo do capítulo 1, a terapia com calor local foi bem sucedida para resolução favorável de 8 dos 12 casos atendidos entre 2005 e

2010, e apenas 2 pacientes necessitaram de terapêutica complementar com itraconazol após o parto. Apesar da preocupação que este grupo mereceu, não houve um pior prognóstico da esporotricose, diferente do que é observado em algumas outras infecções (Bercovitch et al., 2011). É provável que o número de gestantes acometidas continue a crescer juntamente do aumento do número geral de casos de esporotricose, dado que a epidemia permanece instalada e sem controle. Em 2011 houve um relato de cinco gestantes com esporotricose, também durante esta mesma epidemia zoonótica, em outra instituição assistencial. Todas as pacientes foram curadas, sendo duas com terapia com calor local, duas com anfotericina B intravenosa em baixa dose acumulada (<500 mg) e uma após uso de terbinafina, sem saber da gestação. Não houve alterações fetais atribuíveis à esporotricose ou ao tratamento implementado, apesar de uma perda neonatal (Orofino-Costa et al., 2011). A dupla contracepção vem sendo recomendada diariamente no atendimento às mulheres com esporotricose em idade fértil, pois a maioria utiliza contraceptivos orais e o itraconazol pode diminuir níveis séricos destes. Ainda assim, existem pacientes que engravidam no decorrer do tratamento (comunicação pessoal). Tais intercorrências aumentam nossa responsabilidade e preocupação com este grupo de pacientes, que adicionam sua vulnerabilidade a uma maior morbidade.

Desde o início da pandemia do HIV, o caráter oportunístico da esporotricose em pacientes infectados por este vírus vem sendo mencionado. Entretanto, de 1987 até 2009, somente 34 casos foram relatados na literatura. O grupo de coinfectados pelo HIV também se destacou na nossa casuística. No estudo com 21 pacientes atendidos entre 1999-2009, caracterizamos que estes pacientes também foram oriundos da região metropolitana hiperendêmica de esporotricose, porém homens foram maioria, contrapondo-se ao predomínio de mulheres como classicamente descrito para esta epidemia (Barros et al., 2004; Freitas et al., 2010). Constatamos que a forma clínica de esporotricose por eles desenvolvida se relacionou com o estado imunológico, com predomínio de formas localizadas em pacientes com linfócitos T CD4<sup>+</sup> ≥ 200 células/μL (9/11), mostrando um comportamento imunológico semelhante aos pacientes sem esta coinfeção, enquanto as formas disseminadas ou cutâneas disseminadas foram totalidade naqueles com linfócitos T CD4<sup>+</sup> < 200 células/μL. Esporotricose disseminada foi a manifestação inicial da infecção pelo HIV em sete pacientes, que desconheciam a infecção viral até então. Formas linfocutâneas e disseminadas ocorreram em sete pacientes cada, enquanto

cutâneas disseminadas em cinco. A pele foi o sítio de entrada, exceto em um paciente, e as lesões disseminadas se caracterizaram pelo acometimento multissistêmico. As lesões em pacientes com aids se caracterizaram como múltiplas, extensas, nodulares e ulceradas. As mucosas foram o principal sítio extracutâneo, com seis casos, sendo a nasal a mais frequente. A perfuração septal foi descrita pela primeira vez na esporotricose. Este aspecto de invasão e destruição fala a favor de maior virulência do agente, associado à imunossupressão. Ressaltamos o neurotropismo de *Sporothrix* spp., provocando meningoencefalite subaguda, sendo que o SNC teve frequência de acometimento igual ao sistema osteoarticular (dois casos cada), que é descrito como o principal sítio extracutâneo na esporotricose. Por isso, o estudo do líquido cefalorraquidiano se impõe como rotina em pacientes com esporotricose e aids. Em investigação diagnóstica para a esporotricose disseminada em outros espécimes clínicos de sítios aparentemente assintomáticos, como escarro e urina (um caso cada), *Sporothrix* foi isolado. A biópsia de pele realizada em dez pacientes permitiu observar a presença de granulomas na histopatologia, apesar da imunodeficiência avançada, e a visualização maciça de *Sporothrix*, aspecto pouco frequente na esporotricose, mas observado na quase totalidade neste estudo. Dezesete pacientes foram curados e dois foram a óbito. Quatro pacientes apresentaram a esporotricose como manifestação de síndrome de recuperação imune. Concluimos que a esporotricose pode assumir um papel de doença oportunística em pacientes com infecção pelo HIV. A abordagem adequada, incluindo a investigação diagnóstica de doença sistêmica em pacientes imunossuprimidos (linfócitos T CD4<sup>+</sup> < 200 células/μL), o tratamento antifúngico e o uso da terapia antirretroviral, são fundamentais para a boa evolução da esporotricose associada à infecção pelo HIV.

Numa continuidade da análise voltada a este grupo de pacientes coinfectados por HIV, objetivando um conhecimento mais aprofundado de seu perfil, foi realizado um segundo estudo, desta vez, englobando uma amostra histórica do IPEC desde 1987, ano do primeiro registro de esporotricose, a março de 2013. Foram 48 casos de pacientes com esporotricose e coinfecção por HIV (grupo 1) e 3.570 pacientes com esporotricose (grupo 2). O primeiro paciente com esporotricose coinfectado por HIV foi diagnosticado em 1999 e o número de casos desta coinfecção também sofreu elevações ao longo dos anos, com padrão semelhante ao assumido pela totalidade dos casos de esporotricose. Nos últimos anos, aproximadamente a partir de 2006, um incremento maior ocorreu, o que pode ser explicado pela atual



aceleração da propagação da esporotricose, aumentando a possibilidade de atingir grupos vulneráveis. Conjuntamente, parece haver maior suspeição dos clínicos e testagem para a infecção pelo HIV, pela possibilidade de coinfeção. Acreditamos que tais condições médicas e sociais diferentes tendem a sobrepor-se e, por vezes, reforçam-se mutuamente (como acontece com o abuso de substâncias e algumas formas de violência), afetando desproporcionalmente as populações marginalizadas e carentes. Ratificando o estudo anterior, a maioria do grupo 1 foi composta de homens (68,8%) e não brancos (70,8%;  $p < 0,0001$ ). O predomínio de pacientes não brancos neste grupo aponta para condições sociais e econômicas ainda mais desfavoráveis do que as já observadas nos casos de esporotricose, e parece refletir uma histórica disparidade no acesso aos serviços de saúde no Brasil (Travassos et al., 2011). Em ambos os grupos predominou a baixa escolaridade. As doenças negligenciadas são frequentemente encontradas em segmentos pobres e marginalizados da população, com acesso restrito à educação formal (Schneider et al., 2011).

Conforme descrito anteriormente, o HIV modifica claramente a história natural da esporotricose e está associado a um amplo espectro desta micose, com uma incidência muito maior de casos disseminados graves, número de hospitalizações e mortes. Além disso, devemos ter em mente que nem sempre a esporotricose é uma doença benigna, e pode levar à hospitalização e à morte, mesmo em pacientes sem imunossupressão. Infecções bacterianas secundárias e reações de hipersensibilidade foram causas relevantes de hospitalização entre os pacientes do grupo 2. Neste grupo, a presença de comorbidades foi importante. *S. brasiliensis*, o principal agente etiológico desta epidemia em específico, parece ser mais virulento do que outras espécies do complexo *S. schenckii* (Arrillaga-Moncrieff et al., 2009) e pode causar reações de hipersensibilidade pronunciadas. É notável que 47,9% dos pacientes tenham sido diagnosticados com as duas infecções simultaneamente, devido à presença de esporotricose oportunística ou outra condição relacionada ao HIV. Fica evidente que este subgrupo de pacientes não teve acesso adequado ao diagnóstico precoce do HIV e entrou tardiamente no programa de tratamento, o que parece ter aumentado a chance de adquirir outras infecções e o risco de morrer em consequência da aids no primeiro ano de diagnóstico (Grangeiro et al., 2011). Diferente da esporotricose, que tem se comportado como uma crescente ameaça nos últimos anos, a terapia antirretroviral combinada tem sido associada a uma estabilização do número de micoses oportunísticas clássicas, como histoplasmoses e

criptococose (Ramos-e-Silva et al., 2012), conforme documentado pelos nossos dados. A incidência de esporotricose entre os pacientes com HIV tem aumentado de forma contínua, e no final do período em estudo assumiu números semelhantes aos de histoplasmose e criptococose. Os danos e riscos associados à propagação da esporotricose em uma população marginalizada, afetada por diversas condições médicas e sociais, são motivos de preocupação. A associação de esporotricose e HIV promove casos mais graves da micose, às vezes fatais. Devem ser tomadas medidas de saúde pública, a fim de combater os riscos, especialmente porque ambas as infecções são evitáveis.

Como já enfatizado, peculiaridades desta epidemia têm sido atribuídas à espécie de *Sporothrix* envolvida. Estudos com isolados do início da epidemia, obtidos de gatos domésticos e de humanos apontavam para um perfil genético próprio e diferente dos perfis conhecidos para *S. schenckii* até então (Gutierrez-Galhardo et al., 2008; Reis et al., 2009). Concomitante, de posse de amostras oriundas de casos da epidemia zoonótica e num estudo comparativo com isolados de várias partes do mundo, Marimon et al. (2007) chegaram à mesma conclusão e propuseram a criação de um complexo *Sporothrix schenckii*, que contemplou diferentes espécies, antigas ou recém criadas, classificadas conforme distinção molecular e fenotípica. Esta nova classificação se consolidou entre os pesquisadores, porém a relevância clínica e terapêutica desta distinção ainda é uma dúvida. *S. brasiliensis* recebeu esta denominação justamente por ter sido descrita na epidemia do Rio de Janeiro. Por analogia estatística, o quantitativo de casos já contribui para a ocorrência de formas inéditas, ou para o aumento de formas incomuns. Outras variáveis, porém, contribuem para estes achados, como o quantitativo de inóculo que os gatos podem transferir a uma pessoa durante um ou vários traumas. Em busca de melhor entender a participação de *S. brasiliensis* nas formas clínicas incomuns, bem como nas condições clínicas associadas à esporotricose, como reações de hipersensibilidade, outro estudo foi feito. Por limitação na disponibilidade de isolados fúngicos armazenados, uma amostra de 50 isolados foi analisada, com o cuidado de se contemplar isolados de casos que apresentaram diferentes formas clínicas (linfocutânea = 24, fixa = 15, cutânea disseminada = 6 e disseminada = 5), manifestações de hipersensibilidade (eritema nodoso = 6 e eritema multiforme = 4), e provenientes também de área não endêmica (área endêmica = 43 e não endêmica = 7).

Verificou-se que 45 dos 50 isolados foram *S. brasiliensis* e que, entre os pacientes dos quais estes foram isolados, 40 relataram contato com gato, confirmando que esta espécie de *Sporothrix* é a principal envolvida na epidemia zoonótica do estado do Rio de Janeiro. *S. brasiliensis* foi a espécie causadora da esporotricose em 42/43 pacientes provenientes da região hiperendêmica, enquanto fora desta região, representou 3/7 dos casos. Ela foi ainda implicada em todos os dez casos estudados que desenvolveram eritema multiforme ou eritema nodoso, bem como presente em todos os pacientes que apresentaram a forma clínica disseminada e não possuíam doença supressora subjacente. Dos cinco casos analisados de doença por *S. schenckii*, apenas um desenvolveu a forma disseminada e este paciente estava coinfestado por HIV. Apesar da limitação amostral, devida a poucos casos de outras espécies, pode-se apontar para a real responsabilidade de *S. brasiliensis* na mudança observada no padrão de formas clínicas e suas condições associadas, seguidamente vistas nesta epidemia. Por outro lado, também concordando com relatos anteriores de suscetibilidade de *S. brasiliensis* aos antifúngicos (Gutierrez-Galhardo et al., 2008; Marimon et al., 2008b), os pacientes infectados por *S. brasiliensis* apresentaram boa resposta ao tratamento com itraconazol.

Nesta plêiade de casos incomuns vistos durante os anos de epidemia, a agressividade clínica e a dificuldade terapêutica em um paciente infectado há 11 anos (5 anos de acompanhamento no IPEC), e com disseminação cutânea e óssea, destacou-se. Graças à infraestrutura do IPEC e a uma eficiente colaboração laboratorial e clínica, foram analisados cinco isolados deste paciente, coletados ao longo de cinco anos e obtidos de lesões persistentes ou recidivantes, a despeito do tratamento com terbinafina. Pensando em poder se tratar de reinfecção, superinfecção ou mesmo de uma alteração na virulência ao longo do tempo, alguns testes foram feitos.

No estudo utilizando a técnica de PCR *fingerprinting* com o *primer* T3B foi confirmado que todos os isolados tinham perfil molecular condizente com *S. brasiliensis*, o que, de certa forma foi uma surpresa, dado que este paciente adoeceu sem vínculo epidemiológico com gatos e habitava um município fora do chamado “cinturão” da esporotricose no Rio de Janeiro, composto justamente pela área hiperendêmica da capital e região metropolitana do estado (Silva et al., 2012). Estes isolados não apresentaram diferenças no padrão de bandas geradas no *fingerprinting*, sugerindo que os mesmos não apresentem variação genética

significativa. Então, adotamos técnicas clássicas para avaliar a virulência destes isolados, sempre utilizando a forma de levedura (exceto nos testes com antifúngicos).

Nos ensaios *in vitro* com macrófagos não foram encontradas distinções entre os isolados, entretanto nos ensaios *in vivo*, utilizando o modelo de infecção experimental de larvas do lepidóptero *Galleria mellonella*, foi observada uma consistente maior mortalidade nas larvas inoculadas com o isolado obtido com mais tempo de doença. Este último resultado denota uma maior virulência deste isolado, mas restava entender os possíveis fatores associados a esta alteração na relação parasita-hospedeiro. Tal modelo experimental vem sendo utilizado com sucesso na determinação da virulência de fungos e bactérias e apresenta vantagens como baixo custo, facilidade de armazenamento e manuseio, além de aspectos éticos favoráveis (Mylonakis, 2008; García-Rodas et al., 2011; Thomaz et al., 2013), sendo que ainda não encontramos relatos na literatura indexada de sua utilização com *Sporothrix* spp.

Ensaio para medida da produção de urease, melanina e para avaliar termotolerância não mostraram diferença entre os isolados. A atividade proteásica não foi uniforme entre os isolados, entretanto o isolado que apresentou a maior atividade não o fez com consistência frente a todos os outros isolados, bem como não apresentou alteração em sua virulência *in vivo*, comparado aos demais isolados.

A suscetibilidade aos agentes antifúngicos testados foi semelhante para os cinco isolados. Ao se comparar as concentrações inibitórias mínimas (CIM) encontradas ao perfil de suscetibilidade conhecido de *S. brasiliensis* (Gutierrez-Galhardo et al., 2008; Marimon et al., 2008b), apenas a terbinafina apresentou boa eficácia *in vitro* contra estes isolados do estudo, enquanto os azóis e a anfotericina B apresentaram eficácia baixa e intermediária, respectivamente, com destaque para a grande sensibilidade à terbinafina, fármaco utilizado no tratamento deste paciente ao longo destes anos. Finalmente, ensaios para verificação da suscetibilidade ao estresse oxidativo revelaram que os isolados foram mais sensíveis aos intermediários reativos de nitrogênio, quando comparados às espécies reativas derivadas de oxigênio. Ainda, o mesmo isolado que levou as larvas à morte mais rapidamente mostrou uma tendência em sobreviver mais tempo quando exposto aos intermediários reativos de nitrogênio, apesar da falta de significância estatística. A vantagem de resistir a condições adversas, como as encontradas dentro dos lisossomos nos macrófagos poderia explicar a maior virulência deste isolado, ainda que esta não seja uma conclusão possível e provada com os resultados obtidos.

Concluimos que este paciente está infectado por um mesmo fungo ao longo de todos estes anos e que, apesar de sensível à terbinafina *in vitro*, este exemplar de *S. brasiliensis* adquiriu meios para manter-se no hospedeiro, evadindo de seu sistema imune e mantendo a infecção. É possível que outros fatores, não estudados aqui, também contribuam para esta maior virulência. Consideramos este estudo, *in vivo* e *in vitro*, ímpar, na medida em que demonstra a evolução da virulência de *S. brasiliensis* num hospedeiro com esporotricose disseminada e crônica.

Estes resultados, somado ao que já se sabe sobre a esporotricose e principalmente sobre a epidemia que ainda atinge a região metropolitana do Rio de Janeiro, algumas conclusões são perceptíveis: a epidemia permanece fora de controle e muitas das peculiaridades observadas nas formas de apresentação clínica podem ser atribuídas à ocorrência da espécie *S. brasiliensis* na região; a constante e crescente propagação dos casos insere a doença em segmentos da população que podem agravar ainda mais o atual panorama, com potencial maior gravidade de doença ou dificuldade de tratamento, como gestantes, pacientes com HIV e imunossupressão, e crianças, como as que desenvolveram dacriocistite com sequelas. Há uma inquestionável contribuição no âmbito da saúde pública, uma vez que se sabe que a epidemia se sustenta, num cenário em que temos 71% dos gatos envolvidos na cadeia de transmissão com destino inadequado (Freitas et al., 2010), perpetuando o ciclo da esporotricose zoonótica no Rio de Janeiro, além do impacto do alto custo das internações e do tratamento mais prolongado dos pacientes.

Em 2013, durante o 1º Encontro Internacional de *Sporothrix* e Esporotricose, foi divulgado que em São Paulo (Netto, 2013), estado de São Paulo, Rio Grande (Sanhotene et al., 2013) e Pelotas (Madrid et al., 2013) no estado do Rio Grande do Sul, os centros de controle de zoonoses estão em ação para rastrear e controlar o crescente número de casos da doença associado à transmissão zoonótica envolvendo gatos domésticos. Essas medidas foram possíveis, pois os profissionais se fiaram no que já vinha ocorrendo no Rio de Janeiro e agiram mais precocemente, quando da percepção do aumento no número de casos humanos e animais à semelhança do ocorrido no fim dos anos 90 em nosso estado. É fundamental a permanência dos estudos visando manter um entendimento da ecoepidemiologia e das características clínicas da doença, entretanto, o mais importante é que as autoridades administrativas, políticas e de saúde, de posse do conhecimento do atual panorama da epidemia se reúnam, planejem e executem medidas para findar este triste e preocupante distúrbio de saúde pública no Rio de Janeiro.

## 8. CONCLUSÕES

1. Síndrome de *Sweet* deve ser incorporada como manifestação de hipersensibilidade da esporotricose, como as outras já descritas (eritema multiforme, eritema nodoso e artrite reativa).

2. Dacriocistite aguda é uma manifestação da esporotricose que evolui com complicações (fístula e dacriocistite crônica), necessitando de reparação cirúrgica e ocorre principalmente em crianças.

3. Termoterapia local é efetiva em gestantes com formas localizadas de esporotricose.

4. A infecção pelo HIV modifica a história natural da esporotricose e está associada a um amplo espectro clínico desta micose, com uma incidência muito maior de casos disseminados graves, número de hospitalizações e mortes.

5. *Sporothrix* spp. apresenta neurotropismo, provocando quadros de meningoencefalite.

6. Pela primeira vez foi descrita a perfuração de septo nasal pela esporotricose.

7. A boa evolução da esporotricose associada à infecção pelo HIV está relacionada a uma abordagem adequada que inclui investigação diagnóstica de doença sistêmica em pacientes imunossuprimidos (linfócitos T CD4<sup>+</sup> < 200 células/ $\mu$ L), tratamento antifúngico e terapia antirretroviral.

8. Em grande parte dos pacientes com esporotricose coinfetados com HIV, as infecções foram diagnosticadas simultaneamente (48%), refletindo a esporotricose oportunística em estágio avançado da infecção pelo HIV.

9. A nova espécie do complexo *S. schenckii*, *S. brasiliensis*, está associada às manifestações de hipersensibilidade e aos quadros disseminados observados.

10. *S. brasiliensis* pode apresentar aumento da virulência *in vivo*, gerando casos crônicos de esporotricose, com complicações e sequelas.

## **9. PERSPECTIVAS**

### **9.1. DIAGNÓSTICO E CONTROLE DA ESPOROTRICOSE**

1. A esporotricose no estado do Rio de Janeiro é uma hiperendemia negligenciada, com casos graves e causa de óbito. Fazem-se prementes medidas de controle.

2. Inclusão da esporotricose disseminada como doença definidora de aids no Brasil, onde esta micose é emergente neste grupo.

3. Incorporação dos métodos de diferenciação de espécies do complexo *Sporothrix schenckii*, dado que parece haver relação destas com perfis clínicos diferentes.

4. Modelos de virulência devem ser empregados para um maior conhecimento da interação parasita-hospedeiro na esporotricose.

### **9.2. ATUAÇÃO PROFISSIONAL FRENTE À ESPOROTRICOSE**

1. Continuar o acompanhamento clínico dos pacientes com esporotricose e observar as peculiaridades desta epidemia.

2. Seguir nos estudos laboratoriais, visando entender o papel do fungo nas diferentes apresentações clínicas.

3. Participar da divulgação sobre a epidemia de esporotricose no meio científico e para a população geral, com o objetivo de compartilhar as descobertas e constatações, bem como de educar e ajudar no controle da doença.

4. Interagir com outros estudiosos da esporotricose, mantendo-me atualizado na leitura de novos dados e participando de debates e congressos científicos.

5. Sensibilizar as autoridades competentes sobre os riscos crescentes à saúde pública que a esporotricose representa, particularmente no estado do Rio de Janeiro, com o intuito de modificar a história desta epidemia.

## REFERÊNCIAS BIBLIOGRÁFICAS

- Aarestrup FM, Guerra RO, Vieira BJ, Cunha RMC. Oral manifestation of sporotrichosis in AIDS patients. *Oral Dis* 2001; 7: 134-6.
- Abi-chacra EA, Souza LOP, Cruz LP, Braga-Silva LA, Gonçalves DS, Sodr  C, et al. Phenotypical properties associated with virulence from clinical isolates belonging to the *Candida parapsilosis* complex. *FEMS Yeast Res* 2013; 13: 831–48.
- Alchorne M, Paschoalick R, Carrete C, Fernandes K, Jacinto R. Inqu rito epidemiol gico com esporotriquina em Mogi das Cruzes – SP. *An Bras Dermatol* 1990; 65(5a): 45S-8S.
- Almeida-Paes R, Pimenta MA, Monteiro PCF, Nosanchuk JD, Zancop -Oliveira RM. Immunoglobulins G, M, and A against *Sporothrix schenckii* exoantigens in patients with sporotrichosis before and during treatment with itraconazole. *Clin Vaccine Immunol* 2007a; 14: 1149-57.
- Almeida-Paes R, Pimenta MA, Pizzini CV, Monteiro PC, Peralta JM, Nosanchuk JD, et al. Use of mycelial-phase *Sporothrix schenckii* exoantigens in an enzyme-linked immunosorbent assay for diagnosis of sporotrichosis by antibody detection. *Clin Vaccine Immunol* 2007b; 14: 244-9.
- Almeida-Paes R. Fatores de virul ncia e ant genos de *Sporothrix* spp. relacionados   epidemia de esporotricose no estado do Rio de Janeiro. Rio de Janeiro. Tese [Doutorado em Biologia Celular e Molecular] - Instituto Oswaldo Cruz; 2012.
- Almeida-Paes R, Nosanchuk JD, Zancop -Oliveira RM. Fungal melanins: biosynthesis and biological functions. In: Ma XP, Sun XX, editors. *Melanin: biosynthesis, functions and health effects*. [S.l.]: Nova Science Publishers; 2012a. p. 77-108.
- Almeida-Paes R, Bail o AM, Pizzini CV, Reis RS, Soares CMA, Peralta JM, et al. Cell-free antigens from *Sporothrix brasiliensis*: antigenic diversity and application in an immunoblot assay. *Mycoses* 2012b; 55(6): 467-75.
- Al-Tawfiq JA, Wools KK. Disseminated sporotrichosis and *Sporothrix schenckii* fungemia as the initial presentation of human immunodeficiency virus infection. *Clin Infect Dis* 1998; 26: 1403-6.
- Arrillaga-Moncrieff I, Capilla J, Mayayo E, Marimon R, Marine M, Gene J, et al. Different virulence levels of the species of *Sporothrix* in a murine model. *Clin Microbiol Infect* 2009; 15: 651-5.
- Aung AK, The BM, McGrath C, Thompson PJ. Pulmonary sporotrichosis: case series and systematic analysis of literature on clinico-radiological patterns and management outcomes. *Med Mycol* 2013; 51: 534-44.



Barros MBL, Schubach TMP, Galhardo MCG, Schubach AO, Monteiro PCF, Reis RS, et al. Sporotrichosis: an emergent zoonosis in Rio de Janeiro. Mem Inst Oswaldo Cruz 2001; 96: 777-9.

Barros MBL, Schubach AO, Valle ACF, Galhardo MCG, Conceição-Silva F, Schubach TMP, et al. Cat-transmitted sporotrichosis epidemic in Rio de Janeiro, Brazil: description of a series of cases. Clin Infect Dis 2004; 38: 529-35.

Barros MBL, Costa DLMA, Schubach TMP, Valle ACF, Lorenzi NP, Teixeira JL, et al. Endemic of zoonotic sporotrichosis: profile of cases in children. Pediatr Infect Dis J 2008; 27(3): 246-50.

Barros MBL, Schubach TMP, Coll JO, Gremiao ID, Wanke B, Schubach AO. Esporotricose: a evolução e os desafios de uma epidemia. Rev Panam Salud Publica 2010; 27: 455-60.

Barros MBL, Almeida-Paes R, Schubach AO. *Sporothrix schenckii* and sporotrichosis. Clin Microbiol Rev 2011a; 24: 633-54.

Barros MBL, Schubach AO, de Vasconcellos Carvalhaes de Oliveira R, Martins EB, Teixeira JL, Wanke B. Treatment of cutaneous sporotrichosis with itraconazole--study of 645 patients. Clin Infect Dis 2011b; 52(12): e200-6.

Bercovitch RS, Catanzaro A, Schwartz BS, Pappagianis D, Watts DH, Ampel NM. Coccidioidomycosis during pregnancy: a review and recommendations for management. Clin Infect Dis 2011; 53(4): 363-8.

Bibler MR, Lubber HJ, Glueck HI, Estes SA. Disseminated sporotrichosis in a patient with HIV infection after treatment for acquired factor VIII inhibitor. JAMA 1986; 256: 3125-6.

Bolao F, Podzamczak D, Ventin M, Gudiol F. Efficacy of acute phase and maintenance therapy with itraconazole in an AIDS patient with sporotrichosis. Eur J Clin Microbiol Infect Dis 1994; 13: 609-12.

Bonifaz A, Fierro L, Saúl A, Ponce RM. Cutaneous sporotrichosis. Intermittent treatment (pulses) with itraconazole. Eur J Dermatol 2008; 18(1): 61-4.

Bunce PE, Yang L, Chun S, Zhang SX, Trinkaus MA, Matukas LM. Disseminated sporotrichosis in a patient with hairy cell leukemia treated with amphotericin B and posaconazole. Med Mycol 2012; 50: 197-201.

Carlos IZ, Sgarbi DB, Angkuster J, Alviano CS, Silva CL. Detection of cellular immunity with the soluble antigen of the fungus *Sporothrix schenckii* in the systemic form of the disease. Mycopathologia 1992; 117: 139-44.

Carlos IZ, Zini MM, Sgarbi DB, Angluster J, Alviano CS, Silva CL. Disturbances in the production of interleukin-1 and tumor necrosis factor in disseminated murine sporotrichosis. Mycopathologia 1994; 127: 189-94.

Carlos IZ, Sgarbi DB, Placeres MCP. Host organism defense by a peptide-polysaccharide extracted from the fungus *Sporothrix schenckii*. Mycopathologia 1998; 144: 9-14.

Carlos IZ, Sgarbi DB, Santos GC, Placeres MCP. *Sporothrix schenckii* lipid inhibits macrophage phagocytosis: involvement of nitric oxide and tumour necrosis factor- $\alpha$ . Scand J Immunol 2003; 57: 214-20.

Carlos IZ, Sassa MF, Sgarbi DBG, Placeres MC, Maia DC. Current research on the immune response to experimental sporotrichosis. Mycopathologia 2009; 168: 1-10.

Casadevall A. Cards of virulence and the global virulome for humans. Microbe 2006; 1: 359-64.

Casadevall A. Amoeba provide insight into the origin of virulence in pathogenic fungi. Adv Exp Med Biol 2012; 710: 1-10.

CDC. Epidemiologic notes and reports multistate outbreak of sporotrichosis in seedling handlers. MMWR 1988; 37(42): 652-3.

Chapman SW, Pappas P, Kauffmann C, Smith EB, Dietze R, Tiraboschi-Foss N, et al. Comparative evaluation of the efficacy and safety of two doses of terbinafine (500 and 1000 mg day<sup>-1</sup>) in the treatment of cutaneous or lymphocutaneous sporotrichosis. Mycoses 2004; 47: 62-8.

Cohen PR. Sweet's syndrome – a comprehensive review of an acute febrile neutrophilic dermatosis. Orphanet J Rare Dis 2007; 2: 34.

Cruz R, Vieille P, Oschilewski D. Aislamiento ambiental de *Sporothrix globosa* en relación a un caso de esporotricosis linfo-cutánea. Rev Chilena Infectol 2012; 29: 401-5.

da Rosa AC, Scroferneker ML, Vettorato R, Gervini RL, Vettorato G, Weber A. Epidemiology of sporotrichosis: a study of 304 cases in Brazil. J Am Acad Dermatol 2005; 52: 451-9.

de Beurmann L, Gougerot H, Vaucher V. Sporotichoses cutanées du chat. C R Soc Biol 1909; 66: 370-2.

de Meyer EM, de Beer ZW, Summerbell RC, Moharram AM, de Hoog GS, Vismar HF, et al. Taxonomy and phylogeny of new wood- and soil-inhabiting *Sporothrix* species in the *Ophiostoma stenoceras-Sporothrix schenckii* complex. Mycologia 2008; 100: 647-61.

Dias NM, Oliveira MME, Santos C, Zancoppe-Oliveira RM, Lima N. Sporotrichosis caused by *Sporothrix mexicana*, Portugal. Emerg Infect Dis 2011; 17: 1975-6.

Donabedian H, O'Donnell E, Olszewski C, MacArthur RD, Budd N. Disseminated cutaneous and meningeal sporotrichosis in an AIDS patient. Diagn Microbiol Infect Dis 1994; 18: 111-5.

- Donadel KW, Reinoso YD, de Oliveira JC, Azulay RD. Esporotricose: revisão. An Bras Dermatol 1993; 68(1): 45-52.
- Dong JA, Chren MM, Elewski BE. Bonsai tree: Risk factor for disseminated sporotrichosis. J Am Acad Dermatol 1995; 33: 839-40.
- Dooley DP, Bostic PS, Beckius ML. Spook house sporotrichosis: A point-source outbreak of sporotrichosis associated with hay bale props in a Halloween haunted-house. Arch Intern Med 1997; 157: 1885-7.
- Edwards C, Reuther WL 3rd, Greer DL. Disseminated osteoarticular sporotrichosis: treatment in a patient with acquired immunodeficiency syndrome. South Med J 2000; 93: 803-6.
- Feeney KT, Arthur IH, Whittle AJ, Altman SA, Speers DJ. Outbreak of sporotrichosis, Western Australia. Emerg Infect Dis 2007; 13: 1228-31.
- Fernandes GF, Lopes-Bezerra LM, Bernardes-Engemann AR, Schubach TM, Dias MA, Pereira SA, et al. Serodiagnosis of sporotrichosis infection in cats by enzyme-linked immunosorbent assay using a specific antigen, SsCBF, and crude exoantigens. Vet Microbiol 2011; 147(3-4): 445-9.
- Fernandes KS, Coelho AL, Lopes-Bezerra LM, Barja-Fidalgo C. Virulence of *Sporothrix schenckii* conidia and yeast cells, and their susceptibility to nitric oxide. Immunology 2000; 101: 563-9.
- Fernandes KS, Neto EH, Brito MM, Silva JS, Cunha FQ, Barja-Fidalgo C. Detrimental role of endogenous nitric oxide in host defence against *Sporothrix schenckii*. Immunology 2008; 123: 469-79.
- Fernández-Silva F, Capilla J, Mayayo E, Guarro J. Efficacy of posaconazole in murine experimental sporotrichosis. Antimicrob Agents Chemother 2012; 56(5): 2273-7.
- Ferreira CP, Galhardo MC, Valle AC. Cryosurgery as adjuvant therapy in cutaneous sporotrichosis. Braz J Infect Dis 2011; 15(2): 181-3.
- Figueiredo CC, Lima OC, Carvalho L, Lopes-Bezerra LM, Morandi V. The *in vitro* interaction of *Sporothrix schenckii* with human endothelial cells is modulated by cytokines and involves endothelial surface molecules. Microb Path 2004; 36: 177-88.
- Francesconi G, Valle ACF, Passos SR, Reis RS, Galhardo MCG. Terbinafine (250 mg/day): an effective and safe treatment of cutaneous sporotrichosis. J Eur Acad Dermatol Venereol 2009; 23: 1273-6.
- Francesconi G, Valle ACF, Passos SRL, Barros MBL, Almeida-Paes R, Curi AL, et al. Comparative study of 250 mg/day terbinafine and 100 mg/day itraconazole for the treatment of cutaneous sporotrichosis. Mycopathologia 2011; 171: 349-54.
- Freitas DC, de Migliano MF, Zani Neto L. Esporotricose: Observação de caso espontâneo em gato doméstico (*F. catus*). Rev Fac Med Vet S Paulo 1956; 5: 601-4.

Freitas, DFS. Dez anos de epidemia de esporotricose no estado do Rio de Janeiro: estudo clínico-epidemiológico e terapêutico dos casos atendidos no Instituto de Pesquisa Clínica Evandro Chagas entre 2005-2008. Rio de Janeiro. Dissertação [Mestrado em Pesquisa Clínica em Doenças Infecciosas] - Instituto de Pesquisa Clínica Evandro Chagas; 2009.

Freitas DFS, Valle ACF, Almeida-Paes R, Bastos FI, Galhardo MCG. Zoonotic sporotrichosis in Rio de Janeiro, Brazil: a protracted epidemic yet to be curbed. *Clin Infect Dis* 2010; 50: 453.

García-Rodas R, Casadevall A, Rodríguez-Tudela JL, Cuenca-Estrella M, Zaragoza O. *Cryptococcus neoformans* capsular enlargement and cellular gigantism during *Galleria mellonella* infection. *PLoS ONE* 2011; 6(9): e24485.

Garrison RG, Boyd KS, Mariat F. Ultrastructural studies of the mycelium-to yeast transformation of *Sporothrix schenckii*. *J Bacteriol* 1975; 124: 959-68.

Ghosh A, Maity PK, Hemashettar BM, Sharma VK, Chakrabarti A. Physiological characters of *Sporothrix schenckii* isolates. *Mycoses* 2002; 45: 449-54.

Gilaberte Y, Aspiroz C, Alejandre MC, Andres-Ciriano E, Fortuño B, Charlez L, et al. Cutaneous sporotrichosis treated with photodynamic therapy: an *in vitro* and *in vivo* study. *Photomed Laser Surg* 2014; 32(1): 54-7.

Gomez BL, Nosanchuk JD. Melanin and fungi. *Curr Opin Infect Dis* 2003; 16: 91-6.

Gori S, Lupetti A, Moscato G, Parenti M, Lofaro A. Pulmonary sporotrichosis with hyphae in a human immunodeficiency virus-infected patient. A case report. *Acta Cytol* 1997; 41: 519-21.

Grangeiro A, Escuder MM, Menezes PR, Alencar R, Ayres de Castilho E. Late Entry into HIV Care: Estimated Impact on AIDS Mortality Rates in Brazil, 2003–2006. *PLoS ONE* 2011; 6(1): e14585.

Guarro J, Gené J, Stchigel AM. Developments in fungal taxonomy. *Clin Microbiol Rev* 1999; 12: 454-500.

Gutierrez-Galhardo MC, Schubach AO, Barros MBL, Blanco TCM, Cuzzi-Maya T, Schubach TMP, et al. Erythema nodosum associated with sporotrichosis. *Int J Dermatol* 2002; 41: 114-6.

Gutierrez-Galhardo MC, Barros MBL, Schubach AO, Cuzzi-Maya T, Schubach TMP, Lazéra MS, et al. Erythema multiforme associated with sporotrichosis. *J Eur Acad Dermatol Venereol* 2005; 19: 507-9.

Gutierrez-Galhardo MC, Oliveira RMZ, Valle ACF, Paes RA, Silvatavares PM, Monzon A, et al. Molecular epidemiology and antifungal susceptibility patterns of *Sporothrix schenckii* isolates from a cat-transmitted epidemic of sporotrichosis in Rio de Janeiro, Brazil. *Medical Mycology* 2008; 46: 141-51.

- Gutierrez-Galhardo MC, Silva MT, Lima MA, Nunes EP, Schettini LE, de Freitas RF, et al. *Sporothrix schenckii* meningitis in AIDS during immune reconstitution syndrome. J Neurol Neurosurg Psychiatry 2010; 81(6): 696-9.
- Hamilton AJ, Gomez BL. Melanins in fungal pathogens. J Med Microbiol 2002; 51: 189-91.
- Heller HM, Fuhrer J. Disseminated sporotrichosis in patients with AIDS: case report and review of the literature. AIDS 1991; 5: 1243-6.
- Helm MAF, Berman C. The clinical, therapeutic and epidemiological features of the sporotrichosis infection on the mines. In: Proceedings of the Transvaal Mine Medical Officers' Association. Sporotrichosis Infection on Mines of the Witwatersrand. Johannesburg: The Transvaal Chamber of Mines; 1947. p. 59-74.
- Hogan LH, Klein BS, Levitz SM. Virulence factors of medically important fungi. Clin Microbiol Rev 1996; 9: 469-88.
- Howard DH. Dimorphism in *Sporotrichum schenckii*. J Bacteriol 1961; 81: 464-9.
- Hu S, Chung WH, Hung SI, Ho HC, Wang ZW, Chen CH, et al. Detection of *Sporothrix schenckii* in clinical samples by a nested PCR assay. J Clin Microbiol 2003; 41: 1414-8.
- Itoh M, Okamoto S, Kariya H. Survey of 200 cases of sporotrichosis. Dermatologica 1986; 172: 209-13.
- Jacobson ES. Pathogenic roles for fungal melanins. Clin Microbiol Rev 2000; 13: 708-17.
- Kajiwara H, Saito M, Ohga S, Uenotsuchi T, Yoshida S. Impaired host defense against *Sporothrix schenckii* in mice with chronic granulomatous disease. Infect Immun 2004; 72: 5073-9.
- Kano R, Nakamura Y, Watanabe S, Tsujimoto H, Hasegawa A. Identification of *Sporothrix schenckii* based on sequences of the chitin synthase 1 gene. Mycoses 2001; 44: 261-5.
- Kano R, Watanabe K, Murakami M, Yanai T, Hasegawa A. Molecular diagnosis of feline sporotrichosis. Vet Rec 2005; 156: 484-5.
- Kano R, Anzawa K, Mochizuki T, Nishimoto K, Hiruma M, Kamata H, et al. *Sporothrix schenckii* (sensu strict *S. globosa*) mating type 1-2 (MAT1-2) gene. J Dermatol 2013; 40(9): 726-30.
- Katz HI. Drug interactions of the newer oral antifungal agents. Br J Dermatol 1999; 141 Suppl 56: 26-32.
- Kauffman CA, Bustamante, Chapman SW, Pappas PG. Clinical practice guidelines for the management of sporotrichosis: 2007 update by the Infectious Diseases Society of America. Clin Infect Dis 2007; 45: 1255-65.

- Keiser P, Whittle D. Sporotrichosis in human immunodeficiency virus-infected patients: report of a case. *Rev Infect Dis* 1991; 13: 1027-8.
- Kwon-Chung KJ, Bennett JE. *Medical Mycology*. 2<sup>nd</sup> ed. Philadelphia: Lea & Febiger; 1992. p. 707-29.
- Kurosawa A, Pollock SC, Collins MP, Kraff CR, Tso MOM. *Sporothrix schenckii* endophthalmitis in a patient with human immunodeficiency virus infection. *Arch Ophthalmol* 1988; 106: 376-80.
- Lacaz CS. Esporotricose e outras micoses gomosas. In: Lacaz CS, Porto E, Martins JEC, Heins-vaccari EM, Melo NT. *Tratado de Micologia Médica Lacaz*. 9. ed. São Paulo: Sarvier; 2002. p. 479-97.
- Langfelder K, Streibel M, Jahn B, Haase G, Brakhage AA. Biosynthesis of fungal melanins and their importance for human pathogenic fungi. *Fungal Genet Biol* 2003; 38: 143-58.
- Li M, Chen Q, Sun J, Shen Y, Liu W. Inflammatory response of human keratinocytes triggered by *Sporothrix schenckii* via toll-like receptor 2 and 4. *J Dermatol Sci* 2012; 66: 80-2.
- Li S, Song Y, Liu Y, Wei T. Analysis of sporotrichosis cases in 6-year-period in Changchun, Northeast China. In: *Abstract Book of the 1<sup>st</sup> International Meeting on Sporothrix and Sporotrichosis*; 2013 Oct 2-4; Rio de Janeiro, Brasil. Rio de Janeiro: ISHAM Working Group on *Sporothrix*; 2013. p. 45.
- Lima OC, Figueiredo CC, Pereira BAS, Coelho MGP, Morandi V, Lopes-Bezerra LM. Adhesion of the human pathogen *Sporothrix schenckii* to several extracellular matrix proteins. *Braz J Med Biol Res* 1999; 32: 651-7.
- Lima OC, Figueiredo CC, Previato JO, Mendonça-Previato L, Morandi V, Lopes-Bezerra LM. Involvement of fungal cell wall components in adhesion of *Sporothrix schenckii* to human fibronectin. *Infect Immun* 2001; 69: 6874-80.
- Lima OC, Bouchara JP, Reiner G, Marot-Leblond A, Chabasse D, Lopes-Bezerra LM. Immunofluorescence and flow cytometry analysis of fibronectin and laminin binding to *Sporothrix schenckii* yeast cells and conidia. *Microb Pathog* 2004; 37: 131-40.
- Lipstein-Kresch E, Isenberg HD, Singer C, Cooke O, Greenwald RA. Disseminated *Sporothrix schenckii* infection with arthritis in a patient with acquired immunodeficiency syndrome. *Rheumatol* 1985; 12: 805-8.
- Liu GY, Nizet V. Color me bad: microbial pigments as virulence factors. *Trends Microbiol* 2009; 17: 406-13.
- Liu TT, Zhang K, Zhou X. Molecular identification of *Sporothrix* clinical isolates in China. *J Zhejiang Univ Sci B* 2014; 15(1): 100-8.

- Liu X, Zhang Z, Hou B, Wang D, Sun T, Li F, et al. Rapid identification of *Sporothrix schenckii* in biopsy tissue by PCR. *J Eur Acad Dermatol Venereol* 2013; 27(12): 1491-7.
- Londero AT, Ramos CD. Esporotricose no Rio Grande do Sul. Três décadas de observação. *An Bras Dermatol* 1989; 64: 307-10.
- Lopes JO, Alves SH, Mari CR, Brum LM, Westphalen JB, Altermann MJ, et al. Epidemiology of sporotrichosis in the central region of Rio Grande do Sul. *Rev Soc Bras Med Trop* 1999; 32(5): 541-5.
- Lutz A, Splendore A. Sobre uma mycose observada em homens e ratos. *Rev Med S Paulo* 1907; 21: 433-50.
- Madrid H, Cano J, Gene J, Bonifaz A, Toriello C, Guarro J. *Sporothrix globosa*, a pathogenic fungus with widespread geographical distribution. *Rev Iberoam Micol* 2009; 26: 218-22.
- Madrid H, Gene J, Cano J, Silvera C, Guarro J. *Sporothrix brunneoviolacea* and *Sporothrix dimorphospora*, two new members of the *Ophiostoma stenoceras-Sporothrix schenckii* complex. *Mycologia* 2010; 102: 1193-203.
- Madrid IM, Xavier MO, Mattei AS, Fernandes GS, Guim TN, Santin R, et al. Role of melanin in the pathogenesis of cutaneous sporotrichosis. *Microbes Infect* 2010a; 12: 162-5.
- Madrid IM, Mattei A, Martins A, Nobre M, Meireles M. Feline sporotrichosis in the southern region of Rio Grande do Sul, Brazil: clinical, zoonotic and therapeutic aspects. *Zoonoses Public Health* 2010b; 57(2): 151-4.
- Madrid IM, Mendes RS, Prestes C, Neto FMS. Surveillance and control of the human and animal sporotrichosis in the city of Pelotas, Rio Grande do Sul, Brazil. In: Abstract Book of the 1<sup>st</sup> International Meeting on *Sporothrix* and Sporotrichosis; 2013 Oct 2-4; Rio de Janeiro, Brasil. Rio de Janeiro: ISHAM Working Group on *Sporothrix*; 2013. p. 61.
- Maia DC, Sassa MF, Placeres MC, Carlos IZ. Influence of Th1/Th2 cytokines and nitric oxide in murine systemic infection induced by *Sporothrix schenckii*. *Mycopathologia* 2006; 161: 11-9.
- Marimon R, Cano J, Gene J, Sutton DA, Kawasaki M, Guarro J. *Sporothrix brasiliensis*, *S. globosa*, and *S. mexicana*, three new *Sporothrix* species of clinical interest. *J Clin Microbiol* 2007; 45: 3198-206.
- Marimon R, Gené J, Cano J, Guarro J. *Sporothrix luriei*: a rare fungus from clinical origin. *Med Mycol* 2008a; 46(6): 621-5.
- Marimon R, Serena C, Gené J, Cano J, Guarro J. In vitro antifungal susceptibilities of five species of *Sporothrix*. *Antimicrob Agents Chemother* 2008b; 52: 732-4.

Marques SA, Franco SRVS, Camargo RMP, Dias LDF, Haddad-Júnior V, Fabris VE. Esporotricose do gato doméstico (*Felis catus*): transmissão humana. Rev Inst Med Trop São Paulo 1993; 35(4): 327-30.

Martins EB. Perfil epidemiológico, clínico e terapêutico da esporotricose no Instituto de Pesquisa Clínica Evandro Chagas – Fiocruz, Rio de Janeiro, no período de 2002 a 2004. Rio de Janeiro. Dissertação [Mestrado em Medicina Tropical] – Instituto Oswaldo Cruz; 2006.

Matter SE, Bailey DM, Sexton DJ. Immune deficiency presenting as disseminated sporotrichosis. J Okla State Med Assoc 1984; 77: 114-7.

Meinerz AR, Nascente PS, Schuch LF, Cleff MB, Santin R, Brum CS, et al. Suscetibilidade in vitro de isolados de *Sporothrix schenckii* frente à terbinafina e itraconazol. Rev Soc Bras Med Trop 2007; 40: 60-2.

Mesa-Arango AC, Reyes-Montes MR, Pérez-Mejía A, Navarro-Barranco H, Souza V, Zúñiga G, et al. Phenotyping and genotyping of *Sporothrix schenckii* isolates according to geographic origin and clinical form of sporotrichosis. J Clin Microbiol 2002; 40: 3004-11.

Micromedex [homepage na internet]. The Complete Drug Reference [acesso em 04 fev 2014]. Disponível em: <http://www-micromedexsolutions-com.ez68.periodicos.capes.gov.br/micromedex2/librarian/>.

Mirbod-Donovan F, Schaller R, Hung CY, Xue J, Reichard U, Cole GT. Urease produced by *Coccidioides posadasii* contributes to the virulence of this respiratory pathogen. Infect Immun 2006; 74: 504-15.

Morgado FN, Schubach AO, Barros MBL, Conceição-Silva F. The *in situ* inflammatory profile of lymphocutaneous and fixed forms of human sporotrichosis. Med Mycol 2011; 49: 612-20.

Morgan M, Reves R. Invasive sinusitis due to *Sporothrix schenckii* in a patient with AIDS. Clin Infect Dis 1996; 23: 1319-20.

Morris-Jones R, Youngchim S, Gomez BL, Aisen P, Hay RJ, Nosanchuk JD, et al. Synthesis of melanin-like pigments by *Sporothrix schenckii* in vitro and during mammalian infection. Infect Immun 2003; 71: 4026-33.

Mylonakis E. *Galleria mellonella* and the Study of Fungal Pathogenesis: Making the Case for Another Genetically Tractable Model Host. Mycopathologia 2008; 165: 1–3.

Nascimento RC, Almeida SR. Humoral immune response against soluble and fractionate antigens in experimental sporotrichosis. FEMS Immunol Med Microbiol 2005; 43: 241–7.

Nascimento RC, Espindola NM, Castro RA, Teixeira PA, Loureiro y Penha CV, Lopes-Bezerra LM, et al. Passive immunization with monoclonal antibody against a 70-kDa putative adhesin of *Sporothrix schenckii* induces protection in murine sporotrichosis. Eur J Immunol 2008; 38: 3080-9.



Neto RJP, Machado AA, Castro G, Quaglio ASS, Martinez R. Esporotricose cutânea disseminada como manifestação inicial da síndrome da imunodeficiência adquirida – relato de caso. Rev Soc Bras Med Trop 1999; 32: 57-61.

Netto HM. Sporotrichosis in São Paulo city: the beginning of an outbreak. In: Abstract Book of the 1<sup>st</sup> International Meeting on *Sporothrix* and Sporotrichosis; 2013 Oct 2-4; Rio de Janeiro, Brasil. Rio de Janeiro: ISHAM Working Group on *Sporothrix*; 2013.

Nosanchuk JD, Casadevall A. The contribution of melanin to microbial pathogenesis. Cell Microbiol 2003; 5: 203-23.

Nosanchuk JD, Casadevall A. Impact of melanin on microbial virulence and clinical resistance to antimicrobial compounds. Antimicrob Agents Chemother 2006; 50: 3519-28.

Oliveira MME, Almeida-Paes R, Muniz MM, Barros MBL, Gutierrez-Galhardo MC, Zancopé-Oliveira RM. Sporotrichosis caused by *Sporothrix globosa* in Rio de Janeiro, Brazil: case report. Mycopathologia 2010; 169: 359-63.

Oliveira MME, Almeida-Paes R, Muniz MM, Gutierrez-Galhardo MC, Zancopé-Oliveira RM. Phenotypic and molecular identification of *Sporothrix* isolates from an endemic area of sporotrichosis in Brazil. Mycopathologia 2011; 172: 257-67.

Oliveira MME, Sampaio P, Almeida-Paes R, Pais C, Gutierrez-Galhardo MC, Zancopé-Oliveira RM. Rapid Identification of *Sporothrix* Species by T3B Fingerprinting. J Clin Microbiol 2012; 50: 2159-162.

Oliveira MME, Almeida-Paes R, Gutierrez-Galhardo MC, Zancopé-Oliveira RM. Molecular identification of the *Sporothrix schenckii* complex. Rev Iberoam Micol 2014a; 31: 2-6.

Oliveira MME, Veríssimo C, Sabino R, Aranha J, Zancopé-Oliveira RM, Sampaio P, et al. First autochthonous case of sporotrichosis by *Sporothrix globosa* in Portugal. Diagn Microbiol Infect Dis 2014b; 78: 388-90.

Orofino-Costa R, Boia MN, Magalhães GA, Damasco PS, Bernardes-Engemann AR, Benvenuto F, et al. Arthritis as a hypersensitivity reaction in a case of sporotrichosis transmitted by a sick cat: clinical and serological follow up of 13 months. Mycoses 2010; 53: 81-3.

Orofino-Costa R, Bernardes-Engemann AR, Azulay-Abulafia L, Benvenuto F, Neves Mde L, Lopes-Bezerra LM. Sporotrichosis in pregnancy: case reports of 5 patients in a zoonotic epidemic in Rio de Janeiro, Brazil. An Bras Dermatol 2011; 86(5): 995-8.

Oscherwitz SL, Rinaldi MG. Disseminated sporotrichosis in a patient infected with human immunodeficiency virus. Clin Infect Dis 1992; 15: 568-9.

Penha CV, Bezerra LM. Concanavalin A-binding cell wall antigens of *Sporothrix schenckii*: a serological study. Med Mycol 2000; 38: 1-7.

Penn CC, Goldstein E, Bartholomew WR. *Sporothrix schenckii* meningitis in a patient with AIDS. Clin Infect Dis 1992; 15: 741-3.

- Pereira SA, Gremião I, Kitada A, Silva J, Boechat J, Viana P, et al. Occurrence of feline sporotrichosis cases diagnosed at Evandro Chagas Clinical Research Institute – Fiocruz, Rio de Janeiro, Brazil (2005-2011). *Mycoses* 2012; 55(S4): 148.
- Quintella LP, Passos SR, do Vale AC, Galhardo MC, Barros MB, Cuzzi T, et al. Histopathology of cutaneous sporotrichosis in Rio de Janeiro: a series of 119 consecutive cases. *J Cutan Pathol* 2011; 38(1): 25-32.
- Quintella LP, Passos SR, de Miranda LH, Cuzzi T, Barros MB, Francesconi-do-Vale AC, et al. Proposal of a histopathological predictive rule for the differential diagnosis between American tegumentary leishmaniasis and sporotrichosis skin lesions. *Br J Dermatol* 2012; 167(4): 837-46.
- Ramos-e-Silva J. Sporotrichosis in Brazil. In: Marshall J. *Essays on tropical dermatology*. Amsterdam: Excerpta Medica; 1972. p. 370-86.
- Ramos-e-Silva M, Lima CM, Schechtman RC, Trope BM, Carneiro S. Systemic mycoses in immunodepressed patients (AIDS). *Clin Dermatol* 2012; 30: 616–27.
- Read SI, Sperling LC. Feline sporotrichosis. Transmission to man. *Arch Dermatol* 1982; 118(6): 429-31.
- Reis EG, Gremião ID, Kitada AA, Rocha RF, Castro VS, Barros MB, et al. Potassium iodide capsule treatment of feline sporotrichosis. *J Feline Med Surg* 2012; 14(6): 399-404.
- Reis RS, Almeida-Paes R, Muniz MM, Tavares PMS, Monteiro PCF, Schubach TMP, et al. Molecular characterisation of *Sporothrix schenckii* isolates from humans and cats involved in the sporotrichosis epidemic in Rio de Janeiro, Brazil. *Mem Inst Oswaldo Cruz* 2009; 104: 769-74.
- Riley PA. Melanin. *Int J Biochem Cell Biol* 1997; 29: 1235-9.
- Rippon JW. *Medical Mycology: the pathogenic fungi and the pathogenic actinomycetes*. 3<sup>rd</sup> ed. Philadelphia: WB Saunders; 1988. p. 325-52.
- Rodrigues AM, de Hoog S, de Camargo ZP. Emergence of pathogenicity in the *Sporothrix schenckii* complex. *Med Mycol* 2013a; 51: 405–12.
- Rodrigues AM, Teixeira MdM, de Hoog GS, Schubach TMP, Pereira SA, Fernandes GF, et al. Phylogenetic Analysis Reveals a High Prevalence of *Sporothrix brasiliensis* in Feline Sporotrichosis Outbreaks. *PLoS Negl Trop Dis* 2013b; 7(6): e2281.
- Romeo O, Scordino F, Criseo G. New insight into molecular phylogeny and epidemiology of *Sporothrix schenckii* species complex based on calmodulin-encoding gene analysis of Italian isolates. *Mycopathologia* 2011; 172: 179-86.
- Romero-Martinez R, Wheeler M, Guerrero-Plata A, Rico G, Torres-Guerrero H. Biosynthesis and functions of melanin in *Sporothrix schenckii*. *Infect Immun* 2000; 68: 3696-703.

Ruiz-Baca E, Toriello C, Perez-Torres A, Sabanero-Lopez M, Villagomez-Castro JC, Lopez-Romero E. Isolation and some properties of a glycoprotein of 70 kDa (Gp70) from the cell wall of *Sporothrix schenckii* involved in fungal adherence to dermal extracellular matrix. *Med Mycol* 2009; 47: 185-96.

Sampaio SAP, Lacaz CS, Almeida F. Aspectos clínicos da esporotricose em São Paulo. *Rev Hosp Clin Fac Med São Paulo* 1954; 9(6): 391-402.

Sanchotene KO, Bergamaschi MP, Xavier MO. Feline Sporotrichosis in Rio Grande, RS, Brazil. In: Abstract Book of the 1<sup>st</sup> International Meeting on *Sporothrix* and Sporotrichosis; 2013 Oct 2-4; Rio de Janeiro, Brasil. Rio de Janeiro: ISHAM Working Group on *Sporothrix*; 2013. p. 76.

Sandhu GS, Kline BC, Stockman L, Roberts GD. Molecular probes for diagnosis of fungal infections. *J Clin Microbiol* 1995; 33: 2913-9.

Scheinfeld N. A review of the new antifungals: posaconazole, micafungin, and anidulafungin. *J Drugs Dermatol* 2007; 6: 1249-51.

Schenck BR. On refractory subcutaneous abscess caused by a fungus possibly related to the *Sporotricha*. *Bull Johns Hopkins Hosp* 1898; 93: 286-90.

Schneider MC, Aguilera XP, Barbosa da Silva Junior J, Ault SK, Najera P, Martinez J, et al. Elimination of neglected diseases in Latin America and the Caribbean: a mapping of selected diseases. *PLoS Negl Trop Dis* 2011; 5(2): e964.

Schubach TMP, Schubach AO. Esporotricose em gatos e cães - revisão. *Clínica Veterinária* 2000; 29: 21-4.

Schubach TM, Valle AC, Gutierrez-Galhardo MC, Monteiro PC, Reis RS, Zancopé-Oliveira RM, et al. Isolation of *Sporothrix schenckii* from the nails of domestic cats (*Felis catus*). *Med Mycol* 2001; 39: 147-9.

Schubach TMP, Schubach AO, Reis RS, Cuzzi-Maya T, Blanco TCM, Monteiro DF, et al. *Sporothrix schenckii* isolated from domestic cats with and without sporotrichosis in Rio de Janeiro, Brazil. *Mycopathologia* 2002; 153: 83-6.

Schubach TMP, Schubach AO, Cuzzi-Maya T, Okamoto T, Reis RS, Monteiro PCF, et al. Pathology of sporotrichosis in 10 cats of Rio de Janeiro. *Vet Rec* 2003; 152: 172-5.

Schubach TMP, Schubach AO, Okamoto T, Barros MBL, Figueiredo FB, Cuzzi T, et al. Evaluation of an epidemic of sporotrichosis in cats: 347 cases (1988-2001). *J Am Vet Med Assoc* 2004; 224: 1623-9.

Schubach AO, Schubach TMP, Barros MBL. Epidemic cat-transmitted sporotrichosis. *N Engl J Med* 2005; 353: 1185-6.

Scott EN, Muchmore HG, Fine DP. Activation of the alternative complement pathway by *Sporothrix schenckii*. *Infect Immun* 1986; 51: 6-9.

- Scott EN, Muchmore HG. Immunoblot analysis of antibody responses to *Sporothrix schenckii*. J Clin Microbiol 1989; 27: 300-4.
- Sgarbi DB, Silva AJ, Carlos IZ, Silva CL, Angluster J, Alviano CS. Isolation of ergosterol peroxide and its reversion to ergosterol in the pathogenic fungus *Sporothrix schenckii*. Mycopathologia 1997; 139: 9-14.
- Shaw JC, Levinson W, Montanaro A. Sporotrichosis in the acquired immunodeficiency syndrome. J Am Acad Dermatol 1989; 21: 1145-7.
- Shi M, Li SS, Zheng C, Jones GJ, Kim KS, Zhou H, et al. Real-time imaging of trapping and urease-dependent transmigration of *Cryptococcus neoformans* in mouse brain. J Clin Invest 2010; 120: 1683-93.
- Sigler L, Harris JL, Dixon DM, Flis AL, Salkin IF, Kemna M, et al. Microbiology and potential virulence of *Sporothrix cyanescens*, a fungus rarely isolated from blood and skin. J Clin Microbiol 1990; 28: 1009-15.
- Silva MB, Costa MM, Torres CC, Galhardo MC, Valle AC, Magalhães MAF, et al. Urban sporotrichosis: a neglected epidemic in Rio de Janeiro, Brazil. Cad Saude Publica 2012; 28: 1867-80.
- Silva-Vergara ML, de Camargo ZP, Silva PF, Abdalla MR, Sgarbieri RN, Rodrigues AM, et al. Disseminated *Sporothrix brasiliensis* infection with endocardial and ocular involvement in an HIV-infected patient. Am J Trop Med Hyg 2012; 86(3): 477-80.
- Silveira CP, Torres-Rodriguez JM, Alvarado-Ramirez E, Murciano-Gonzalo F, Dolande M, Panizo M, et al. MICs and minimum fungicidal concentrations of amphotericin B, itraconazole, posaconazole and terbinafine in *Sporothrix schenckii*. J Med Microbiol 2009; 58: 1607-10.
- Singer JI, Muncie JE. Sporotrichosis. Etiologic considerations and report of additional cases from New York. New York State J Med 1952; 52: 2147-53.
- Song Y, Li SS, Zhong SX, Liu YY, Yao L, Huo SS. Report of 457 sporotrichosis cases from Jilin province, northeast China, a serious endemic region. J Eur Acad Dermatol Venereol 2013; 27(3): 313-8.
- Sterling JB, Heymann WR. Potassium iodide in dermatology: a 19th century drug for the 21st century-uses, pharmacology, adverse effects, and contraindications. J Am Acad Dermatol 2000; 43: 691-7.
- St-Germain G, Summerbell R. Identifying filamentous fungi. In: A clinical laboratory handbook. California: Star Publishing Company; 1996.
- Suzuki K, Kawasaki M, Ishizaki H. Analysis of restriction profiles of mitochondrial DNA from *Sporothrix schenckii* and related fungi. Mycopathologia 1988; 103: 147-51.
- Tachibana T, Matsuyama T, Mitsuyama M. Characteristic infectivity of *Sporothrix schenckii* to mice depending on routes of infection and inherent fungal pathogenicity. Med Mycol 1998; 36: 21-7.

- Tachibana T, Matsuyama T, Mitsuyama M. Involvement of CD4<sup>+</sup> T cells and macrophages in acquired protection against infection with *Sporothrix schenckii* in mice. *Med Mycol* 1999; 37: 397-404.
- Takeda Y, Kawasaki M, Ishizaki H. Phylogeny and molecular epidemiology of *Sporothrix schenckii* in Japan. *Mycopathologia* 1991; 116: 9-14.
- Tavanti A, Hensgens LA, Mogavero S, Majoros L, Senesi S, Campa M. Genotypic and phenotypic properties of *Candida parapsilosis* sensu strictu strains isolated from different geographic regions and body sites. *BMC Microbiol* 2010; 10: 203–13.
- Teixeira PA, Castro RA, Nascimento RC, Tronchin G, Torres AP, Lazera M, et al. Cell surface expression of adhesins for fibronectin correlates with virulence in *Sporothrix schenckii*. *Microbiology* 2009; 155: 3730-8.
- Toledo MS, Tagliari L, Suzuki E, Silva CM, Straus AH, Takahashi HK. Effect of anti-glycosphingolipid monoclonal antibodies in pathogenic fungal growth and differentiation. Characterization of monoclonal antibody MEST-3 directed to Man $\alpha$ 1-->3Man $\alpha$ 1-->2IPC. *BMC Microbiol* 2010; 10: 47.
- Thomaz L, García-Rodas R, Guimarães AJ, Taborda CP, Zaragoza O, Nosanchuk JD. *Galleria mellonella* as a model host to study *Paracoccidioides lutzii* and *Histoplasma capsulatum*. *Virulence* 2013; 4: 139-46.
- Torinuki W, Tagami H. Complement activation by *Sporothrix schenckii*. *Arch Dermatol Res* 1985; 277: 332-3.
- Torres-Mendoza BM, Vazquez-Valls E, Gonzalez-Mendoza A. Effect of potassium iodide on the immune response in the sporotrichosis. *Rev Iberoam Micol* 1997; 14: 98–100.
- Travassos C, Laguardia J, Marques PM, Mota JC, Szwarcwald CL. Comparison between two race/skin color classifications in relation to health-related outcomes in Brazil. *Int J Equity Health* 2011; 10: 35.
- Uenotsuchi T, Takeuchi S, Matsuda T, Urabe K, Koga T, Uchi H, et al. Differential induction of Th1-prone immunity by human dendritic cells activated with *Sporothrix schenckii* of cutaneous and visceral origin to determine their different virulence. *Int Immunol* 2006; 18: 1637-46.
- Valle ACF, Gutierrez-Galhardo MC. Esporotricose. In: Tavares W, Marinho LAC. Rotinas de diagnóstico e tratamento das doenças infecciosas e parasitárias. 3. ed. São Paulo: Atheneu; 2012. p. 332-6.
- Verma S, Verma GK, Singh G, Kanga A, Shanker V, Singh D, et al. Sporotrichosis in sub-himalayan India. *PLoS Negl Trop Dis* 2012; 6(6): e1673.
- von den Driesch P. Sweet's syndrome (acute febrile neutrophilic dermatosis). *J Am Acad Dermatol* 1994; 31: 535–56.
- Wang Y, Aisen P, Casadevall A. Melanin, melanin "ghosts", and melanin composition in *Cryptococcus neoformans*. *Infect Immun* 1996; 64: 2420-4.

Ware AJ, Cockerell CJ, Skiest DJ, Kussman HM. Disseminated sporotrichosis with extensive cutaneous involvement in a patient with AIDS. *J Am Acad Dermatol* 1999; 40: 350-5.

Wheeler MH, Bell AA. Melanins and their importance in pathogenic fungi. *Curr Top Med Mycol* 1988; 2: 338-87.

Yu X, Wan Z, Zhang Z, Li F, Li R, Liu X. Phenotypic and molecular identification of *Sporothrix* isolates of clinical origin in Northeast China. *Mycopathologia* 2013; 176(1-2): 67-74.

Zancopé-Oliveira RM, Almeida-Paes R, Oliveira MME, Freitas DFS, Gutierrez-Galhardo MC. New diagnostic applications in sporotrichosis. In: Khopkar U, editor. *Skin biopsy perspectives*. Rijeka: In Tech; 2011. p. 53-72.

## ANEXOS

# ANEXO A – Parecer Consubstanciado do Comitê de Ética



Ministério da Saúde

FIOCRUZ  
Fundação Oswaldo Cruz

Instituto de Pesquisa Clínica Evandro Chagas



Comitê de Ética em Pesquisa

## PARECER CONSUBSTANCIADO – 037/2010

Protocolo 0024.0.009.000-10

### 1. Identificação:

**Título do Projeto:** "Avaliação de fatores epidemiológicos, micológicos, clínicos e terapêuticos associados à esporotricose".

**Pesquisadora Responsável:** Maria Clara Gutierrez Galhardo.

**Doutorando:** Dayvisson Francis Saraiva Freitas.

**Instituição Responsável:** Instituto de Pesquisa Clínica Evandro Chagas/FIOCRUZ.

**Data de Apresentação ao CEP:** 07/05/2010.

### 2. Sumário:

Visa a avaliar fatores epidemiológicos, clínicos e terapêuticos dos casos envolvidos na epidemia/endemia de esporotricose. Tem como objetivos específicos: descrever os aspectos epidemiológicos, clínicos e terapêuticos dos casos envolvidos na epidemia/endemia de esporotricose; analisar a possível associação de fatores sócio-demográficos, epidemiológicos e clínicos com as formas clínicas da doença; determinar o genótipo e estudar a virulência dos diferentes isolados de *S. schenckii* nos pacientes com lesões que necessitaram de mais de um ano de tratamento e dos pacientes com recidiva de lesões; correlacionar as lesões dermatológicas das formas cutâneas (nódulo, ulceração, placa verrucosa) com o tempo de evolução da esporotricose; avaliar fatores relacionados às seqüelas e recidivas no pós-tratamento imediato da esporotricose. Este projeto constitui uma parte do projeto intitulado "Dez anos de epidemia de esporotricose no estado do Rio de Janeiro: estudo clínico-epidemiológico dos casos atendidos no Instituto de Pesquisa Clínica Evandro Chagas entre 2005-2008 com ênfase nos fatores de virulência de isolados de *Sporothrix schenckii*", aprovado por este Comitê de Ética em Pesquisa em 31/07/2008 sob o CAAE 0021.0.009.000-08. Trata-se de estudo de série de casos, de pacientes com esporotricose e primeiro atendimento no IPEC entre janeiro de 2005 e dezembro de 2010, por levantamento do prontuário. Serão incluídos somente pacientes com primeiro atendimento no IPEC no período proposto e com isolamento de *S. Schenckii*, em cultura, nos espécimes clínicos coletados. Espera-se incluir em torno de 1200 pacientes, sendo os dados coletados em uma ficha padronizada e inseridos no programa SPSS 11.0. Para caracterização genotípica das cepas isoladas em momentos diferentes será utilizada a técnica de PCR *fingerprinting* com o *primer* M13 e para virulência, ensaio de fagocitose em cultura de macrófagos.

### 3. Observações Gerais: (Atendendo à Resolução CNS 196/96).

Projeto com delineamento adequado. Por se tratar de projeto retrospectivo/prospectivo foi apresentado um Termo de Compromisso e Responsabilidade do Pesquisador em relação ao sigilo, à confidencialidade e à privacidade das informações e, um Termo de Consentimento Livre e Esclarecido em linguagem acessível ao sujeito de pesquisa. Os exames laboratoriais de diagnóstico e acompanhamento dos pacientes inseridos no projeto já fazem parte da rotina de atendimento clínico e realização dos exames, não constituindo impacto nos gastos habituais do IPEC.



"Avaliação de fatores epidemiológicos, micológicos, clínicos e terapêuticos associados à esporotricose".


**4. Diligências:**

Sim. Foram satisfeitas.

**5. Parecer: APROVADO.**

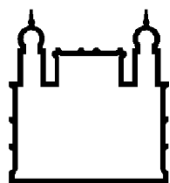
**Data: 30 de julho de 2010.**

**Assinatura do Coordenador:**



**Dr.<sup>a</sup> Léa Camillo-Coura**  
Coordenadora do Comitê  
de Ética em Pesquisa  
IPEC / FIOCRUZ

## ANEXO B – Termo de Compromisso e Responsabilidade



Ministério da Saúde

**FIOCRUZ**

**Fundação Oswaldo Cruz**

INSTITUTO DE PESQUISA CLÍNICA EVANDRO CHAGAS



### TERMO DE COMPROMISSO E RESPONSABILIDADE

Eu, Maria Clara Gutierrez Galhardo, coordenadora do projeto de pesquisa intitulado “Avaliação de fatores epidemiológicos, micológicos, clínicos e terapêuticos associados à esporotricose.”, me comprometo em manter a confidencialidade assim como a privacidade dos participantes do projeto.

A identidade dos participantes, assim como os resultados obtidos com este projeto, serão mantidos em um banco de dados sob a minha responsabilidade.

Os resultados obtidos com esta pesquisa serão divulgados em comunicações científicas mantendo o anonimato dos participantes e o material utilizado não será empregado em outras pesquisas, a não ser quando abertos novos protocolos.

Rio de Janeiro, \_\_\_\_ / \_\_\_\_ / \_\_\_\_\_

---

Maria Clara Gutierrez Galhardo

## APÊNDICE

## APÊNDICE A – Certificado em Congresso Internacional: Melhor Pôster



### CERTIFICATE

We hereby certify that

**Dayvison Francis Saraiva Freitas**

has presented and was awarded with the best poster prize

**“In vivo evolution of virulence in a patient with disseminated *Sporothrix brasiliensis*”**

in the **1<sup>st</sup> International Meeting on *Sporothrix* and Sporotrichosis.**

Co-authors:

**Suelen Silvana dos Santos, Rodrigo Almeida Paes, Manoel Marques Evangelista de Oliveira, Antonio Carlos Francesconi do Valle, Maria Clara Gutierrez-Galhardo, Rosely Maria Zancopé-Oliveira, Joshua D. Nosanchuk.**

Rio de Janeiro, October 4<sup>th</sup> 2013

Leila Maria Lopes-Bézerra, PhD  
**1<sup>st</sup> IMSs President**