

## Pathogenesis of schistosomal 'pipestem' fibrosis: a low-protein diet inhibits the development of 'pipestem' fibrosis in mice

E. M. COUTINHO\*, M. M. DE SOUZA<sup>†</sup>, L. M. SILVA<sup>†</sup>,  
C. L. CAVALCANTI\*, R. E. DE ARAUJO\*, A. A. BARBOSA Jr.<sup>†</sup>,  
A. W. CHEEVER<sup>†</sup> AND Z. A. ANDRADE<sup>†</sup>

\*Aggeu Magalhães Research Centre (FIOCRUZ), Recife PE and <sup>†</sup>Gonçalo Moniz Research Centre (FIOCRUZ) Salvador, BA, Brazil.

Received for publication 19 November 1996

Accepted for publication 1 July 1997

**Summary.** Mice maintained on a low protein diet for 30 days and then infected with *Schistosoma mansoni* for 16 weeks completely failed to develop 'pipestem fibrosis' of the liver, whereas 50% of well nourished controls did. Usually mice with relatively mild and prolonged *S. mansoni* infection develop two different pathological pictures: one consisting of disseminated portal fibrosis caused by periovular granulomas concentrated at the portal spaces (pipestem fibrosis), the other represented by scattered hepatic granulomas. The reason for this dual response is poorly understood. Combined results from parasitological, histopathological, biochemical and morphometric data revealed that peri-ovular granulomas of undernourished mice were smaller, inflammation was less intense and there was minimal fibrosis in comparison with those of controls, which suggest that a vigorous host response is necessary for the pathogenesis of schistosomal portal fibrosis.

**Keywords:** pipestem fibrosis, schistosomiasis, periovular granuloma, undernutrition

A microscopic form of periportal fibrosis, mimicking the gross schistosomal 'pipestem' fibrosis seen in man, was described by Warren (1966) in mice with prolonged (16 weeks or more) and relatively mild (1–2 worm pairs) *Schistosoma mansoni* infection. In the mouse model periportal fibrosis clearly results from massive and continuous deposition of parasite eggs along previously dilated intrahepatic periportal veins (Andrade 1987). However, the lesion occurs only in 30–50% of the animals, even when inbred mice are used (Andrade & Cheever 1993). This suggests that time and parasite

load are not the only important factors but that some peculiar type of host reactivity is also necessary for the development of the classical and systematized periportal fibrosis. Henderson *et al.* (1993) observed 'pipestem' fibrosis and marked splenomegaly in 19–24% of male CBA-J inbred mice chronically infected with *S. mansoni* and detected immunological differences between the animals that developed the lesions and those that showed only scattered hepatic periovular granulomas and moderate splenomegaly. The former group failed to generate anti-idiotypic antibodies and this was interpreted as a factor interfering with the protective down modulation of peri-ovular granulomas in chronically infected mice.

Correspondence: Dr Z. A. Andrade, Chief, Laboratory of Experimental Pathology, Gonçalo Moniz Research Centre, Rua Valdemar Falcão, 121, 40.295–001 Salvador, Bahia, Brazil.

Mice maintained on a multideficient and essentially low-protein diet were infected with *S. mansoni* and observed for a prolonged period of time. The undernourished animals completely failed to develop 'pipestem' fibrosis while 50% of the controls maintained on a balanced diet did. The parasitological and pathological findings observed are here analysed regarding their implications on the pathogenesis of schistosomal periportal fibrosis.

## Materials and methods

White Swiss mice of both sexes were submitted to percutaneous infection with 30 recently shed *S. mansoni* cercariae obtained from laboratory raised *Biomphalaria glabrata* (L strain). One group of infected mice was placed in a special diet cage 30 days before infection and remained until the end of the experiment. The diet consisted of kidney beans (*Phaseolus vulgaris*), manioc flour (*Manihot esculenta*), low fat, dried and salted meat and sweet potato (*Iponacea batatas*). This diet was planned to simulate the one usually consumed by the poor people in North-east Brazil and is thus referred to as Regional Basic Diet (RBD) (Coutinho 1980; Coutinho et al. 1992). The percentages (g%) for its main ingredients are: kidney beans 18.34 (3.99 proteins, 10.66 carbohydrates, 0.24 fat, 0.57 minerals, 1.09 fibre); manioc flour: 64.81 (0.84 proteins, 48.59 carbohydrates, 0.12 fat, 0.43 minerals, 5.64 fibre); dried salted meat: 3.74 (2.74 proteins, 0.43 carbohydrates, 0.06 fat, 0.06 minerals); sweet potato: 12.76 (0.30 proteins, 9.99 carbohydrates, 0.03 fat, 0.20 minerals, 0.48 fibre). Considering the total, the diet consisted of 7.87% proteins, 69.67% carbohydrates, 0.80% fat, 1.26% minerals, 7.21% fibre (KCal% 336.15, NDpCal% 5.64). Another group of mice was fed with a balanced, commercial mouse diet (Nuvital Nutrientes Ltda, Colombo, Paraná, Brazil), with 22% protein content. Diets were given in pellet form. Weights of all animals were recorded weekly.

Sixteen weeks after cercarial exposure the animals were anaesthetized with ether and submitted to perfusion of the portal system by the method of Duvall & DeWitt (1967) for worm recovery. The liver and spleen were removed and weighed. Pieces of the liver were placed in 4% potassium hydroxide for the counting of eggs (Cheever 1970). Fragments of liver, spleen, intestines and lung were fixed in Bouin's fixative and/or in buffered (Ph.7.4) 10% formalin. These tissues were embedded in paraffin and the 5 µm-thick sections were stained with haematoxylin and eosin and the picro-sirius-red method for collagen (Junqueira et al. 1979).

Morphometry. Randomly sampled 5 µm-thick liver

histological sections stained with picrosirius-red for collagen were examined by semiautomatic morphometry using the Leica Q500MC Image Processing and Analysis System (Leica Cambridge, Cambridge, England). For morphometric measurements a total sectional area of 6.6 mm<sup>2</sup> per animal was evaluated. All periovular granulomas were included. A spherical shape and normal size distribution were assumed. The following granuloma parameters were calculated: size, volume density and numerical density. The granuloma volume density was calculated as the quotient of the total granuloma profile area to the total sectional area studied per animal. The number of granulomas per unit volume of liver was assessed by applying the Weibel's formula (Weibel 1969). The sectional area of the fibrous tissue, red stained, was directly measured and calculated as a percentage of the total area examined.

Collagen was measured as hydroxyproline by the method B of Bergman & Loxley (1963) and hydroxyproline levels were corrected for intensity of infection by dividing total hepatic hydroxyproline (without correction for hydroxyproline levels in uninfected mice) by the number of *S. mansoni* eggs in the liver. The results were evaluated by covariance analysis using the number of liver eggs as the covariate.

Statistical analysis for other variables employed the 2-tailed *t*-test.

## Results

Initial and final weights of the animals belonging to each group appear in Table 1. Animals maintained on the low-protein diet reached only half the weight of the well-nourished animals at the end of the experiment. Table 2 presents parasitological data and liver and spleen weights.

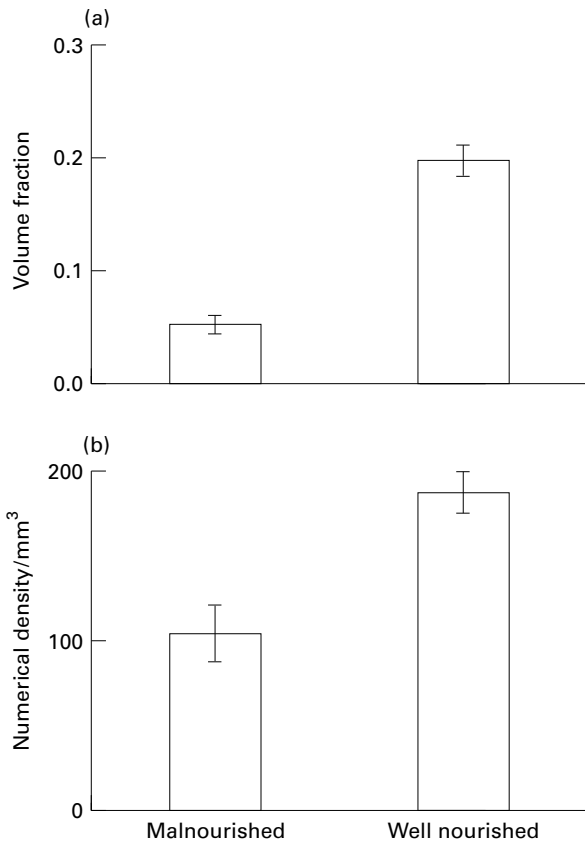
Malnourished mice had fewer worms and fewer eggs per worm pair in the liver compared to mice on a normal diet. Liver and spleen weights were greater in well nourished mice both in absolute terms and in relation to

**Table 1.** Body weights of mice at the beginning and end of the experiment

Group	Body weight	
	Initial	Final
Malnourished	13.4 ±1.0	21.2 ±4.3
Normal diet		
pipestem	13.4 ±1.0	45.4 ±4.1
no pipestem	13.4 ±1.0	45.6 ±3.5
all mice	13.4 ±1.0	45.5 ±3.6

Table 2. Organ weights and parasitological data from malnourished and well nourished mice. Mean  $\pm$  standard deviation

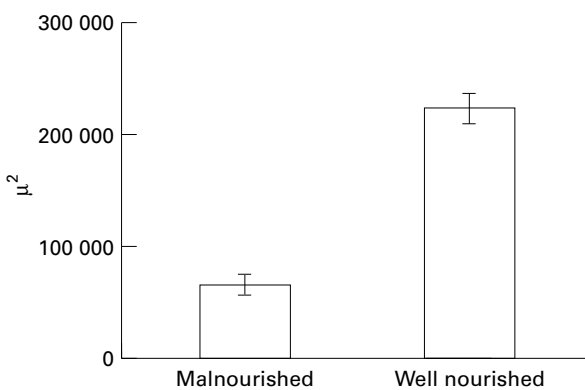
Group (number of mice)	Worm pairs	Liver weight (g)	Liver as % BW	Spleen (mg)	Spleen (as % BW)	Eggs/g liver ( $\times 10^3$ )	Eggs/liver ( $\times 10^3$ )	Eggs/WP/Liver ( $\times 10^3$ )
Malnourished Normal diet- all mice (17)	1.47 $\pm$ 0.94	0.91 $\pm$ 0.20	4.34 $\pm$ 0.79	78 $\pm$ 29	0.36 $\pm$ 0.10	4.28 $\pm$ 3.75	4.0 $\pm$ 4.03	3.21 $\pm$ 1.14
Pipestem (7)	3.13 $\pm$ 1.75	2.73 $\pm$ 0.45	5.98 $\pm$ 0.77	327 $\pm$ 107	0.71 $\pm$ 0.21	4.27 $\pm$ 3.49	11.9 $\pm$ 11.2	6.20 $\pm$ 3.32
No pipestem (9)	3.00 $\pm$ 2.00	2.63 $\pm$ 0.27	5.82 $\pm$ 0.65	347 $\pm$ 129	0.76 $\pm$ 0.24	5.06 $\pm$ 3.84	13.4 $\pm$ 10.6	5.62 $\pm$ 4.71
	3.56 $\pm$ 3.29	2.80 $\pm$ 0.56	6.11 $\pm$ 0.87	311 $\pm$ 91	0.68 $\pm$ 0.19	3.65 $\pm$ 3.29	16.3 $\pm$ 6.56	5.44 $\pm$ 2.32



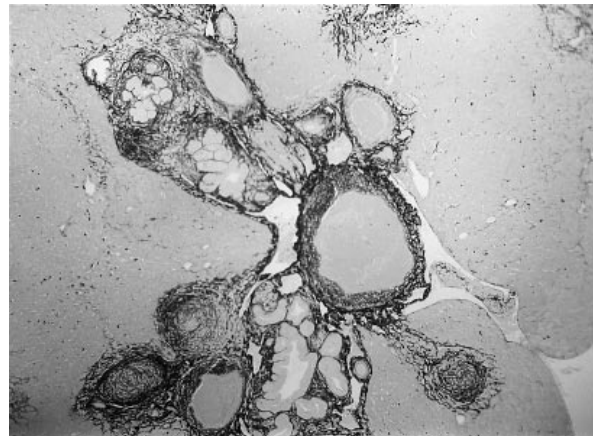
**Figure 1.** Measurements of schistosomal periovular granuloma volume fraction (a) and numerical density (b) in relation to the state of nutrition.

body weight (Table 2). Normal nourished mice (controls) with and without pipestem fibrosis showed none of these differences.

Morphometric analysis showed that the volumetric and numerical density of granulomas was greater in the well-nourished mice (Fig. 1) than in the malnourished mice



**Figure 2.** Morphometry of schistosomal granuloma size in the liver of well nourished and undernourished mice.

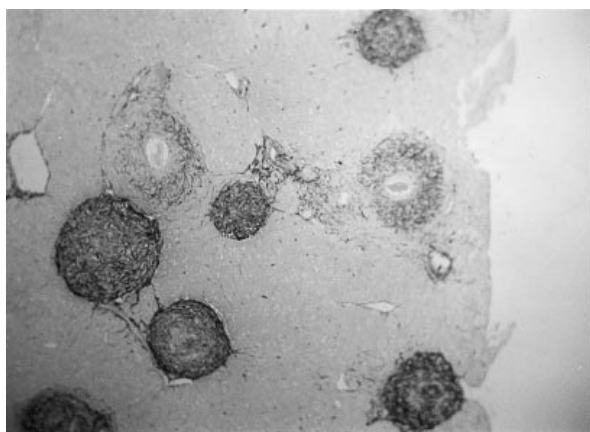


**Figure 3.** Periovular schistosomal granulomas, fibrosis, proliferation of bile ducts, dilatation and intimal thickening of the main portal vein branch contribute to the expansion of the portal space in this example of 'pipestem' fibrosis induced by schistosomiasis observed in well-nourished mouse. Picrosirius-red staining method for collagen, (160 X).

( $P < 0.0001$  and  $0.001$ , respectively). Hepatic granulomas were smaller in the malnourished mice ( $P < 0.0001$ , Fig. 2).

Pipestem liver fibrosis was seen in 7 of 16 (43.7%) infected mice maintained on normal diet and in none of the 16 animals maintained on a protein-deficient diet. Pipestem fibrosis was represented by a preponderant deposition of eggs and periovular granulomas along the periportal spaces of the liver (Fig. 3). Granulomas were usually quite large, containing proliferating fibroblasts and concentric collagen fibre. Periovular necrosis was rarely seen. There was a predominantly eosinophilic cellular infiltration at the periphery of most of the granulomas. Extra-granulomatous fibrosis was also prominent and contributed to the expansion of the periportal areas. Portal vein branches showed various lesions, including peri-phlebitis, endo-phlebitis, and obstruction by granulomas. There was also endothelial cell proliferation and the formation of new vascular canals, which were dilated, congested and thin-walled. Focal and sometimes diffuse portal infiltration by lymphocytes, polymorphonuclear eosinophil leukocytes and plasma cells was frequently observed, but was seldom prominent. In contrast the parenchyma maintained its normal appearance. Hepatic vein branches were without changes.

Nine infected and well-nourished mice without pipestem fibrosis presented scattered granulomas in the liver, without forming large plaques of fibrosis by a preferential accumulation within the portal spaces (Fig. 4). The 16 mice maintained on a protein deficient diet presented the same hepatic microscopical picture as the above group.



**Figure 4.** Isolated periovular granulomas appear scattered in the liver of a malnourished mouse. Lesions show no tendency to concentrate around portal areas. Picrosirius-red method for collagen. (160 X).

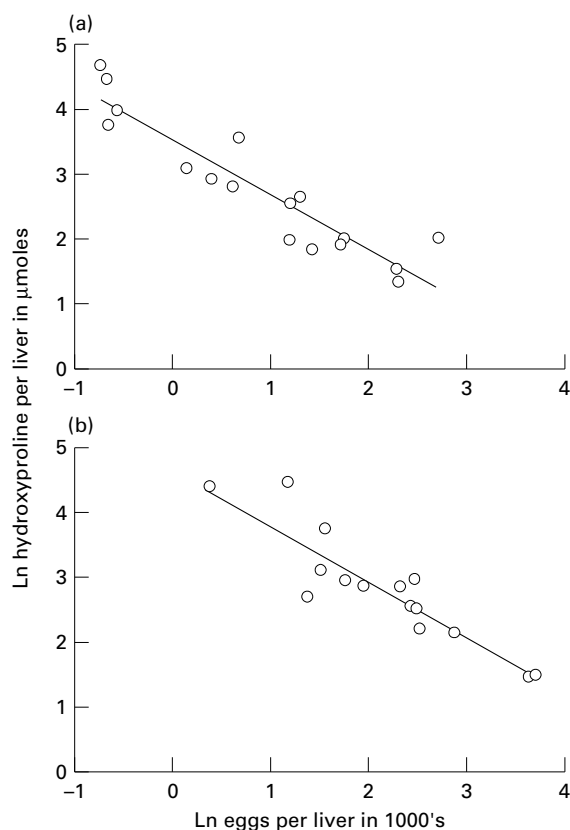
However, periovular granulomas were smaller and with scanty fibrosis. Their livers and spleens were considerably smaller than those from the animals in the two other groups (see Table 2 where the weights are represented as percentages of body weight).

Hepatic fibrosis was diminished in malnourished mice ( $P < 0.0001$ ) when measured morphometrically in total amount and as a percentage of hepatic tissue ( $6.3 \pm 5.1\%$  in malnourished mice and  $13.9 \pm 7.7\%$  in infected control mice). The hydroxyproline levels were also decreased in malnourished mice ( $P < 0.0001$ , Fig. 5A). Hydroxyproline levels did not differ in well-nourished mice with and without pipestem fibrosis (Fig. 5B). Although animals with Symmers' fibrosis showed focal concentrations of periportal fibrous tissue, the overall levels of hepatic fibrosis in relation to egg numbers did not differ from the levels in animals without portal fibrosis.

## Discussion

The present experiments revealed that malnourished mice given a protein deficient diet lost weight and, when chronically infected with *S. mansoni*, did not develop the picture of schistosomal periportal fibrosis, whereas almost half of the controls maintained on a balanced diet showed Symmers' pipestem fibrosis. Malnourished mice also had lower numbers of worm pairs, reduced number of hepatic eggs per worm pair, smaller circumoval granulomas and reduced levels of hepatic fibrosis by both morphometric and chemical analysis.

Previous results (Warren 1966; Andrade 1987; Andrade & Cheever 1993; Henderson *et al.* 1993) have shown that mice with prolonged schistosome infection



**Figure 5.** Hydroxyproline content in the liver of mice infected with *Schistosoma mansoni*: a, Malnourished mice and b, Well-nourished mice.

tend to present two different hepatic pathological pictures: one being periportal accumulation of granulomas and fibrosis ('pipestem' fibrosis) and the other represented by scattered periovular granulomas within the liver. The first type of change has been considered the experimental morphological counterpart of human schistosomal pipestem fibrosis (Warren 1966). A critical appraisal of the significance of this experimental model has already been presented (Andrade & Cheever 1993). Although schistosomal periportal fibrosis in mice does not reproduce every details of human pipestem fibrosis, it is a good experimental model of that condition. The model is reproducible, practical and, on a cost benefit basis, the best available. Here it was used to investigate obscure aspects related to the pathogenesis of hepatic schistosomiasis. A deficient diet induced malnutrition in mice, with considerable loss of body weight and generalized atrophy of internal organs, but without signs of severe nutritional dysfunction such as fatty liver, associated bacterial or viral infections, dry and scaly skin or hair changes. The induced picture mimics the maras-

matic clinical form of human protein-caloric malnutrition (Coutinho *et al.* 1992).

Protein deficiency interferes with the immune status of the host in several ways. It is considered a potent immunodepressant (Meira 1995). Under the present circumstances it can be said that malnutrition inhibited the development of pipestem fibrosis in mice, probably by depressing their immunological responses as reflected in the size and composition of hepatic periportal granulomas. Egg-induced granulomas formed during *S. mansoni* infection are CD4-dependent cell-mediated hypersensitivity reactions, which are associated with a strong Th2 response and represent the principal pathologic manifestation of the disease in mice (Warren *et al.* 1967; Grzych *et al.* 1991; Lukacs & Boros 1993). Therefore a vigorous immunological response is a prerequisite for the granulomatous inflammation and fibrosis that are necessary for the formation of the pipestem fibrosis pattern in the liver.

The effect of host nutrition on the parasite worm is not completely understood. It is probable that in the present experimental conditions the worm life span could be shortened, the fecundity lowered and egg maturation disturbed. These factors, in conjunction, could also affect the outcome of the pathologic process.

### Acknowledgements

Thanks are due to Wladimir Gomes de Melo for technical assistance and the Brazilian Research Council (CNPq) for financial support.

### References

- ANDRADE Z.A. & CHEEVER A.W. (1993) Characterization of the murine model of schistosomal hepatic periportal fibrosis ('pipestem' fibrosis). *Int. J. Exp. Pathol.* **74**, 195–202.
- ANDRADE Z.A. (1987) Pathogenesis of pipe stem fibrosis of the liver (Experimental observations on murine schistosomiasis). *Mem. Inst. Oswaldo Cruz* **82**, 325–334.
- BERGMAN I. & LOXLEY R. (1963) Two improved and simplified methods for the spectrophotometric determination of hydroxyproline. *Anal. Chem.* **35**, 1961–1965.
- CHEEVER A.W. (1970) Relative resistance of the eggs of human schistosomes to digestion in potassium hydroxide. *Bull. Wild. Hth. Organiz.* **43**, 601–603.
- COUTINHO E.M. (1980) Patobiologia da desnutrição nas doenças parasitárias. *Mem. Inst. Oswaldo Cruz* **75**, 63–76.
- COUTINHO E.M., FREITAS L.P.C.G. & ABATH F.G.C. (1992) The influence of the regional basic diet from Northeast Brazil on health and nutritional conditions of mice infected with *Schistosoma mansoni*. *Rev. Soc. Bras. Med. Trop.* **25**, 13–20.
- DUVALL R.H. & DEWITT W.B. (1967) An improved perfusion technique for recovering adult schistosomes from laboratory animals. *Am. J. Trop. Med. Hyg.* **16**, 483–486.
- GRZYCH J.M., PEARSE E., CHEEVER A.W., CALADA Z.A., CASPAR P., HEINY S., LEWIS F. & SHER A. (1991) Egg deposition is the major stimulus for the production of Th2 cytokine granuloma in murine schistosomiasis. *J. Immunol.* **146**, 1322–1327.
- HENDERSON G.S., NIX N.A., MONTESANO M.A., GOLD D., FREEMAN G.L. JR, MCCURLEY T.L., COLLEY D.G. (1993) Two distinct pathological syndromes in male CBA/J inbred mice with chronic *Schistosoma mansoni* infections. *Am. J. Pathol.* **142**, 703–714.
- JUNQUEIRA L.C.U., BIGNOLAS G. & BRENTANI R. (1979) Picrosirius staining plus polarization microscopy, a specific method for collagen detection in tissue sections. *Histochem. J.* **11**, 447–455.
- LUKACS N.W. & BOROS D.L. (1993) Lymphokine regulation of granuloma formation in murine schistosomiasis mansoni. *Clin. Immunol. Immunopathol.* **68**, 57–63.
- MEIRA D.A. (1995) Interaction of infection, nutrition and immunity. *Rev. Soc. Bras. Med. Trop.* **28**, 315–319.
- WARREN K.S. (1966) The pathogenesis of 'clay-pipe stem cirrhosis' in mice with chronic schistosomiasis mansoni, with a note on the longevity of the schistosomes. *Am. J. Pathol.* **49**, 477–489.
- WARREN K.S., DOMINGO E.O. & COWAN R.B.T. (1967) Granuloma formation around schistosome egg as a manifestation of delayed hypersensitivity. *Am. J. Pathol.* **51**, 735–756.
- WEIBEL E. (1969) Stereological principles for morphometry in electron microscopic cytology. *Int. Rev. Cytol.* **26**, 235–302.