

Transient Hearing Loss in Adults Associated With Zika Virus Infection

Eriko S. Vinhaes,¹ Luciane A. Santos,² Lisiane Dias,¹ Nilvano A. Andrade,¹ Victor H. Bezerra,¹ Anderson T. de Carvalho,¹ Laise de Moraes,² Daniele F. Henriques,³ Sasha R. Azar,⁴ Nikos Vasilakis,⁴ Albert I. Ko,^{2,5} Bruno B. Andrade,^{2,6} Isadora C. Siqueira,² Ricardo Khouri,^{2,7} and Viviane S. Boaventura^{1,2,8}

¹Hospital Santa Izabel, Salvador, ²Centro de Pesquisas Gonçalo Moniz, Fundação Oswaldo Cruz, Fundação Oswaldo Cruz/MS, Salvador, and ³World Health Organization Collaborating Center for Reference and Research on Arbovirus, Instituto Evandro Chagas, Fundação Nacional de Saúde, Ministério da Saúde, Belém, Brazil; ⁴Department of Pathology, Center for Biodefense and Emerging Infectious Diseases, University of Texas Medical Branch, Galveston, ⁵Department of Epidemiology of Microbial Diseases, Yale School of Public Health, New Haven, Connecticut, ⁶Multinational Organization Network Sponsoring Translational and Epidemiological Research Initiative, José Silveira Foundation, Salvador, Brazil; ⁷KU Leuven, Department of Microbiology and Immunology, Rega Institute for Medical Research, Laboratory of Clinical and Epidemiological Virology, Leuven, Belgium; and ⁸Faculdade de Medicina da Bahia, Universidade Federal da Bahia, Salvador, Brazil

In 2015, during the outbreak of Zika virus (ZIKV) in Brazil, we identified 3 cases of acute hearing loss after exanthematous illness. Serology yielded finding compatible with ZIKV as the cause of a confirmed ($n = 1$) and a probable ($n = 2$) flavivirus infection, indicating an association between ZIKV infection and transient hearing loss.

Keywords. Zika virus; sensorineural hearing loss; tinnitus; dizziness.

Zika virus (ZIKV) is an arbovirus (family Flaviviridae, genus *Flavivirus*) that has been reported in Africa and Asia. In March 2015, ZIKV was first detected in Rio Grande do Norte, Brazil [1]. Since then, ZIKV has spread rapidly throughout northeast Brazil and autochthonous circulation has been documented in the United States [2, 3].

Most cases of ZIKV infection exhibit mild to moderate symptoms including exanthema, conjunctivitis, headache, fever, arthralgia, and myalgia. Additionally, an increased number of neurologic disorders have been reported in a temporal relationship with the ZIKV infection epidemic in Brazil [4] and other countries [2]. Although hearing loss has been previously reported in 1 patient during ZIKV infection in

Malaysia, hearing impairment was not confirmed by audiometric test [5].

Here we report 1 confirmed and 2 probable acute ZIKV cases based on clinical evaluation and serological exams with transient sensorineural hearing loss (SNHL) supported by time-based audiometric exams, admitted between May and July 2015, during the ZIKV outbreak in Bahia, Brazil [4]. This study was approved by the Hospital Santa Izabel (Bahia) institutional review board (number 484.908). Informed written consent was obtained from all participants.

Patient 1

On 29 July 2015, a 23-year-old man was admitted to the ear, nose, and throat emergency department (ENTED) at Santa Izabel Hospital, with a 2-day history of hearing impairment complaining in the right ear, without tinnitus or dizziness, with normal otoscopic findings. Two weeks prior to admission, he experienced fever and itching exanthema for 3 days; myalgia, asthenia, headache, and periarticular edema in wrists for 2 days; and mild arthralgia in the ankles and wrists for 15 days (Figure 1A). On 31 July, when hearing complaints were resolved, a first audiometry test was performed and detected a mild hearing loss in the right ear (Supplementary Figure 1). Immunoglobulin M (IgM) antibody capture enzyme-linked immunosorbent assay (MAC-ELISA) of acute-phase sera collected on 29 July found anti-ZIKV IgM antibodies but not IgM antibodies for dengue virus (DENV) or other arboviruses. Plaque reduction neutralization titer (PRNT) evaluation of convalescent samples collected 7 months later demonstrated a 4-fold increase in neutralizing antibody titers to ZIKV in the absence of a titer increase to DENV2 when compared to acute-phase titers (Supplementary Figure 1).

Patient 2

On 30 May 2015, a 54-year-old woman was seen in an ENTED with moderate bilateral hearing loss and no abnormality in otologic and otoneurologic examinations. Three days prior to the medical visit, she experienced itching exanthema (symptoms persisted for 3 days), mild arthralgia in both feet (13 days), dizziness (6 days), bilateral metallic tinnitus (21 days), periarticular edema in hands and feet, retroocular pain, myalgia, and headache (14 days) (Figure 1B). A previous audiometry examination was performed in 2014, showing mild SNHL in right and left ear. A second audiometry examination was performed on 5 June 2015, during acute symptoms for ZIKV, which revealed a bilateral mild to moderate hearing loss involving all frequencies in the right and left ear. Audiometric examination was performed again on 10 July 2015, revealing complete recovery to prior hearing thresholds (Figure 1B). MAC-ELISA testing of acute-phase sera collected on July 3 found anti-ZIKV and

Received 18 May 2016; editorial decision 4 November 2016; accepted 16 November 2016; published online December 1, 2016.

Correspondence: V. Boaventura, Rua Waldemar Falcão, 121, Candeal, Salvador-Bahia, Brazil 40296-710 (viviane.boaventura@bahia.fiocruz.br).

Clinical Infectious Diseases® 2017;64(5):675–7

© The Author 2016. Published by Oxford University Press for the Infectious Diseases Society of America. This is an Open Access article distributed under the terms of the Creative Commons Attribution-NonCommercial-NoDerivs licence (<http://creativecommons.org/licenses/by-nc-nd/4.0/>), which permits non-commercial reproduction and distribution of the work, in any medium, provided the original work is not altered or transformed in any way, and that the work is properly cited. For commercial re-use, please contact journals.permissions@oup.com. DOI: 10.1093/cid/ciw770

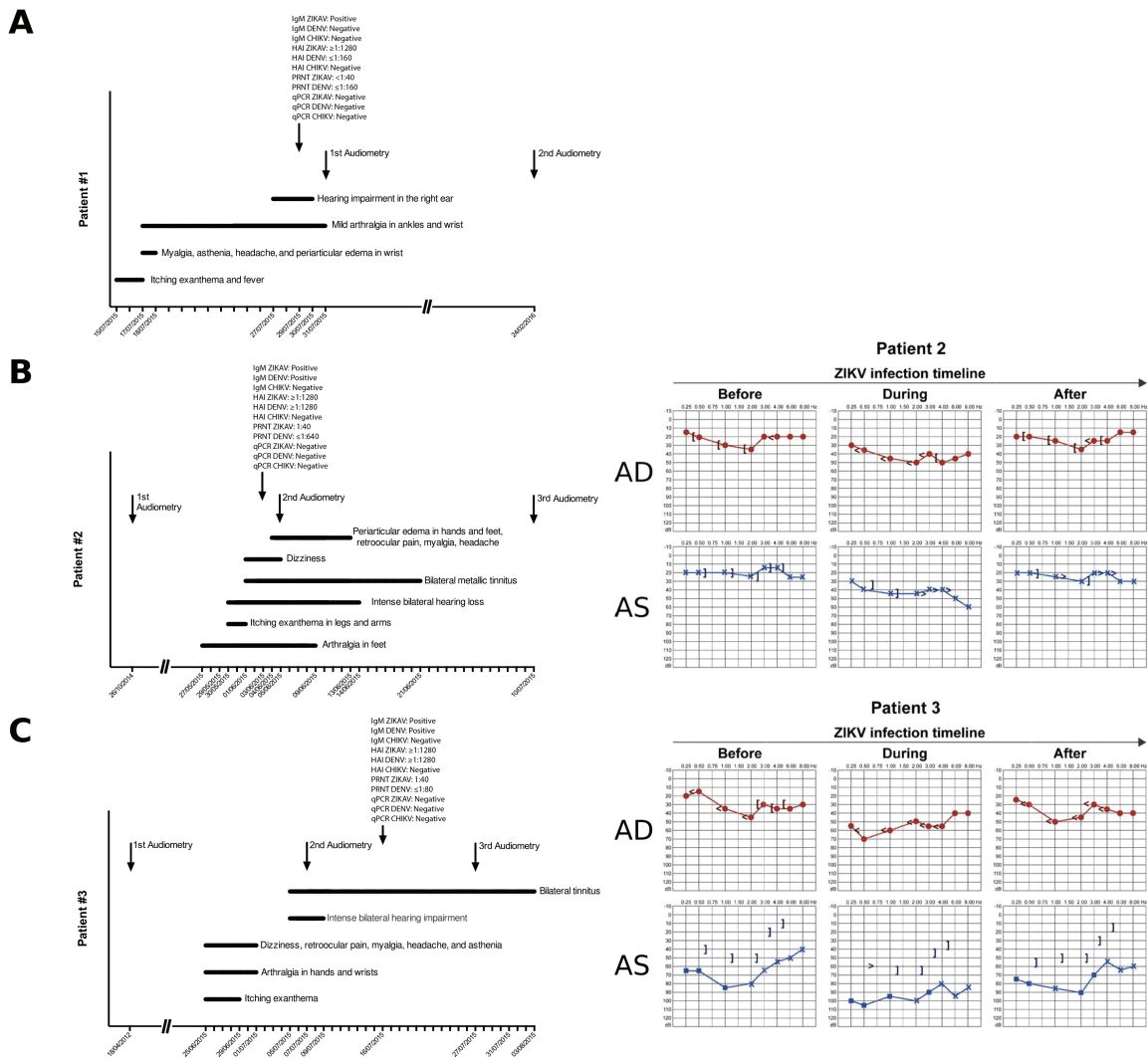


Figure 1. Clinical course and laboratory results and time-based audiometry examinations for Zika virus–infected patients 1–3 (A–C, respectively). For the audiometry examinations, the frequency in hertz of the test tones is shown on the horizontal axis and sound intensity in decibels is shown on the vertical axis. Red symbols indicate responses for the right ear (AD), and blue symbols indicate responses for the left ear (AS). The “X” and “O” symbols represent responses to air-conducted stimuli. The “■” symbols represent responses to air-conducted stimuli with masking. The “<” and “>” symbols represent responses to bone-conducted stimuli. The “[” and “]” symbols represent responses to bone-conducted stimuli with masking. Thresholds of ≤ 20 dB were considered normal. Abbreviations: CHIKV, Chikungunya virus; DENV, dengue virus; HAI, hemagglutination inhibition assays; IgM, immunoglobulin M; PRNT, plaque reduction neutralization titer; qPCR, polymerase chain reaction; ZIKV, Zika virus.

DENV IgM antibodies, but not antibodies to chikungunya virus or other arboviruses. PRNT testing of convalescent samples collected 7 months later demonstrated an 8-fold increase in neutralizing antibody titers for ZIKV and DENV2 compared with acute-phase titers (Supplementary Table 3).

Patient 3

On 7 July 2015, a 58-year-old woman was admitted to the ENTED with a 2-day history of intense bilateral hearing impairment and tinnitus similar to falling tap water. No abnormalities in vestibular exams were detected. Thirteen days prior to admission, the patient experienced itching exanthema for 5 days, retroocular pain, myalgia, headache, asthenia,

dizziness, and arthralgia in both hands and wrists for 7 days. A previous audiometric exam, performed in 2012, revealed a moderate to severe mixed hearing loss (MHL) in the left ear, caused by a dry central membrane tympanic perforation in the left ear, and a mild SNHL in the right ear. On 7 July, a new audiometric test revealed a profound MHL in the left ear and a moderate SNHL in the right ear. Interestingly, hearing loss was more intense in lower pitches, making speech perception difficult. An audiometry performed on July 27 revealed a partial recovery of hearing thresholds as compared to the audiometric exam performed in 2012 (Figure 1C). MAC-ELISA testing of acute-phase sera collected on July 16 found anti-ZIKV and DENV IgM antibodies, but not antibodies

to chikungunya virus or other arboviruses. PRNT results of convalescent samples collected 7 months later demonstrated a 16-fold increase in neutralizing antibodies for ZIKV, but not for DENV2 (Supplementary Table 3).

DISCUSSION

Hearing loss has been sporadically reported during infection with flaviviruses, including West Nile virus [6, 7], DENV [8], and ZIKV [5]. A previously published case report suggesting ZIKV infection in association with hearing loss symptoms was not accompanied by audiometric tests and lacked strong evidence of the scenario [5]. Here we demonstrated that unilateral or bilateral hearing loss, tinnitus, and dizziness may occur during or early after ZIKV infection in adults (2 probable cases and 1 confirmed case), supported by time-based audiometric exams. Transient otologic symptoms persisted for up to 28 days causing moderate to severe hearing disability and interfering with speech comprehension.

The 3 cases reported in this study occurred during the ZIKV outbreak in Bahia, Brazil [4], had compatible clinical symptoms for an acute ZIKV infection, and had anti-ZIKV IgM antibodies detected in acute-phase sera. All patients tested negative for ZIKV by quantitative polymerase chain reaction (qPCR), probably because of the time frame between infection onset and sampling [2]. Patients 2 and 3 had anti-DENV IgM ELISA antibodies, although this may be possibly due to the serologic cross-reactivity between ZIKV and DENV [2]. Comparing samples from acute to convalescent phase, we observed that PRNT values for ZIKV increased for all patients (patient 1, 1:40 to 1:160; patient 2, 1:40 to 1:320; patient 3, <1:40 to 1:320). While patients 1 and 3 did not demonstrate an anti-DENV2 titer increase in PRNT, we observed an 8-fold increase for patient 2 (1:640 to 1:5120). MAC-ELISA findings therefore provide confirmatory evidence in patient 1 for an acute ZIKV infection and suggestive evidence for patient 3. Based on the sum of serologic results and the lack of additional convalescent samples to perform PRNT and hemagglutination assay to the other flavivirus and DENV serotypes, we considered patient 2 as inconclusive. Despite the extensive distribution of DENV in several countries, including Brazil [2], there is only 1 published case of sudden SNHL related to DENV hemorrhagic fever [8]. In addition, this DENV study had important confounding factors associated with hearing impairment that could not be excluded from the analysis, such as systemic vascular leak syndrome and antipyretic drugs [9, 10], reducing the impact of DENV infection associated with hearing loss.

The mechanism of SNHL associated with acute virus infection involves damage of the inner ear or auditory nerve, by a direct viral effect or mediated by an autoimmune process as previously described [11, 12]. For patient 2, bilateral hearing loss was totally recovered, whereas a partial recovery was

detected for patient 3. This partial recovery for patient 3 might be explained due to a progression of her previous middle ear process. Nonetheless, she denied any acuteness of the inactive chronic otitis media during these 3 years.

In conclusion, this report of 3 cases indicates that transient hearing impairment may be a specific manifestation of acute ZIKV disease. A subsequent case-control study would be necessary to demonstrate this causal relationship and elucidate the mechanisms leading to auditory dysfunction in this setting. Further investigation might also highlight other possible rare events such as permanent hearing loss, facilitating the possible recommendation of audiometry examinations in adults during ZIKV outbreaks.

Supplementary Data

Supplementary materials are available at *Clinical Infectious Diseases* online. Consisting of data provided by the author to benefit the reader, the posted materials are not copyedited and are the sole responsibility of the author, so questions or comments should be addressed to the author.

Notes

Acknowledgments. The authors thank Dr Pedro F. Vasconcelos (Instituto Evandro Chagas) for his suggestions on this work; Dr Marco Krieger (Instituto de Biologia Molecular do Paraná) for providing qPCR kits (BIOMOL assay for ZIKV and 18S host gene); and Adriana Lima Nunes for assistance with audiometric examinations.

Financial support. This work was supported by the National Institutes of Health (grant numbers 1 R01 AI121207 and R24 AI120942). R. K. and L. A. S. were supported by "Programa Ciências sem fronteiras," Conselho Nacional de Desenvolvimento Científico e Tecnológico of Brazil.

Potential conflicts of interest. All authors: No reported conflicts. All authors have submitted the ICMJE Form for Disclosure of Potential Conflicts of Interest. Conflicts that the editors consider relevant to the content of the manuscript have been disclosed.

References

1. Zanluca C, de Melo VCA, Mosimann ALP, et al. First report of autochthonous transmission of Zika virus in Brazil. *Mem Inst Oswaldo Cruz* 2015; 110:569–72.
2. Petersen LR, Jamieson DJ, Powers AM, Honein MA. Zika virus. *N Engl J Med* 2016; 374:1552–63.
3. Weaver SC, Costa F, Garcia-Blanco MA, et al. Zika virus: history, emergence, biology, and prospects for control. *Antiviral Res* 2016; 130:69–80.
4. Paploski IAD, Prates APPB, Cardoso CW, et al. Time lags between exanthematous illness attributed to Zika virus, Guillain-Barré syndrome, and microcephaly, Salvador, Brazil. *Emerg Infect Dis* 2016; 22:1438–44.
5. Tappe D, Nachtigall S, Kapaun A, Schnitzler P, Günther S, Schmidt-Chanasi J. Acute Zika virus infection after travel to Malaysian Borneo, September 2014. *Emerg Infect Dis* 2015; 21:911–3.
6. Casetta I, Ciorba A, Cesnik E, Trevisi P, Tugnoli V, Bovo R. West Nile virus neuroinvasive disease presenting with acute flaccid paralysis and bilateral sensorineural hearing loss. *J Neurol* 2011; 258:1880–1.
7. Weatherhead JE, Miller VE, Garcia MN, et al. Long-term neurological outcomes in West Nile virus-infected patients: an observational study. *Am J Trop Med Hyg* 2005; 92:1006–12.
8. Ribeiro BNF, Guimarães ACG, Yazawa F, et al. Sensorineural hearing loss in hemorrhagic dengue? *Int J Surg Case Rep* 2015; 8C:38–41.
9. Taki M, Nin F, Hasegawa T, et al. Case report: two cases of hearing impairment due to intracranial hypotension. *Auris Nasus Larynx* 2009; 36:345–8.
10. Schreiber BE, Agrup C, Haskard DO, Luxon LM. Sudden sensorineural hearing loss. *Lancet* 2010; 375:1203–11.
11. Cohen BE, Durstenfeld A, Roehm PC. Viral causes of hearing loss: a review for hearing health professionals. *Trends Hear* 2014; 18:1–17.
12. Greco A, Fusconi M, Gallo A, Marinelli C, Macri GF, De Vincentiis M. Sudden sensorineural hearing loss: an autoimmune disease? *Autoimmun Rev* 2011; 10:756–61.