

# INTRAUTERINE INFECTION WITH MUMPS VIRUS

Aparecida G. P. Garcia, MD,  
João Mario S. Pereira, MD, Nilo Vidigal, MD,  
Yolanda Y. Lobato, MD, Claudia S. Pegado, MD,  
and Joari P. Castelo Branco, MD

The histopathologic study of 3 cases of gestational mumps is presented. The tissue studied was obtained from a spontaneous abortion (case 1) and from 2 therapeutic abortions (cases 2 and 3). Severe placental and fetal lesions were observed, indicating a probable association with maternal mumps. The main placental lesion was a diffuse proliferative necrotic villitis with severe lesions in the fetal vascular circuit, probably the cause of death. In the fetal viscera, areas of necrosis and mineralization were observed. Viral inclusions identical to those described in mumps infection were observed in the chorionic and fetal tissues. (*Obstet Gynecol* 56:756, 1980)

The incidence of gestational mumps in prospective studies has been variously estimated to be between 0.8 and 10 cases per 10,000 pregnancies.<sup>1,2</sup> An excessive number of abortions is associated with the infection during pregnancy.<sup>3-8</sup> Young,<sup>9</sup> in a review of the literature, stated that no lesions of the placenta have been described in gestational mumps. Herbst et al<sup>10</sup> studied a placenta from a patient with epidemic parotitis and detected abnormalities only by electron microscopy.

The present report is based on the anatomic and histopathologic study of a spontaneous abortion after maternal mumps and on material obtained by uterine

---

*From the Department of Pathology, Instituto Fernandes Figueira, Fundação Oswaldo Cruz, Rio de Janeiro, Brazil.*

*Supported by a grant from Conselho Nacional de Desenvolvimento Científico e Tecnológico (CNPq).*

*Submitted for publication January 30, 1980.*

curettage from 2 gravid women who had the virus disease at the beginning of pregnancy.

## Material

Tissues obtained for these studies were from a macerated fetus and placenta (case 1) from Maternidade Clovis Correa da Costa, Instituto Fernandes Figueira, Rio de Janeiro, and material obtained by therapeutic abortion (cases 2 and 3). The authors' information is based on the epidemiologic and clinical data; there were no virologic studies or serologic diagnoses of the maternal disease.

The fetal and placental tissues were fixed in 10% formalin and embedded in paraffin. Hematoxylin and eosin stain was used on all sections; Shorr, periodic acid-Schiff (PAS), Perl, and Kossa stains were used for identification of viral inclusions and analysis of the areas of fetal visceral necrosis and mineralization.

## Case Reports

### Case 1

A 29-year-old white woman, gravida 2, para 1, had an estimated date of confinement of January 26, 1965. Her last menstrual period had begun on April 19, 1964. Her previous pregnancy had been normal. On September 14, the patient developed bilateral parotid swelling (mumps) with low-grade fever. She had been exposed to mumps, as several cases were registered in the neighborhood. She was admitted with the diagnosis of a missed abortion with a history of 2 previous episodes of bleeding. Induction of labor was not successful and a hysterotomy was performed.

Macroscopic examination revealed a severely macerated 90-g male fetus that measured 19 cm in total length. The placenta was bulky (85 g), ovoid (15.5 × 8 × 1 cm), and without precise limits due to villous edema. The fetal membranes were moderately thickened and the chorionic vessels were prominent. The maternal surface showed ill-defined pale friable cotyledons. On microscopic examination, al-

though autolysis of fetal tissues was advanced, extensive areas of necrosis or of necrosis and mineralization (Kossa, Perl, and PAS were positive) were detected in the liver, brain, and myocardium. There was widespread necrotizing villitis with an accumulation of necrotic material and mononuclear cells or nuclear fragments in the intervillous spaces. Necrotizing granulomata containing giant cells and epithelioid cells were present in some villi. Round or oval bodies, often vacuolated and surrounded by a narrow clear zone, were seen in the cytoplasm of the fibroblasts of the chorion and of decidual cells (Figure 1). They were stained pink by hematoxylin and eosin, violet by PAS, and bright red by the method of Shorr.

#### Case 2

A 30-year-old white woman, gravida 4, para 2, had had 2 normal pregnancies and a blighted ovum between them. In August 1974 she became pregnant and mumps was diagnosed in the second month, after she had had contact with infected relatives. For this reason, she was submitted to prophylactic abortion in the third month of pregnancy. Macroscopic examination revealed numerous fragments of placental tissue intermingled with fetal parts. Microscopic examination of the lungs, kidneys, liver, myocardium, peripheral muscle, and bone showed no abnormalities. In the cytoplasm of some cortical adrenal cells, round inclusions stained pink by eosin, bright red by the method of Shorr, and PAS positive were observed (Figure 2). The placenta showed identical inclusions in the cytoplasm of degenerated fibroblasts and in the decidual cells.

#### Case 3

A 27-year-old white woman, gravida 4, para 3, had had her last menstrual period on October 30, 1974, and had an expected date of confinement of August 7, 1975. On November 18, through contact with 1 of her sons, she developed bilateral parotitis, which persisted for 12 days. A prophylactic abortion was performed in the 10th week of pregnancy. Macroscopic examination of the material obtained by curettage showed only fragments of villous tissue. Microscopy

revealed mononuclear perivascular and periglandular infiltration of endometrial stroma and protoplasmic inclusions in decidual cells, in cells of the decidual vessels, and in the stroma cells of the chorionic villi (Figure 3).

#### Comments

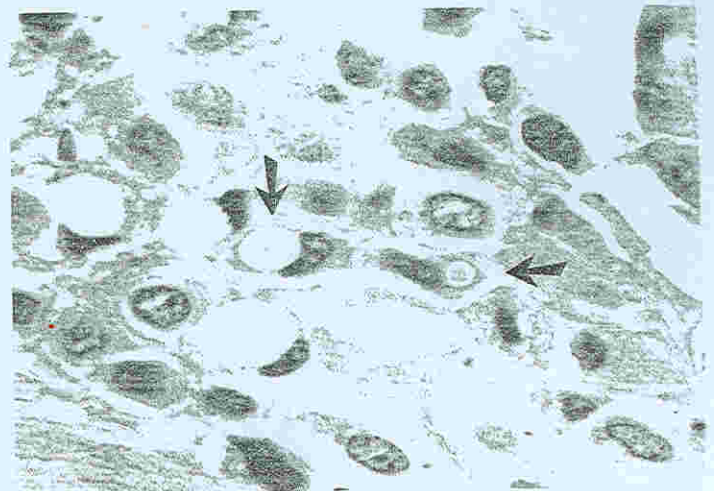
The authors' observations are based only on clinical and epidemiologic data of the virus disease of the pregnant women. A recent report, based on a review of the literature,<sup>9</sup> stresses that congenital mumps or even postnatally acquired perinatal mumps has rarely if ever been documented virologically or serologically.

The adverse effect of mumps infection upon the outcome of pregnancy has been manifested by fetal wastage closely related temporally to maternal infection.<sup>2</sup> In case 1, vaginal bleeding appeared 2 weeks after the maternal parotitis, and a severely macerated fetus was delivered 20 days after the clinical maternal manifestations.

The nature of the lethal effects of mumps early in gestation is not well understood.<sup>2,11</sup> In 2 of the present cases there was probably fetal involvement, evidenced by the presence of areas of visceral necrosis and mineralization (case 1) and of viral inclusions in some of the adrenal cortical cells (case 2). The fetal death (case 1) may have been a consequence of heavy involvement of chorionic villous tissue, mainly of the vascular fetal circuit associated with parenchymal degeneration and necrosis in vital organs.

Passage of mumps virus across the human placenta has not been rigorously documented,<sup>12-14</sup> although the experience of Aase et al,<sup>15</sup> based on the immunologic response of the fetus following intrauterine exposure to this virus, strongly pointed to this fact in human pathology. The same immunologic events have been observed in the subhuman primate, in which carefully

Figure 1. Case 1. Inclusions in the cytoplasm of decidual cells. (H & E,  $\times 680$ .)



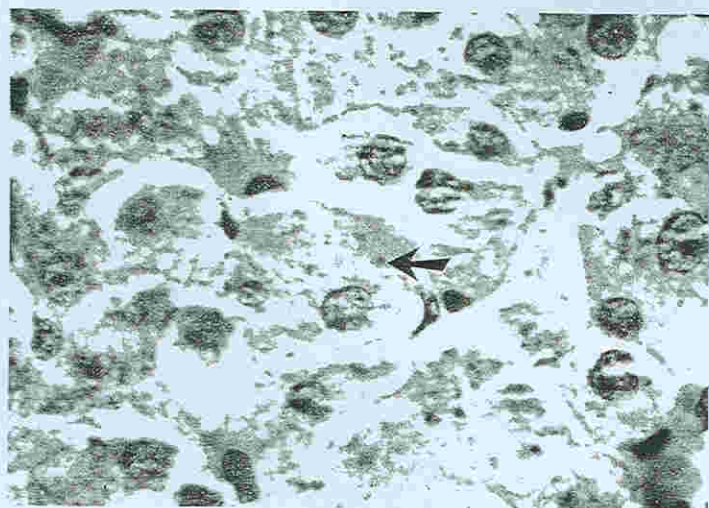


Figure 2. Case 2. Cytoplasmic inclusion in an adrenal cell. (H & E,  $\times 680$ .)

controlled experimental infection has indicated that mumps virus crosses the mammalian placenta.<sup>15</sup> Attenuated mumps virus was recovered from the placenta of a susceptible woman.<sup>16</sup>

Actually, the placenta has rarely been described in human gestational mumps,<sup>16</sup> and in some cases was even considered normal.<sup>17</sup> In case 1, the organ was severely compromised and had macroscopic and microscopic alterations. There was widespread necrotizing villitis and accumulation of necrotic material in the intervillous space. Important was the disruption of the vessels of the chorion, stem, and free villi. That these lesions preceded the fetal death is evidenced by the presence of old thrombi and vascular recanalization. These vascular lesions are identical to those described in congenital rubella<sup>18,19</sup> and cytomegalovirus intrauterine infection.<sup>20</sup> The type of villitis is similar to that described in chickenpox and smallpox—predominantly necrotic, sometimes granulomatous.<sup>21</sup>

In both cases of therapeutic abortion, it seems that

the lesions showing mononuclear periglandular and perivascular infiltration of endometrial stroma and the lesions of the chorionic villi with involvement of fetal vasculature are probably expressions of viral infection. Noteworthy is the presence of cytoplasmic inclusions in some cortical adrenal cells (case 2), in decidual cells, and in stroma cells of the chorionic villi (cases 2 and 3). These are identical to those that have been described in mumps.<sup>22</sup>

There are many case reports in the literature<sup>7,8,23-25</sup> associating maternal mumps infection with a wide variety of congenital anomalies, although the largest studies do not support the thesis that mumps virus is capable of producing a malformation.<sup>26</sup> In case 1, the maternal infection was manifested after the first trimester of pregnancy, a fact which per se was responsible for the absence of malformations; in case 2, the fetal organs were fragmented, thus preventing complete examination; in case 3, fetal structures were not present in the available material.

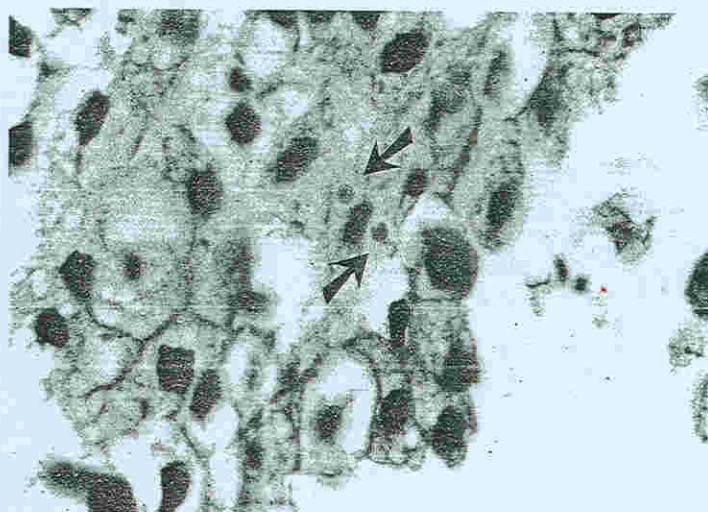


Figure 3. Case 3. Presence of 2 inclusions in a decidual cell. (H & E,  $\times 731$ .)

## References

1. Sever J, White LR: Intrauterine viral infections. *Annu Rev Med* 19:471, 1968
2. Siegel M, Fuerst HT: Low birth weight and maternal virus diseases. A prospective study of rubella, mumps, chickenpox and hepatitis. *JAMA* 197:680, 1966
3. Bowers D: Mumps during pregnancy. *West J Surg Obstet Gynecol* 61:72, 1953
4. Schwartz HA: Mumps in pregnancy. *Am J Obstet Gynecol* 60:875, 1950
5. Ylinen O, Jarvinen PA: Parotitis during pregnancy. *Acta Obstet Gynecol Scand* 32:121, 1953
6. Philip RN, Reinhard KR, Lackman DB: Observations on a mumps epidemic in a "virgin" population. *Am J Epidemiol* 69:91, 1959
7. Hyatt H: Relationship of maternal mumps to congenital defects and fetal deaths and to maternal morbidity and mortality. *Am Pract Dig Treat* 12:359, 1961
8. Swan C, Tostevin AL, Black GHB: Final observations on congenital defects in infants following infectious diseases during pregnancy with special reference to rubella. *Med J Aust* 2:889, 1946
9. Young N: Chickenpox, measles and mumps, *Infectious Diseases of the Fetus and Newborn Infant*. Edited by JW Remington, JO Klein. Philadelphia, Saunders, 1976, p 572
10. Herbst P, Multier AM, Jaldvka V: Morphologische Untersuchungen der Plazenta eiver an Parotitis Erkrankten Mutter. *Z Geburtshilfe Gynaekol* 174:187, 1970
11. Hanshaw JB, Dudgeon JA: Other possible pathogens in the fetus and newborn. *Viral Diseases of the Fetus and Newborn*. Major Problems in Clinical Pediatrics 17. Edited by AJ Schaeffer, M Markowitz. Philadelphia, Saunders, 1978, p 233
12. Chiba Y, Ogra PL, Nakao T: Transplacental mumps infection. *Am J Obstet Gynecol* 122:904, 1975
13. St Geme JW Jr, Van Pelt LI, Yamauchi T: Transplacental mumps virus infection. *Am J Obstet Gynecol* 125:280, 1976
14. Monif GRG: Maternal mumps infection during gestation: Observations on the progeny. *Am J Obstet Gynecol* 119:549, 1974
15. Aase JM, Noren GR, Reddy DV, et al: Mumps virus infection in pregnant women and the immunologic response of their offspring. *N Engl J Med* 286:1379, 1972
16. Yamauchi T, Wilson C, St Geme JW Jr: Transmission of live, attenuated mumps virus to the human placenta. *N Engl J Med* 29:710, 1974
17. Zardini DV: Eccezionale caso di parotite epidemica in neonato da madre convalescente della stessa malattia. *Lattente* 1:767, 1962
18. Tondury GT, Smith DW: Fetal rubella pathology. *J Pediatr* 68:867, 1966
19. St Geme JW Jr, Noren GR, Adams P Jr: Proposed embryopathic relation between mumps virus and primary endocardial fibroelastosis. *N Engl J Med* 275:339, 1966
20. Altshuler G, Russel P: The human placental vilitides: A review of chronic intrauterine infection, *Current Topics in Pathology*. Edited by F Huth et al. Berlin, Springer-Verlag, 1975, p 63
21. Garcia AGP: Fetal infection in chickenpox and alastrim with histopathologic study of placenta. *Pediatrics* 32:895, 1963
22. Johnson CD, Goodpasture EW: The histopathology of experimental mumps in the monkey, *Macacus rhesus*. *Am J Pathol* 12:495, 1936
23. Holowach J, Thurston DL, Becker B: Congenital defects in infants following mumps during pregnancy. A review of the literature and a report of chorioretinitis due to fetal infection. *J Pediatr* 50:689, 1957
24. Robertson GC, Williamson AP, Blattner RJ: Origin and development of lens cataracts in mumps infected chick embryos. *Am J Anat* 115:473, 1964
25. Siegel M: Congenital malformations following chickenpox, measles, mumps and hepatitis. Results of a cohort study. *JAMA* 226:1521, 1973
26. Manson MM, Logan WPD, Loy RM: Rubella and other virus infections during pregnancy. *Rep Public Health Med Subj no 101*. London, Her Majesty's Stationery Office, 1960. Cited in Hardy JB: *Viral infection in pregnancy: A review*. *Am J Obstet Gynecol* 93:1052, 1965

Address reprint requests to:  
*Aparecida G. P. Garcia, MD*  
*Department of Pathology*  
*Instituto Fernandes Figueira*  
*Avenida Ruy Barbosa, 716-22.250*  
*Rio de Janeiro, Brazil*

*Accepted for publication February 21, 1980.*

Copyright © 1980 by The American College of Obstetricians and Gynecologists.