

Case Report

Osteomyelitis Caused by *Paracoccidioides brasiliensis* in a Child from the Metropolitan Area of Rio de Janeiro

by Susie A. Nogueira, ^a Ana Lúcia Guedes, ^b Bodo Wanke, ^c Silvia Capella, ^d Karis Rodrigues, ^a Thalita F. Abreu, ^b José Carlos Morais, ^a and J.S. Lambert ^e

^a Hospital Universitário Clementino Fraga Filho, Serviço de Doenças Infecciosas e Parasitárias, University Federal do Rio de Janeiro, Brazil

^b Institute Puericultura e Pediatria Matargão, University Federal do Rio de Janeiro, Brazil

^c Fundação Oswaldo Cruz, Serviço de Micologia, Centro de Pesquisa Hospital Evandro Chagas, Brazil

^d Hospital Municipal Salgado Filho, Brazil

^e Institute of Human Virology, University of Maryland, USA

Summary

The authors describe a case of paracoccidioidomycosis in a 7-year-old girl from the city of Rio de Janeiro who initially presented to her physician with a lesion in her calcaneus which was misdiagnosed and treated as bacterial osteomyelitis. Later, cutaneous manifestations, lymph node enlargement, and hepatosplenomegaly developed and biopsy of the skin and cervical lymph nodes showed the fungus which was also present in the sputum. It is emphasized that *Paracoccidioides brasiliensis* can be the cause of bone lesions in endemic areas of Latin America and that response to treatment with amphotericin B is good.

Introduction

Paracoccidioidomycosis is a systemic fungal infection, endemic in Latin America, formerly known as South American blastomycosis. It is caused by a dimorphic fungus, *Paracoccidioides brasiliensis*, which is not uniformly distributed in endemic countries. The mycosis is mostly diagnosed among agricultural workers and/or residents of rural areas in humid tropical and subtropical regions of Latin America.¹⁻⁵

Paracoccidioidomycosis is classified based on its epidemiological, immunopathologic and clinical aspects into two polar forms: (1) the juvenile type or subacute form, observed mainly in patients under 30 years old, or in immunosuppressed individuals, in whom it presents with lymphatic/haematogenous dissemination and characteristic involvement of the phagocytic macrophage system and; (2) the adult type or chronic form, which affects mainly adults, who have a present or past history of working in a rural area, and is frequently associated with pulmonary and skin lesions.^{6,7}

Paracoccidioidomycosis is a rare disease in childhood (about 6 per cent of all cases)^{8,9} and usually has multisystem manifestations, often presenting with

involvement of the superficial and deep lymph nodes, skin, liver, and spleen. Bone lesions have been less frequently described, and are usually part of a multisystem clinical picture.⁸⁻¹²

The present report describes a case of the juvenile form of paracoccidioidomycosis in a 7-year-old child living in the metropolitan area of the city of Rio de Janeiro, Brazil, who sought medical care with complaints primarily related to a bone infection of the right foot which was initially diagnosed as a bacterial osteomyelitis.

Case Description

A 7-year-old girl, born and living in the metropolitan area of Rio de Janeiro, was admitted to a municipal hospital with complaints of pain in her right foot and difficulty with walking. According to her mother in November 1999 the child began to complain of pain in her foot. She was seen by an orthopaedic specialist, and prescribed anti-inflammatory drugs. In December 1999, with no improvement in the pain, new onset of fever, and increasing difficulty in walking, she was again seen by the orthopaedist who diagnosed an osteomyelitis, based on an X-ray of the right foot showing an osteolytic lesion of the calcaneus bone (Fig. 1). She was admitted to the paediatric ward (HMSF) and i.v. oxacillin and ceftazidime administered to treat presumptive bacterial aetiological agents, including *Staphylococcus aureus* and *Pseudomonas aeruginosa*.

Correspondence: Susie Andries Nogueira, Serviço de Doenças Infecciosas e Parasitárias, Hospital Universitário Clementino Fraga Filho, Av Brigadeiro Trompowski s/n - Ilha do Fundão, Rio de Janeiro - CEP: 21491.590. Tel: 55 21 5905252 Fax: 55 21 5905422 E-mail <susie@hucff.ufrj.br>.

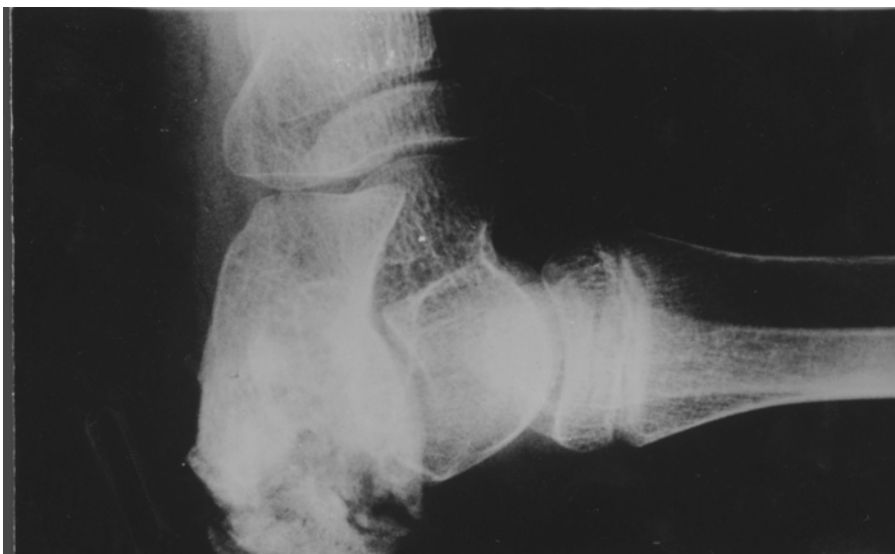

FIG. 1. Roentgenogram of right calcaneus with osteolytic lesion.

With no improvement after 10 days, incision and drainage was performed. The aspirated material was tested by microscopic examination and culture for bacteria, all of which were negative. She continued with fever, and a haemogram revealed a leukocytosis and an increased sedimentation rate, at which time oxacillin was stopped and vancomycin added. At this time cutaneous lesions similar to molluscum contagiosum, subcutaneous nodules, and hepato-

splenomegaly were noted on physical examination. She was transferred to the University Hospital (HUCFF) of the UFRJ in January 2000. On admission the subject was noted to have anaemia, malnutrition, fever, hepatosplenomegaly, subcutaneous nodules, and cervical lymph node enlargement.

Thoracic and abdominal CT scan demonstrated lymph nodes in the mediastinum and in the intra-abdominal region, as well as hepatosplenomegaly,

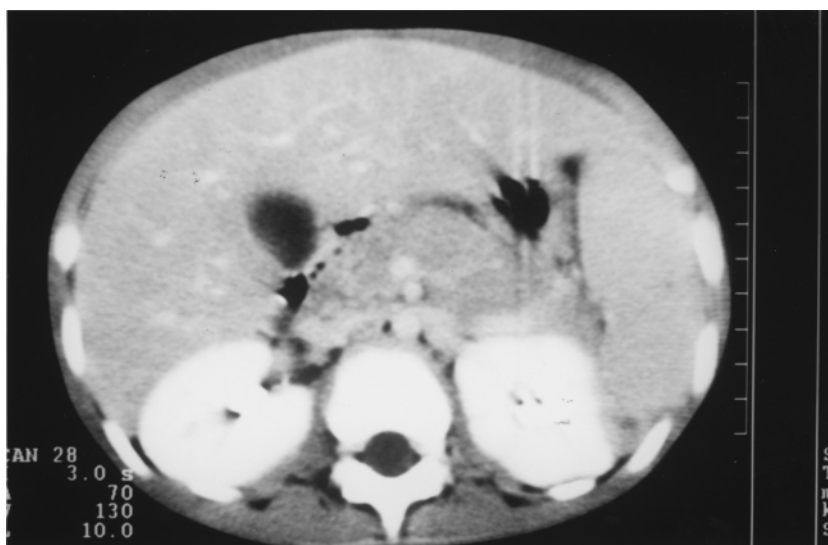

FIG. 2. CT scan of abdomen with enlargement of lymph nodes and hepatosplenomegaly.

but no pulmonary infiltrates were noted (Fig. 2). Bone scintillography detected lesions in the right calcaneus and multiple areas of the skull.

Haemoglobin was 9.2 g; haematocrit was 27.8 per cent, leukocytes were 37 200 cells, and sedimentation rate was 108 mm. Total serum protein was 8.00 g with an elevated gammaglobulin fraction.

Direct microscopy of potassium hydroxide preparations of sputum showed the typical tissue forms of *P. brasiliensis*. Biopsy of a cervical lymph node also demonstrated *P. brasiliensis* (Figs 3 and 4) in granuloma. Blood cultures were negative for bacteria and fungi.

Treatment with amphotericin B was subsequently initiated and following 1 month of therapy the patient began to gain weight, the lymph node enlargement and liver and spleen enlargement subsided, the subcutaneous nodules disappeared, and she was able to walk again without pain. She was discharged in February 2000 to the Pediatric Infectious Disease outpatient clinic (IPPMG) where she continued to receive i.v. amphotericin B every other day.

Discussion

This case illustrates an uncommon presentation of paracoccidioidomycosis: the presentation of a young child from the metropolitan area of the city of Rio de Janeiro without rural exposure, with an isolated bone lesion as the first clinical manifestation of the disease and the presence of the fungus in direct examination of sputum, without evidence of a parenchymal lesion in the lungs.

Paracoccidioidomycosis is a systemic mycosis of significance in Latin America and, its multisystem manifestations^{8,9,11,13} may be missed or misdiagnosed as some other infectious diseases.¹⁴ Due to its rarity in childhood, missing, misdiagnosing and delaying the diagnosis is common in paediatric practice. Gonçalves, *et al.*¹⁵ described 36 cases of paracoccidioidomycosis in children in the state of Rio de Janeiro, all of whom were resident in 15 rural counties scattered in the southwestern part of this state. Paracoccidioidomycosis occurs most commonly in adults with a past history of agricultural work, or those living in rural subtropical areas. In a para-coccidioidin skin test survey performed by Wanke¹⁶ in urban Rio de Janeiro, 2 per cent of children less than 12 years old had a positive reaction and 10 per cent of children in the second decade of life had a positive reaction. In contrast, another study performed in a rural area of the state of Rio de Janeiro showed 32.9 per cent positive skin test in children < 10 years old and 46.2 per cent in older children.¹⁷ Thus, although uncommon, infection by *P. brasiliensis* may occur in children living in metropolitan areas of Latin America,^{11,12} as happened with our young patient, reinforcing the fact that paracoccidioidomycosis should be part of the differential diagnosis even in 'urban dwellers'.

A study of 46 patients with paracoccidioidomycosis¹⁴ found greater clinical involvement of the reticuloendothelial system in younger individuals as compared to adults. According to Amstalden, *et al.*¹⁸ bone and joint infections are relatively uncommon. They described nine cases (mostly in adults) in whom osteoarticular manifestations were the only or

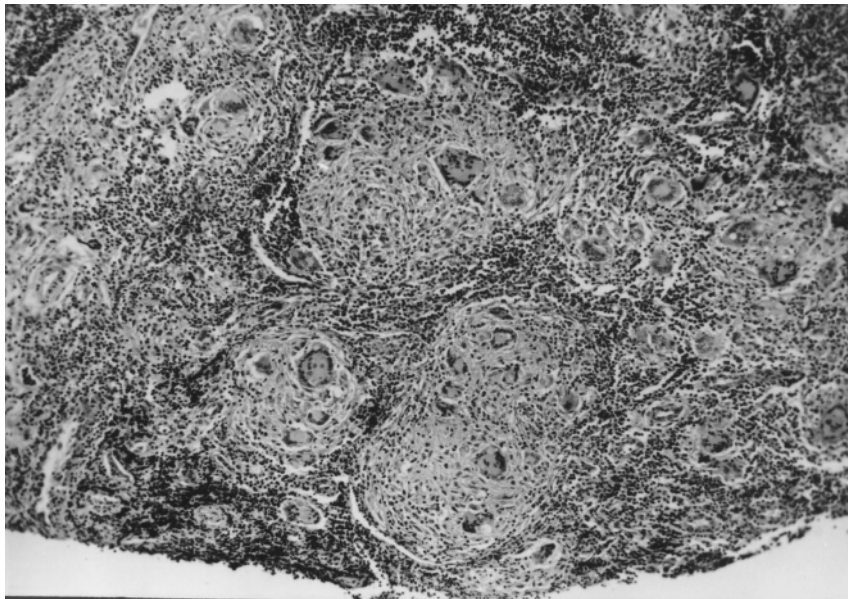


FIG. 3. Lymph node with non-necrotizing granuloma with large numbers of Langerhan's giant cells (HE, $\times 40$).

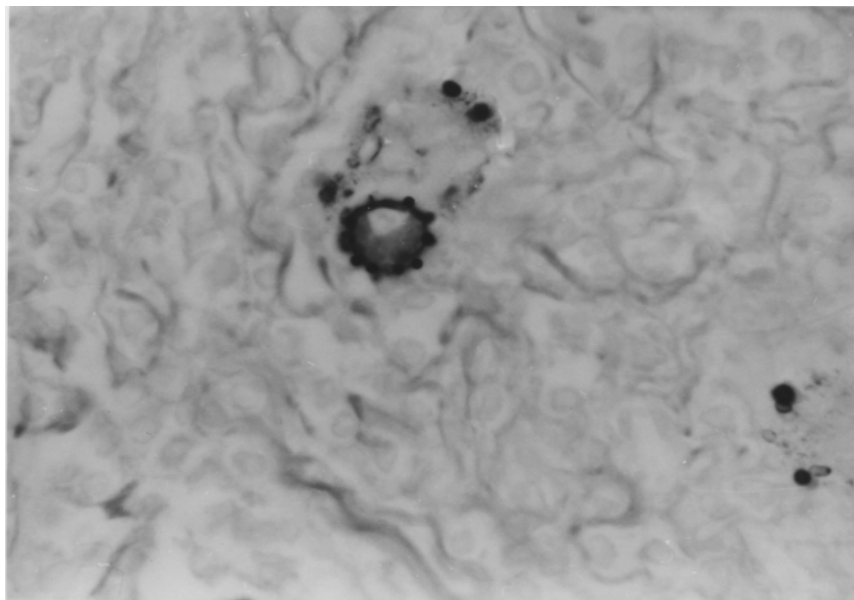


FIG. 4. Multiple small buds of the periphery of the fungus, characteristic of *Paracoccidioides brasiliensis*.

primary presentation of the disease; seven of these cases included joint involvement, primarily the large joints and long bones of the extremities.

Paracoccidioidomycosis of the bone is described radiographically as circumscribed, well delineated areas of lysis with or without a rim of sclerosis,^{8,10,18} and can occur in any bone but is usually seen in clavicles, ribs and scapulae. The differential diagnosis of such bone lesions includes chronic bacterial osteomyelitis, tuberculosis, lymphoma and osteosarcoma, and as the present case illustrates, in endemic areas for *P. brasiliensis* this systemic mycosis should also be included.

The isolated lesion first seen in the calcaneus bone in our patient led her physicians to treat her initially for a bacterial osteomyelitis, and treatment was targeted towards the principal aetiologic agents of this location (*S. aureus* and *P. aeruginosa*). If a fungal aetiology had been suspected initially, the material from the bone drainage could have demonstrated the *P. brasiliensis* tissue forms if adequately examined with potassium hydroxide preparations, as such lesions are usually teeming with organisms. It was only when other clinical features appeared that other possibilities were considered, and subsequent biopsy of the skin nodules and cervical lymph nodes established the correct aetiology. An early diagnosis and rapid initiation of appropriate treatment can achieve an excellent outcome with minimal complications; a wrong diagnosis can result in a fatal outcome.^{9,13}

Restrepo, *et al.*¹⁹ described three patients without

sign or symptoms of lung involvement, with normal chest X-rays, where *P. brasiliensis* was found in the sputum, similar to our patient. Such an observation reminds us of the pulmonary genesis of this mycosis, proof of the existence of a pulmonary primary infection (clinical or subclinical), even in patients with the juvenile form of the disease where the lung component may be obscured by predominant lymph node involvement.

In summary, paracoccidioidomycosis in children is not commonly described in the medical literature,^{8,11,20} and many clinicians have little experience with the juvenile form of this infection, which may lead to the mis-diagnosis of many cases. Paediatricians working in *P. brasiliensis* endemic areas should be aware of this rare but important presentation in children, and note that treatment with amphotericin B is very effective.^{3,7,21,22}

References

1. Negroni R. Paracoccidioidomycosis (South American blastomycosis, Lut's mycosis). *Int J Dermatol* 1993; 32: 847-59.
2. Londero AT, Melo IS. Paracoccidioidomycosis in childhood - a critical review. *Mycopathologia* 1983; 82: 49-55.
3. Sugar AM. Systemic fungal infections: diagnosis and treatment. 1: Paracoccidioidomycosis. *Infect Dis Clin North Am* 1988; 2: 913-29.
4. Wanke B, Londero AT. *Paracoccidioides brasiliensis*. In: Ajello L, Hay RJ (eds), *Medical Mycology*. Topley & Wilson's Microbiology and Microbial Infections, Vol. 4. Arnold, London, 1998.
5. Mangiaterra ML, Giusiano GE, Alonso JM, Gorodner JO. *Paracoccidioides brasiliensis* infection dans une subtropical

- region avec importants alteracion ambientale. *Bull Soc Pathol Exot* 1999; 92: 173–76.
6. Franco M, Montenegro MR, Mendes RP, Marques AS, Dillon NL, Mota NGS. Paracoccidioidomycosis: a recently proposed classification of its clinical forms. *Rev Soc Bras Med Trop* 1987; 20: 129–32.
 7. Wanke B. Micoses profundas. In: Schechter M, Marangoni D (eds), *Doenças infecciosas: conduta diagnóstica e terapêutica*, 2nd edn. Guanabara Koogan, Rio de Janeiro 1999.
 8. Rosario Filho NA, Telles Filho F, Costa O, Marinoni LP. Paracoccidioidomycosis in children with different skeletal involvement. *Rev Inst Med Trop São Paulo* 1985; 27: 337–40.
 9. Bittencourt AL, Andrade JA, Cendon FSP. Paracoccidioidomycosis in a four year old boy. *Mycopathologia* 1986; 93: 55–9.
 10. Lamego CB, Magalhães AA. Lesões osteolíticas. *Rev Ass Med Bras* 1971; 17: 105–06.
 11. Martins RM, Marques JL, Garcez IC, *et al.* Paracoccidioidomycose: relato de um caso em uma criança com 3 anos de idade com forma disseminada. *J Pediatr* 1986; 61: 319–22.
 12. Fonseca ERS, Pardo P, Severo LC. Paracoccidioidomycosis in children in Belém do Pará. *Rev Soc Bras Med Tropical* 1999; 32: 31–3.
 13. Bernard G, Orri NM, Marques HH, *et al.* Severe acute paracoccidioidomycosis in children. *Pediatr Infect Dis J* 1994; 13: 510–15.
 14. Giraldo R, Restrepo A, Gutierrez F, *et al.* Pathogenesis of paracoccidioidomycosis: a model based on the study of 46 patients. *Micopathologia* 1976; 58: 63–70.
 15. Gonçalves AR, Londero AT, Terra GM, Rosenbaum R, Abreu TF, Nogueira SA. Paracoccidioidomycosis in children in the state of Rio de Janeiro (Brazil). Geographic distribution and the study of reservarea. *Rev Inst Med Trop São Paulo* 1998; 40: 11–3.
 16. Wanke B. Inquérito intradérmico com paracoccidioidina em zona urbana do município do Rio de Janeiro. MSc Thesis, Universidade Federal do Rio de Janeiro, Brasil, 1976.
 17. Pedrosa PN. Paracoccidioidomycose: Inquérito intradérmico com paracoccidioidina em zona rural do estado do Rio de Janeiro. MSc Thesis, Universidade Federal do Rio de Janeiro, Brazil, 1976.
 18. Amstalden EM, Xavier R, Kattapuram SV, Bertolo MB, Swartz MN, Rosenberg AE. Paracoccidioidomycosis of bones and joints. A clinical, radiologic and pathologic study of 9 cases. *Medicine* 1996; 75: 213–25.
 19. Restrepo Moreno A, Trujillo M, Gomez I. Inapparent lung involvement in patients with the subacute juvenile type of paracoccidioidomycosis. *Rev Inst Med Trop São Paulo* 1989; 31: 18–22.
 20. Blotta MH, Mamoni RL, Oliveira SJ, *et al.* Endemic regions of Paracoccidioidomycosis in Brazil; a clinical and epidemiological study of 584 patients of southeast region study. *Am J Trop Med Hyg* 1999; 61: 390–94.
 21. Nogueira AS, Caiuby J, Vasconcelos V, *et al.* Paracoccidioidomycosis and tuberculosis in AIDS patients: report of two cases in Brazil. *Int J Infect Dis* 1998; 2: 168–72.
 22. Mendes RP, Negroni R, Arechavala A. Treatment and control of cure. In: Franco M, Lacaz CS, Restrepo-Moreno A, Del Negro G (eds), *Paracoccidioidomycosis*. CRC Press, Boca Raton, 1994; 373–92.

Checklist for Authors

Originality

Does the study make an original scientific contribution or new observation on the topic?

Usefulness

Are the findings likely to contribute to improved standards of care?

Would the findings have an impact on preventive/promotive care?

Design Features

Is the objective of the study clearly defined?

Is the study design appropriate for the objective?

Are the subjects for the study, their source, the method of recruitment as well as the inclusion/exclusion criteria defined?

Are the sampling methods likely to give rise to bias?

Is there a statement included about sample size?

Is the method for collection of data clearly described?

Are all laboratory methods used clearly referenced?

Are the study and comparison groups similar in all respects except for the topic of inquiry?

Is the response rate satisfactory?

Is the method of data collection likely to be open to bias?

If intervention has been used was the allocation random and blind?

Have the outcome measures been defined?

Are there any drop outs?

Was the method of outcome measurement open to bias?

Analysis and Presentation

Is the statistical procedure employed (including the software used) clearly stated?

Are the statistical tests used relevant?

Do the results adequately answer the research question?

Is the interpretation of results reasonable?

References

Are the references relevant to the study and up to date?

Are the references cited in the style required?

Ethics

Are the design and conduct of the study ethical?

Has the permission of the local ethical committee been sought and received?

Adapted from *Mother and Child Health: Research Methods* (www.tropej.oupjournals.org)