



## Case Report

Oleoma treated with oral colchicine: Report of two cases and review of the literature<sup>☆</sup>

Chan I. Lym, MD<sup>a</sup>, Fernanda Katsuren Nakasato, MD<sup>a</sup>, Mariana Campos Souza Menezes, MD<sup>a</sup>, Celso Tavares Sodré, MD<sup>a</sup>, Maria Kátia Gomes, MD, PhD<sup>a</sup>, Mônica Manela-Azulay, MD, PhD<sup>b</sup>, Tullia Cuzzi, MD, PhD<sup>b</sup>, Marcia Ramos-e-Silva, MD, PhD<sup>a,\*</sup>

<sup>a</sup> Sector of Dermatology, University Hospital and School of Medicine, Federal University of Rio de Janeiro, Brazil

<sup>b</sup> Sector of Pathology, University Hospital and School of Medicine, Federal University of Rio de Janeiro, Rio de Janeiro

## ARTICLE INFO

## Article history:

Received 3 October 2014

Received in revised form 30 November 2014

Accepted 15 December 2014

## Keywords:

Oleoma  
Colchicine  
Granuloma

## ABSTRACT

Oleoma is a non-allergic, foreign body type granulomatous reaction. It appears as response to oily exogenous substances injected to the dermis or subcutis for aesthetical purposes. Treatment for localized lesions is surgical. When they are multiple, steroids may show some result.

Newer therapeutic possibilities are being introduced and colchicine constitutes an alternative that is financially accessible and safe in moderate doses for certain dermatological illnesses. We present two women with oleoma on the legs treated with oral colchicine. This option was due to the extension of the clinical picture, which would not have a good surgical outcome. There was significant improvement in one patient, while we had to interrupt the medication in the other because of side effects.

© 2015 Published by Elsevier Inc. on behalf of Women's Dermatologic Society. This is an open access article under the CC BY-NC-ND license (<http://creativecommons.org/licenses/by-nc-nd/4.0/>).

## Introduction

Oleoma is characterized by a non-allergic, foreign body type granulomatous reaction, as response to injection of exogenous oily substances (mineral, vegetable, or animal oil) into the dermis or subcutaneous tissue, for aesthetic purposes (Magrin et al., 2010). The clinical picture is characterized by tumors or hardened plaques at the oily injection sites, sometimes with presence of fistules, purulent material secretion or ulcerations with release of oily material (Di Benedetto et al., 2002). Treatment is unsatisfactory and in most cases, surgical. New therapeutic possibilities, however, have been introduced. We report the cases of two women who were diagnosed as oleoma and treated with oral colchicine with very different outcomes.

## Case Reports

## Case 1

47-year-old black woman, born and living in Rio de Janeiro, laboratory technician, complaining of pruriginous lesions in the lower limbs evolving for about four years. The patient denied triggering factors and previous treatments. She referred to pain and edema during the pre-menstrual cycle.

In the past pathological history, there was hyperthyroidism treated with radioactive iodine 2 years before; cutaneous tuberculosis 31 years ago, with regular treatment and surgical excision of one of the submandibular masses. She denied other diseases and medication allergies. Her mother had hypothyroidism and a sister, vitiligo.

Four infiltrated hyperpigmented plaques were observed at examination, with centrifugal growth and yellowish surface in the medial region of the right lower limb, and infiltrated hyperchromic plaques, coalescent, slightly atrophic, in the medial region of the lower left limb (Figs. 1 and 2).

Histopathology presented granulomatous hypodermatitis with gigantocytic reaction of the foreign body type, constituting an oleoma-like picture (Figs. 3–5).

After histopathological result and further investigation, the patient referred having injected “a strengthening substance into the muscles” on the lateral face of lower limbs about 30 years ago, without being able to define the content or the quantity of the injected substance.

Treatment was initiated with 40 mg of prednisone per day, and in absence of response to the medication after four weeks; we chose to discontinue it and to begin with oral colchicine administration at 0.5 mg every 12 hours. Presently, it has been used for 7 months, with reduction of the hyperpigmentation and lesions softening. The patient is being followed up with regularly in the ambulatories of dermatology and endocrinology.

## Case 2

59-year-old black woman, born in Rio de Janeiro and living in Duque de Caxias, State of Rio de Janeiro, housewife. In 1989, she referred the onset of painful nodules, with slow evolution, in lower limbs

<sup>☆</sup> No conflicts and no funding.

\* Correspondence: Prof. Marcia Ramos-e-Silva, Rua Dona Mariana 143/C-32, 22280-020 Rio de Janeiro Brazil.

E-mail address: [ramos.e.silva@dermato.med.br](mailto:ramos.e.silva@dermato.med.br) (M. Ramos-e-Silva).

<http://dx.doi.org/10.1016/j.ijwd.2014.12.004>

2352-6475/© 2015 Published by Elsevier Inc. on behalf of Women's Dermatologic Society. This is an open access article under the CC BY-NC-ND license (<http://creativecommons.org/licenses/by-nc-nd/4.0/>).

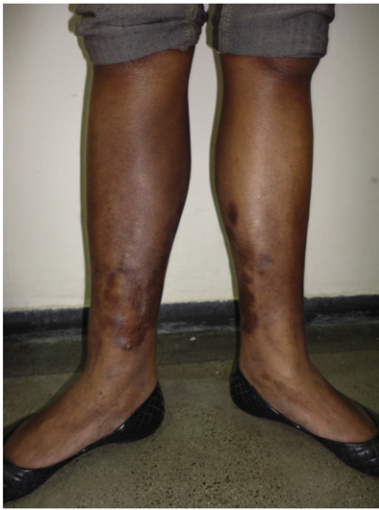

Fig. 1. Case 1 – Nodules and plaques in both legs.

with evolution of approximate six months (Fig. 6). She has localized scleroderma and Parry-Romberg syndrome.

She was submitted to three biopsies at different points in time for a nodular lesion in the thigh, that evidenced chronic inflammatory process with giantocytic reaction, involving rounded structures, in midst of connective tissue, compatible with inclusion of silicone. It was the same aspect as the one in Case 1.

When questioned she reported injection of liquid silicone in the bilateral inguinal region and thighs for aesthetic purposes.

The patient was submitted to partial excision by plastic surgery, without complications. Due to the extension of the lesions, we began a conservative treatment with colchicine at 0.5 mg per day, but after three months, we suspended the medication due to occurrence of very frequent diarrhea. Presently, she is under follow up in the dermatological and rheumatologic ambulatories.

## Discussion

Injection of oily substances into the body for increase of structures, filling out of imperfections or other aesthetic benefits is an old practice, used since the beginning of the 19th century (Gersuny, 1900; Quenu and Perol, 1948). The immediate aesthetic effects from the injection, such as alterations of contours and volume of certain parts of the body, stimulate such practice.

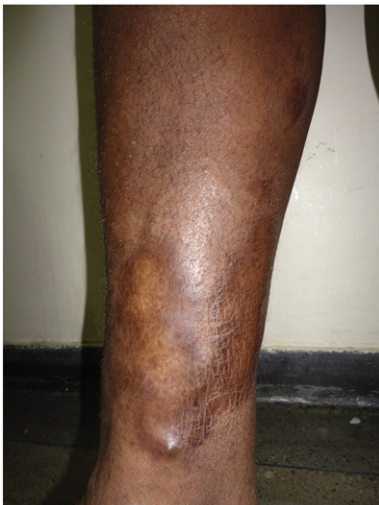

Fig. 2. Case 1 – Detail of one of the plaques.

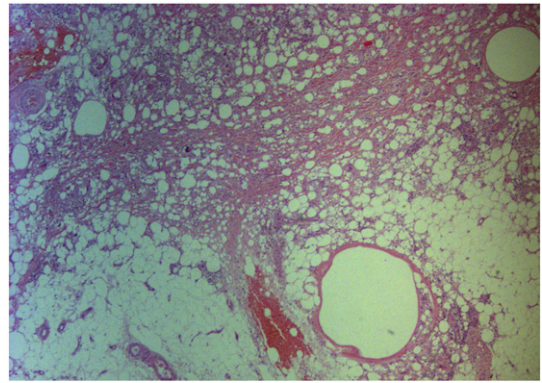


Fig. 3. Case 1 – Histopathology – inflammatory infiltrate located at the dermo-hypodermal junction associated to the presence of clear spaces of various sizes (HE, 40X).

There are reports in the literature of injections of several types of oils carried out in multiple parts of the body, such as paraffin in face and penis, mineral oil in breasts, sesame oil in upper members and chest region, Vaseline in the male and female genital region, besides unspecified oily substances (as in the case of one of our patients), and silicone (Eo et al., 2004; Georgieva et al., 2003; Iyengar et al., 2008; Uchida et al., 2007). The term paraffinoma (or lipogranuloma or sclerosing lipogranuloma) is used when the process involves injection of paraffin, while siliconoma refers to the injection of silicone (Pónyai et al., 2010).

Ramos-e-Silva et al. (Ramos-e-Silva et al., 2012) described a patient with oleoma in thighs and buttocks, as complication in mesotherapy with an unknown substance for cellulitis. This aesthetic procedure consists of multiple local injections into the dermis and subcutaneous tissue of small amounts of medications or other compounds, employed in the treatment of striae, painful syndromes or other illnesses. As happened with this patient and the two reported in the present article, women subjected to these procedures rarely volunteer the history of the use of foreign substances and only confirm it after the material is observed in the biopsies.

The clinical picture is characterized by tumors or hardened plaques at the oily injection sites, sometimes with presence of fistulas, purulent material secretion or ulcerations with release of oily material (Di Benedetto et al., 2002). Clinical presentation of our two patients were according to the description in literature, however without elimination of purulent or oily contents through the lesions. Clinical diagnosis was more difficult because the patients did not report the injections before the histopathologic analysis.

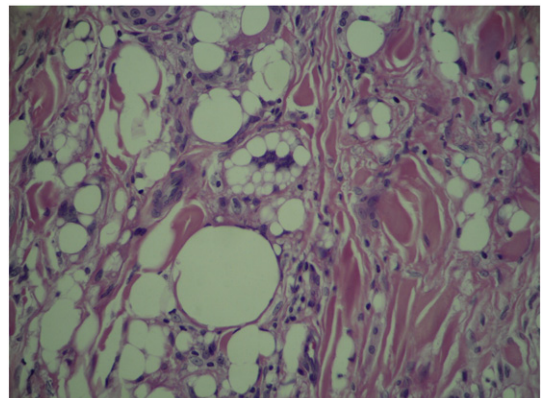
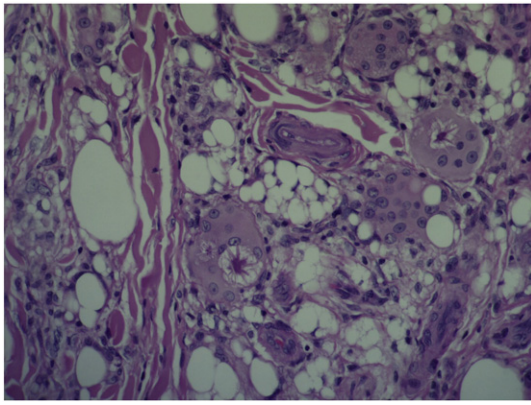


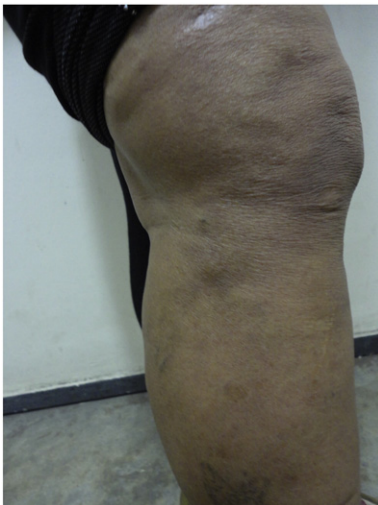Fig. 4. Case 1 – Histopathology – Detail of the inflammatory infiltrate and the clear spaces of various sizes (HE, 100X).



**Fig. 5.** Case 1 – Histopathology – Detail of the inflammatory infiltrate composed of macrophages and foreign body multinucleated giant cells, some with asteroid cuspules (HE, 100X).

One of the patients presented a belated onset of the lesions, 30 years after the procedure, while the other referred onset after only six months. There are reports of the latency period between the injection of the substance and the appearance of the symptoms for a few years up to 40 years. This timeframe is related to the amount of injected substance and the amount of adipose tissue present at the location that will trigger the reaction to the material (Magrin et al., 2010; Di Benedetto et al., 2002; Pónyai et al., 2010).

The human organism does not have enzymes capable of digesting oily substances. This entails a granulomatous reaction of the foreign body type when that type of substance is injected (Eo et al., 2004). Histopathologically, the destruction of subcutaneous fatty tissue is observed, with hyaline necrosis in the stromal septum, forming a typical “Swiss cheese pattern”, with cystic formations of diversified sizes corresponding to fat droplets surrounded by endothelial cells or giant cells, besides eosinophilic collagen tissue, macrophages containing phagocytes, and infiltrates of round cells around blood vessels. The quantity of material injected influences the initial reaction: high doses lead to an initial acute reaction, abating with time. Later, the reaction to the exogenous material becomes chronic fostering a macrophage reaction that fragments and stores the substance in the cytoplasm, in an attempt to metabolize it. The larger droplets are involved by multi-nucleated giant cells. After this process, fibroblasts of the stroma produce collagen fibers that separate the oily vacuoles (Di Benedetto et al., 2002; Georgieva et al., 2003; Pónyai et al., 2010). In presence of this chronicity of the acute



**Fig. 6.** Case 2 – Nodules and plaques in both legs.

reaction, the sclerosing lipogranuloma appears (Ackerman, 1978; Behar et al., 1993). Comparatively, paraffinoma presents dense inflammatory infiltrate and less multinucleated giant cells than siliconoma (Uchida et al., 2007; Schaumburg-Lever and Lever, 1995).

Complications may arise sooner or later, examples of which are an increase of cutaneous sensibility, inflammation, dyschromia, hard edema, sterile abscesses, lymphangitis, fibrosis with functional compromising of the affected organ, and migration of the oil, which is not only related to orthostatism, but to the presence of adipose tissue, that may occur in several directions (Magrin et al., 2010; Di Benedetto et al., 2002; Pónyai et al., 2010).

Surgical removal is considered the most effective treatment. There are reports of the use of topic and systemic steroid therapy, with partial efficacy, especially in cases where the treatment is postponed.

Uchida et al. (Uchida et al., 2007) described a case of facial paraffinoma that showed a moderate response after use of 20 mg prednisolone per day. Corticosteroids in general constitute the drug of choice in cases where resection of the entire material is not possible, due to its anti-inflammatory effect and immune modulator. Magrin et al. (Magrin et al., 2010) chose to use 500 mg of tetracycline every six hours, with posterior progressive dose reduction. Those authors decision was based on a report of a successful case of siliconoma with tetracycline, to avert the negative effects of a prolonged corticoid therapy. They referred to the anti-inflammatory and immune modulator effect of that medication, inhibiting neutrophil chemotaxis and granuloma formation.

Ramos-e-Silva et al. (Ramos-e-Silva et al., 2012) reported the treatment of a patient with oleoma from mesotherapy, initially with systemic corticoid (prednisone), whose gradual dose reduction led to the worsening of the pruritus and lesions. One year after beginning the symptoms, the patient still presented a worsening of the picture and very intense pruritus during attempts for reduction of the prednisone dose. Treatment with colchicine at 0.5 mg per day was started and, after a month, a partial regression of the lesions was observed. In three months, there was total disappearance of pruritus, only showing atrophic and hyperchromic cicatricial lesions at the sites of the former very unaesthetic lesions.

Colchicine has been used in several dermatological problems with good results, mainly in neutrophilic dermatosis, but without any formal indication for use in dermatology (Konda and Rao, 2010). Colchicine is a naturally toxic product whose active principle is extracted from seeds and stalks of *Colchicum autumnale* and other plants of the Colchiaceae family. It was isolated in 1820 by two French chemists, PS Pelletier and J Caventon. Referred to in literature as being an alkaloid, Konda and Rao (Konda and Rao, 2010) described it as a substance containing nitrogen in its structure, thus erroneously denominated alkaloid, although its biosynthetic forerunner, demecolcine, is an alkaloid. It was prescribed for the first time in 1763 by the Austrian physician Dr. Anton von Störck, for treatment of an acute gout crisis. It is believed that Benjamin Franklin introduced it to the US, being himself a patient of this affliction. Presently, there are two absolute non-dermatological indications for its use: acute gout crisis and familiar Mediterranean fever (Konda and Rao, 2010; Bibas et al., 2005).

Colchicine is capable of interrupting mitosis of plant and animal cells in vivo and in vitro, by connection of the tubulin dimers, diverting their transformation into micro tubulins. Without formation of mitotic fuses, there is no mitosis, because it is suspended in the metaphase, and cellular mobility is altered. The first affected cells are those with high rates of mitosis. It reduces mobility, adhesivity, and chemotaxis of polymorphonuclear cells, besides interfering in lysosomal degranulation. It alters the selectins and intercellular adhesion molecules, inhibiting the activation of T-lymphocytes and their adhesion to endothelial cells. Its action on adhesion molecules refers to modification of the quantity, quality of expression and topography of several cell glycoproteins. Another action is damaging cellular secretion of procollagen, suppressing the basal RNA level for collagen type 1, and to increase production of collagenase, promoting greater degrading of collagen tissue (Götting et al., 1999; Sabroe, 2003). Its immune suppressive action is entailed by the cell-mediated

immune responses, since secretion of immunoglobulin, production of interleucin-1 (IL-1), release of histamine and expression of HLA-DR are inhibited. Entailed by its capacity for connecting to proteins, in vitro suppression of parathormone and insulin release and displacement of melanocytes is observed (Konda and Rao, 2010; Bibas et al., 2005). Much controversy exists in literature about whether these effects occur in the clinically employed doses.

The main collateral effects from its use refer to the gastrointestinal tract, through inhibition of mitosis in a mucosa with rapid cell turnover and increase of the intestinal motility by neural mechanisms. This triggers nausea, vomiting, abdominal pain, and diarrhea. With chronic use, the results may be suppression of bone marrow with agranulocytosis, thrombocytopenia, and aplastic anemia. Also subject to occur are: myopathy, neuropathy, urticaria, epidermal toxic necrolysis, late cutaneous porphyria, azoospermia, and alopecia following 2 to 3 months of therapy, involving face, armpits and the pubic region (Konda and Rao, 2010; Bibas et al., 2005).

Colchicine also presents other pharmacological effects, such as alteration of the neuromuscular function, increase of response to sympathicomimetic agents, contraction of blood vessels, hypertension by central vasomotor stimulation, depression of the respiratory center, and reduction of body temperature, among others (Roberts and Marrow, 2001).

Konda and Rao (Konda and Rao, 2010) allege that colchicine constitutes a financially accessible and safe alternative in moderate doses for certain dermatological diseases, such in the initial phase of leukocytoclastic vasculitis, Sweet's syndrome, and aphthous ulcer, comparable to several other immune suppressive agents, even if not being the frontline for such illnesses. The option with oral colchicine in our patients was due to the extension of the clinical picture, which would not lead to a satisfactory surgical result. One of the patients reported an improvement in the hardened aspect of the lesions and reduction of hyperchromia, and continues the treatment. The other patient presented intolerance and the use of the medication had to be interrupted.

## Conclusion

Oleoma is increasing all over the world due to the indiscriminate growth of aesthetic procedures. Besides surgical removal of the lesion

or lesions, and the use of oral steroids, colchicine is another option that may help some selected patients.

## References

- Ackerman AB (1978). Panniculitis. In: Ackerman AB, editor. *Histologic diagnosis of inflammatory skin diseases. A method by pattern analysis* Philadelphia: Lea & Febiger; 1978. p. 779–823.
- Behar TA, Anderson EE, Barwick WJ, Mohler JL (1993). Sclerosing lipogranulomatosis: a case report of scrotal injection of automobile transmission fluid review of subcutaneous injection of oils. *Plast Reconstr Surg* 1993;91:352–61 [PMID: 8430154].
- Bibas R, Gaspar NK, Ramos-e-Silva M (2005). Colchicine for dermatologic diseases. *J Drugs Dermatol* 2005;4:196–204 [PMID: 15776777].
- Di Benedetto G, Pierangeli M, Scalise A, Bertani A (2002). Paraffin oil injection in the body: an obsolete and destructive procedure. *Ann Plast Surg* 2002;49:391–6 [PMID: 12370645].
- Eo SR, Kim KS, Kim DY, Lee SY, Cho BH (2004). Paraffinoma of the labia. *Plast Reconstr Surg* 2004;113:1885–7 [PMID: 15114185].
- Georgieva J, Assaf C, Steinhoff M, Treudler R, Orfanos CE, Geilen CC (2003). Bodybuilder oleoma. *Br J Dermatol* 2003;149:1289–90 [PMID: 14674912].
- Gersuny R (1900). Über eine subcutane Prothese. *Z Heilkund* 1900;1:199.
- Götting C, Sollberg S, Kuhn J, et al (1999). Serum xylosyltransferase: a new biological marker of the sclerotic process in systemic sclerosis. *J Invest Dermatol* 1999;112: 919–24 [PMID: 10383739].
- Iyengar R, Saint-Cyr M, Gokaslan T, Rao R (2008). Breast paraffinoma. *Breast J* 2008;14: 504–5 [PMID: 18657137].
- Konda C, Rao AG (2010). Colchicine in dermatology. *Indian J Dermatol Venereol Leprol* 2010;76:201–5 [PMID: 20228563].
- Magrin PF, de Oliveira Ribeiro C, Quevedo Filho LP, Barbosa Durães SM, Rocha MC (2010). Oleoma: A case report with good response to tetracycline. *Dermatol Online J* 2010;16(7) [PMID: 21062601].
- Pónyai K, Marschalkó M, Hársing J, Ostorházy E, Kelemen Z, Nyirády P, et al (2010). Paraffinoma. *J Dtsch Dermatol Ges* 2010;8:686–8 [PMID: 20337771].
- Quenu J, Perol E (1948). Paraffinomas of the penis. *Int Abstr Surg* 1948;86:174.
- Ramos-e-Silva M, Pereira AL, Ramos-e-Silva S, Piñeiro-Maceira J (2012). Oleoma: rare complication of mesotherapy for cellulite. *Int J Dermatol* 2012;51:162–7 [PMID: 22250624].
- Roberts LJ, Marrow JD (2001). Analgesic-antipyretic and anti-inflammatory agents. In: Hardman JG, Limbird LE, Gilman AG, editors. *Goodman and Gilman pharmacological basis of therapeutics*. 10th ed. Dallas: McGraw Hill; 2001. p. 687–731.
- Sabroe R (2003). Colchicine. In: Wakelin SH, Maibach HI, editors. *Handbook of systemic drug treatment in dermatology*. London: Manson; 2003. p. 105.
- Schaumburg-Lever G, Lever WF (1995). *Inflammatory disease due to physical agents and foreign substances. Histopathology of the skin* 6th ed. Philadelphia: Lippincott; 1995 222.
- Uchida Y, Yoshii N, Kubo H, Kanzaki T, Kanekura T (2007). Facial paraffinoma after cosmetic paraffin injection. *J Dermatol* 2007;34:798–800 [PMID: 17973825].