

Torus Palatinus Osteonecrosis Related to Bisphosphonate: A Case Report

Mariana Godinho^a Fabio Barbosa^c Felipe Andrade^a Tullia Cuzzi^b
Marcia Ramos-e-Silva^a

Sectors of ^aDermatology and ^bPathology, University Hospital and School of Medicine, Federal University of Rio de Janeiro, and ^cFabio Barbosa Dermatology Clinic, Rio de Janeiro, Brazil

Key Words

Osteonecrosis · Torus palatinus · Bisphosphonates

Abstract

Introduction: Osteonecrosis of the palate is a rare condition which is even rarer when occurring on a torus palatinus and associated with bisphosphonate (BP). **Case Presentation:** We report an uncommon case of osteonecrosis of a torus palatinus. Our patient was a 67-year-old white female who presented with a painful intraoral ulcer associated with necrotic bone tissue of her torus palatinus, due to the chronic use of alendronate. **Conclusion:** We point out the possible causative relationship of BPs and osteonecrosis on torus growth. It is very important to know that torus palatinus and the use of BPs are risk factors for osteonecrosis of the maxilla.

Introduction

Osteonecrosis of the jaw is characterized by exposure and devitalization of the mandible or maxilla bone for more than 8 weeks, and since 2003, several cases associated with bisphosphonates (BPs) have been reported [1, 2]. Around 0.1% of patients undergoing treatment develop osteonecrosis of the jaw [3]. BPs are inhibitors of osteoclastic action, capable of changing the bone resorption process [1]. They are usually used to treat osteoporosis, Paget's bone disease, multiple myeloma, bone metastases of the breast and prostate cancer, and malignant hypercalcemia [2–4].

Marcia Ramos-e-Silva, MD, PhD
Rua Dona Mariana 143/C-32
Rio de Janeiro 22280-020 (Brazil)
E-Mail ramos.e.silva@dermato.med.br

Osteonecrosis of the jaw associated with this class of drugs occurs in patients who are presently undergoing or have undergone previous therapy and with no previous radiotherapy of the jaw [1, 2, 5, 6]. It can occur on the mandible or maxilla, but the incidence on the mandible is around 2 times greater. Osteonecrosis of the jaw typically appears as an intraoral lesion with areas of exposed yellow-white hard bone with smooth or ragged borders [1, 3, 5]. When the osteonecrosis is associated with BPs, signs and symptoms are usually the same: irregular ulcers of the mucosa with bone exposure of the mandible or maxilla, pain or swelling of the affected region, and/or suppuration [6]. Bone exposure is not always present as there are some reports only with mucosal ulcers. Pain is a frequent complaint [6].

Although the diagnosis is made clinically, imaging studies are useful to assess the extent of the process, provide the diagnosis in early stages, exclude other diseases, and diagnose possible complications such as pathological fractures and necrosis [4]. Biopsy is not necessary, but in a review of osteonecrosis cases associated with the use of oral BPs, all biopsies performed showed bone necrosis [4]. The physiopathology of the process remains uncertain [1, 2, 5]. The risk factors are exposure to BPs, individual potency of BPs, means of medication administration, time of exposure, and accumulated dosage. Most cases related to oral BPs are due to alendronate [5]. The risk increases with dosage and treatment duration [2]. Dental procedures also constitute a major risk factor associated with this process, though it has been reported to occur spontaneously and after traumas [2, 3, 7]. Smoking and comorbidities may also contribute to the development of osteonecrosis [5]. Additionally, there are reports of associated genetic factors [5, 8].

Tori are bone exostoses located and circumscribed on the cortical bone surface, covered by a thin and poorly vascularized mucosa [3, 9]. They are lesions in the oral cavity due to protuberant bone growths known as hyperostosis, which in the oral cavity are found on the palate and mandible. On the palate they are called torus palatinus and in the jaw area torus mandibularis [10]. They are usually asymptomatic, but frequent ulcerations, difficulty in chewing and speaking can occur. More females than males are affected and the incidence varies between 12.3 and 26.9% [3, 9]. Such lesions are believed to have a genetic etiology. Torus palatinus, the most common exostosis of the maxillofacial skeleton, is usually located at the median line of the hard palate [9, 11].

A case of torus palatinus osteonecrosis associated with the use of alendronate is presented herein.

Case Presentation

A 67-year-old white female reported spontaneous detachment of a bone fragment from her palate. She mentioned that there was a painful ulcer which had appeared 2 months before, with no response to bicarbonate, triamcinolone, and tetracyclines. There was improvement of the local pain after expelling the bone fragment. She had a 16-year history of osteoporosis treated with oral calcium 600 mg/day and alendronate 70 mg/week for the past 6 years. There were no other comorbidities such as diabetes or hypertension. She did not use any other medication and presented with torus palatinus and torus mandibularis not knowing when it started.

The clinical examination of the palate revealed a depression (approximately 0.5 cm) in the mucosal tissue on the left side of a torus palatinus (approximately 2.5 cm) without bone exposure and signs of inflammation or infection (fig. 1). CT imaging showed prominent exostosis (torus) on the medial portion of the hard palate with discontinuity of the cortical

bone on the left side (red arrow, [fig. 2](#), [fig. 3](#)), while the histopathology of the bone fragment confirmed necrotic bone tissue ([fig. 4](#)). With this clinical report, history of BP use, physical examination, imaging and histopathology, the diagnostic conclusion was BP-related osteonecrosis of the torus palatinus. The patient's medication was discontinued and she was referred to a maxillofacial surgeon for the surgical removal of the torus palatinus.

Discussion

Cases of osteonecrosis of the torus palatinus, a type of maxillary exostosis, have rarely been reported. The presence of a torus palatinus is the main precipitating factor leading to osteonecrosis, and the fragility of the mucosa covering the torus palatinus may allow minor trauma to expose the susceptible bone [\[3\]](#).

There are rare reported cases of osteonecrosis of a torus palatinus associated with the use of BPs in the literature and our patient fits the epidemiological profile of the majority of patients affected by osteonecrosis by BPs: female and over 60 years of age [\[7\]](#). In the reported case, the osteonecrosis occurred after the use of oral medication for 6 years, which carries an incidence that is lower than that of intravenous medication [\[1, 5\]](#). Besides, it was associated with the use of alendronate, the main oral BP related to osteonecrosis, at a dosage of 70 mg/week, also reported in the literature [\[1, 7\]](#). Discontinuation of BP treatment is the immediate recommended procedure, although there were no data indicating the improvement of the process with this measure [\[6\]](#).

The incidence of osteonecrosis varies from 1 in 20,000 to 1 in 100,000 with the use of oral BPs [\[2, 6, 7\]](#). There was no history of previous dental intervention, associated comorbidities, or the use of other medications such as corticosteroids, which have also been reported as predisposing factors in the process [\[3, 7\]](#). The event occurred spontaneously or after some minor trauma, since the patient reported constant trauma from forks and spoons to the torus lesion which was very prominent in the oral cavity. The most important factor in the reported case was the existence of the torus palatinus, already reported in the literature as a risk factor for osteonecrosis associated with BPs [\[3\]](#).

The mucosa over the torus is fragile and easily injured, exposing the bone tissue susceptible to the process [\[3\]](#). There is no established standard treatment, especially in the rare reported cases of torus palatinus osteonecrosis. Our approach was to withdraw her medication, in addition to the indication for surgical removal of the torus, to prevent further trauma to the torus mucosa predisposing the beginning of a new process. The patient was also advised to keep good oral hygiene. Since the surgery, the patient has been receiving multidisciplinary care by the dentist and maxillofacial surgeon for 1 year, without recurrence of the condition.

Conclusion

It is important to mention this serious side effect caused by this class of drugs (BPs) as well as the importance of the torus palatinus as a risk factor for osteonecrosis of the maxillofacial skeleton. BPs are widely used in a vast number of diseases with high incidence, such as osteoporosis and myeloma. Also osteonecroses of the jaw, including the ones originating on the torus, must be listed among other significant oral manifestations of drug reactions.

References

- 1 Pazianas M: Osteonecrosis of the jaw and the role of macrophages. *J Natl Cancer Inst* 2011;103:232–240.
- 2 Rizzoli R, Burlet N, Cahall D, et al: Osteonecrosis of the jaw and bisphosphonate treatment for osteoporosis. *Bone* 2008;42:841–847.
- 3 Goldman ML, Denduluri N, Berman AW, et al: A novel case of bisphosphonate-related osteonecrosis of the torus palatinus in a patient with metastatic breast cancer. *Oncology* 2006;71:306–398.
- 4 Morag Y, Morag-Hezroni M, Jamadar DA, et al: Bisphosphonate-related osteonecrosis of the jaw: a pictorial review. *Radiographics* 2009;29:1971–1984.
- 5 EMEA/CHMP/291125/2009: CHMP assessment report on bisphosphonates and osteonecrosis of the jaw. European Medicines Agency. http://www.ema.europa.eu/docs/en_GB/document_library/Report/2010/01/WC500051428.pdf (accessed November 27, 2012).
- 6 Khosla S, Burr D, Cauley J, et al: Bisphosphonate-associated osteonecrosis of the jaw: report of a task force of the American Society for Bone and Mineral Research. *J Bone Miner Res* 2007;22:1479–1491.
- 7 Pazianas M, Miller P, Blumentals WA, Bernal M, Kothawala P: A review of the literature on osteonecrosis of the jaw in patients with osteoporosis treated with oral bisphosphonates: prevalence, risk factors, and clinical characteristics. *Clin Ther* 2007;29:1548–1558.
- 8 Terpos E, Dimopoulos MA: Genetic predisposition for the development of ONJ. *Blood* 2008;112:2596–2597.
- 9 García-García AS, Martínez-González JM, Gómez-Font R, Soto-Rivadeneira A, Oviedo-Roldán L: Current status of the torus palatinus and torus mandibularis. *Med Oral Patol Oral Cir Bucal* 2010;15:e353–e360.
- 10 Meza Flores JL: Torus palatinus and torus mandibularis (in Spanish). *Rev Gastroenterol Peru* 2004;24:343–348.
- 11 Yildiz E, Deniz M, Ceyhan O: Prevalence of torus palatinus in Turkish schoolchildren. *Surg Radiol Anat* 2005;27:368–371.

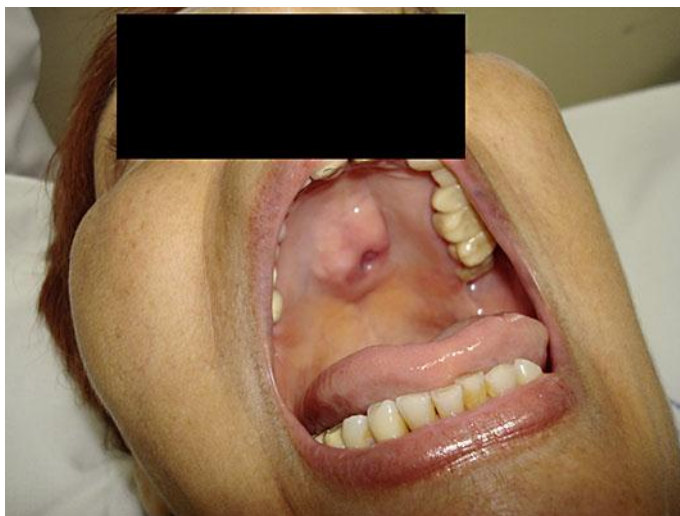

Fig. 1. Depression on the mucosal tissue on the left side of the torus palatinus; no bone exposure or signs of inflammation and/or infection.

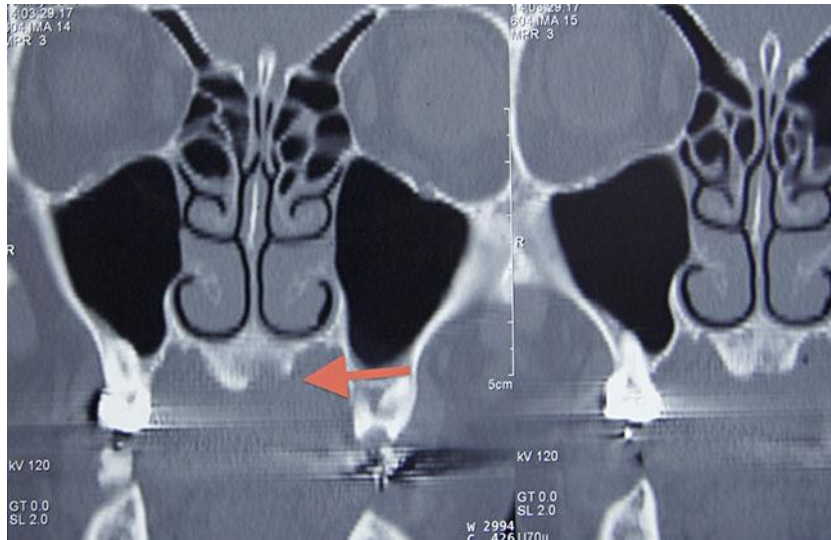


Fig. 2. CT imaging (frontal view) – prominent exostosis (torus) on the hard palate (red arrow).

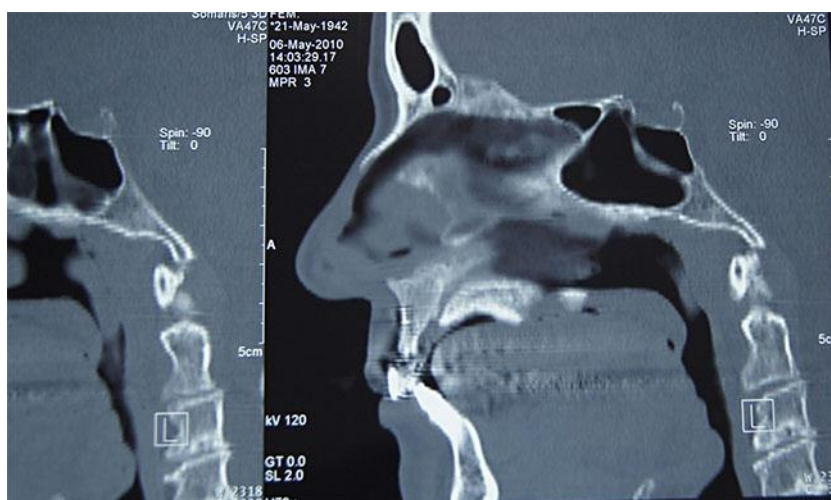

Fig. 3. CT imaging (lateral view) – prominent exostosis (torus) on the medial portion of the hard palate with discontinuity of the cortical bone.

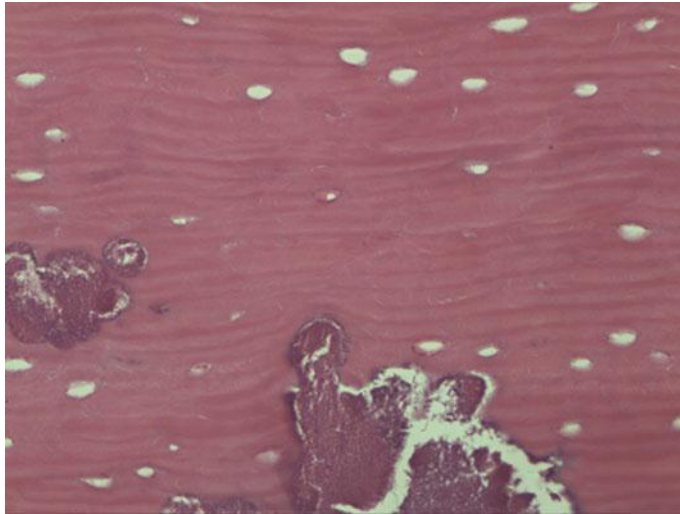


Fig. 4. Histopathology of the bone fragment – necrotic bone tissue. HE. ×40.