

Spitzoid Melanoma: Dermoscopic Report and Diagnostic Discussion

**Gabriella Campos-do-Carmo¹, Marcia Ramos-e-Silva¹,
Mayra Carrijo Rochael², Tullia Cuzzi³**

¹Sector of Dermatology, Federal University of Rio de Janeiro, Rio de Janeiro;

²Department of Pathology, Fluminense Federal University, Niterói; ³Sector of Pathology, Federal University of Rio de Janeiro, Rio de Janeiro, Brazil

Corresponding author:

Professor Marcia Ramos-e-Silva, MD, PhD
Rua Dona Mariana 143/C-32
22280-020 Rio de Janeiro
Brazil
ramos.e.silva@dermato.med.br

Received: January 20, 2010

Accepted: October 12, 2010

SUMMARY We present a case of a 16-year-old young man who came for a dermatologic appointment due to acne. He presented a pigmented asymptomatic lesion on the back of his right thigh. Dermoscopic examination revealed uncommon aspects, highly suspect of nodular melanoma, in particular a blue-whitish veil, striae and asymmetric globules. The lesion was promptly removed and the material referred for histopathologic examination. Microscopic findings showed an atypical spitzoid tumor, compatible with spitzoid melanoma. In this report, the importance of dermoscopy as an auxiliary method in the early diagnosis of cutaneous melanomas is emphasized. Its daily use by the dermatologist is an important tool in the decision-making process in cases of urgent removal of suspect lesions.

KEY WORDS: dermoscopy, melanoma, Spitz nevus

INTRODUCTION

Dermoscopy allows for distinction of melanocytic from non-melanocytic lesions and, as in the case presented below, also finding the parameters that indicate benignity and suspicion or high suspicion of the diagnosis of a cutaneous melanoma. The presence of a pigmented network, globules or radial streaks indicates proliferation of melanocytes and/or nevic cells, and the intralesional disposition of these structures will suggest suspicion or not. Asymmetric lesions in terms of color and structure are more suspect, and additional malignancy criteria are the presence of a blue-whitish veil and pseudopods (1).

Melanoma is rare in infants and is difficult to diagnose, even by experienced dermatopathologists.

Reed's nevus is also an uncommon entity, but with preference for that age group. The characteristics of this benign melanocytic lesion on dermoscopy are most typically a starburst pattern with symmetric striae in the lesion periphery and an amorphous central black area (2,3). In this situation, total and timely removal of the lesion can be planned and performed in a less traumatic way and without urgency. However, when highly suspicious dermoscopic criteria are found, such as striae and/or asymmetric pseudopods, blue-whitish veil and irregular globules, prompt histopathologic confirmation is mandatory. The spitzoid variant of melanoma is rare. Sometimes, definitive diagnosis can only be established upon the development of metastases (4,5).

CASE REPORT

A 16-year-old man, white (Fitzpatrick phototype III) presented a hyperpigmented, well-delimited, asymptomatic papular lesion with smooth surface on the back of right thigh. The lesion size was 0.4 cm, with an approximate evolution of 8 months (Figs. 1 and 2).

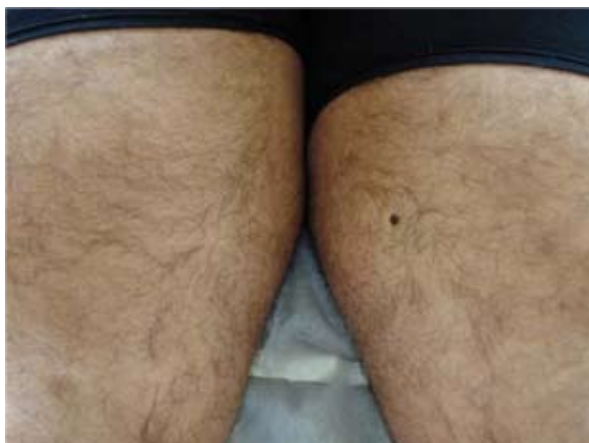

Figure 1. Hyperpigmented papule on the right posterior thigh.

At clinical examination, the possible diagnoses were Reed's nevus and compound melanocytic nevus. Dermoscopic examination revealed brown and gray-bluish globules disposed asymmetrically, partly covered by a blue-whitish veil, and the presence of some asymmetric peripheral striae (Fig. 3).

These findings were highly indicative of cutaneous melanoma and Reed's nevus considering the main differential diagnosis. Surgical excision was carried out after dermoscopic examination, with the possible diagnoses discussed with the

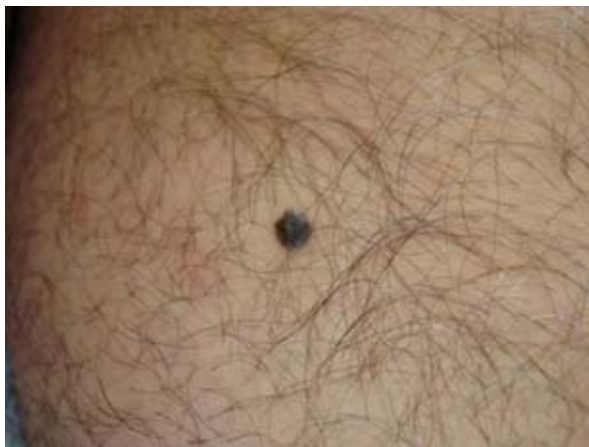

Figure 2. Close up of the hyperpigmented lesion.

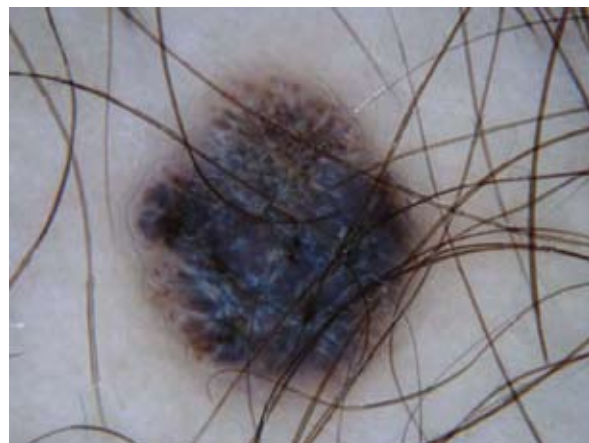

Figure 3. Dermoscopy showing the presence of asymmetric brown and bluish-grey globules, whitish-blue veil and asymmetric striae. (Heine Delta, X20-10).

patient's parents, who were informed of the urgency of the unexpected procedure. Histologic sections revealed an asymmetric compound lesion (Fig. 4).

There was hyperkeratosis, hypergranulosis and irregular acanthosis. Along the dermoepidermal junction, there was proliferation of melanocytes disposed in large nests. The majority of the cells were epithelioid with plenty of eosinophilic cytoplasm and large nuclei, vesicular or hyperchromatic, with prominent nucleoli (Fig. 5).

Some were provided with multiple nuclei while others displayed a delicate melanic pigmentation. There was pleomorphism and anisocariosis. Eosinophilic hyaline corpuscles (Kamino bodies) were observed (Fig. 6).

Focally, the junctional nests showed a perpendicular disposition, while in other areas, proliferation was continuous with horizontally disposed

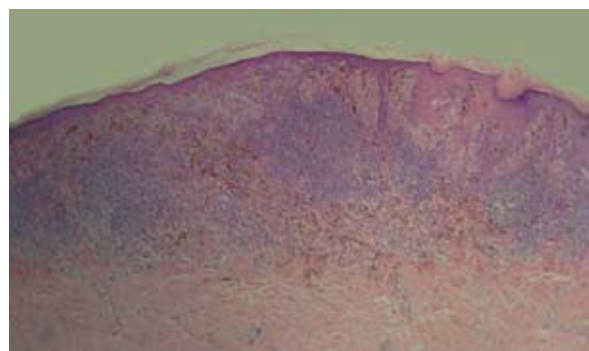


Figure 4. Epidermal changes and melanocytic proliferation more evident on the right side of the figure. A dense inflammatory infiltrate obscures the intradermal component of the lesion. (HE, X20)

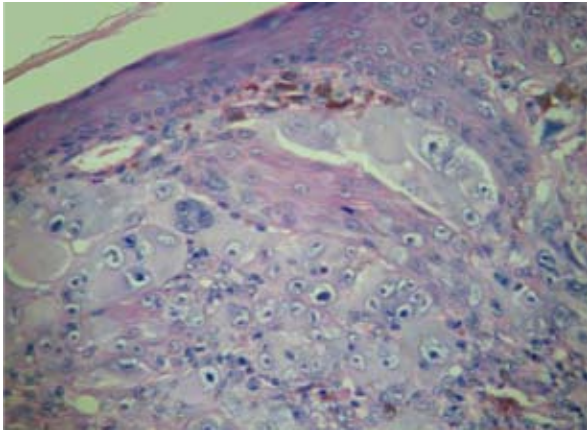


Figure 5. Cytomorphology of epithelioid melanocytes. (HE, X100)

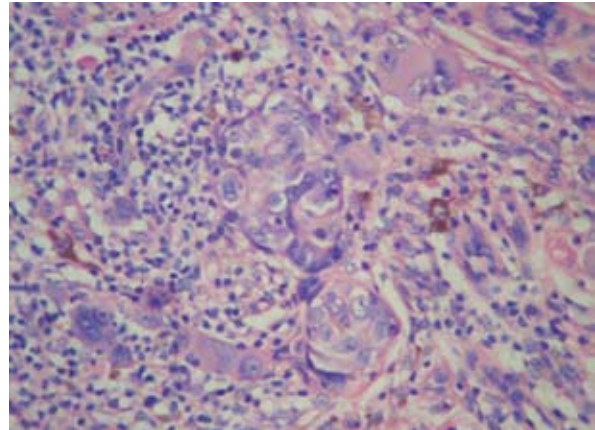


Figure 7. Dermal nests with some isolated and ganglion-like multinucleated cells. (HE, X100)

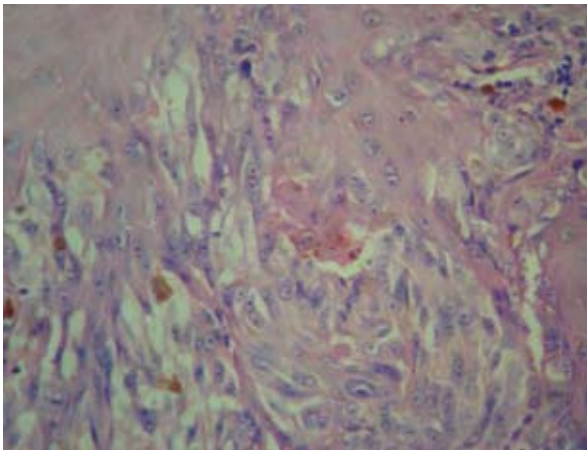


Figure 6. Kamino bodies. (HE, X100)

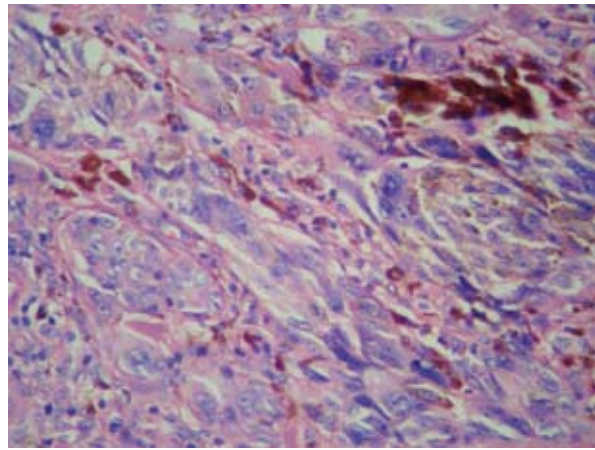


Figure 8. Fascicles of cells with irregular and hyperchromatic nuclei in the dermal tissue. (HE, X100)

cells. Pagetoid dissemination was not exuberant. Similar cells, some with 'ganglionic' aspect, were observed in the dermis, and large epithelioid and fusiform cells with angular and hyperchromatic nuclei, isolated and with short fascicles were also present in the depth of the intradermal component (Fig. 7 and 8).

Figures of mitosis, some atypical, were observed especially in the junctional component of the lesion (Fig. 9).

The histopathologic diagnosis was atypical spitzoid compound lesion compatible with spitzoid melanoma, corresponding to Clark level III lesion, Breslow thickness 1.25 mm. Subsequent studies of the expansion of surgical excision limits and sentinel lymph node did not show residual or metastatic lesion, respectively. Laboratory examinations were normal and after seven-month follow-up the patient was free from the disease. There

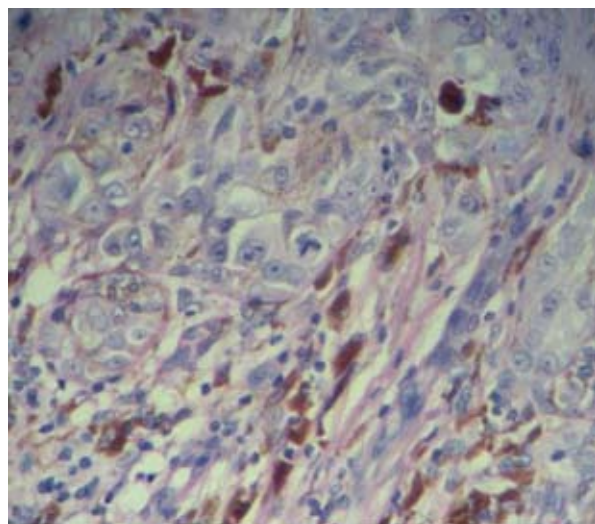


Figure 9. Atypical mitoses. (HE, X100)

was no previous family history of melanoma, or other risk factors.

COMMENT

The most suggestive dermoscopic characteristics of Reed's nevus or pigmented Spitz nevus are radial streaks and/or pseudopods symmetrically disposed in the lesion periphery, a starburst pattern, and globules symmetrically disposed in the lesion periphery, a globular pattern. In a study of 83 cases of Spitz nevus, asymmetry was a major marker of histopathologic atypia and its presence was higher when dermoscopic correlation was carried out (3). However, the presence of criteria of melanocytic spitzoid lesion with asymmetry and/or additional criteria for suspicion of malignancy (such as blue-whitish veil) raises the possibility of atypical Spitz nevus and opens discussion of spitzoid melanoma (2).

The risk of melanoma before age 15 is extremely low, about 1 *per* million. The spitzoid variant is rare in all age groups, and always a difficult diagnosis to be given (6,7).

Spitzoid melanoma is a malignant melanocytic proliferation of fusiform (spindle) cells, epithelioid cells, or a mix of both. Histology is characterized by an asymmetric architecture and irregular borders. The thickness of the lesion normally reaches the dermal-subcutaneous junction and the growth pattern is solid, without interposition of collagen fibers. Atypical figures of mitosis are usually present in the depth of the lesion, with the possible presence of nuclear and nucleolar pleomorphism that is absent in Spitz nevus. Immunohistochemistry does not contribute significantly to definitive diagnosis. Metastases in lymph nodes are frequent in spitzoid melanoma and rare in case of Spitz nevus (3,7,8).

A recent study showed an increased and diffuse expression of the CD99 marker in spitzoid melanomas, which is absent or focal in Spitz nevus; however, more studies and case histories are needed to validate the use of this nonspecific tumor marker of the melanocytic lineage in the differentiation of spitzoid tumors (9).

Some recent genetic studies point to a distinct pathogenesis of spitzoid melanomas, since it appears that there are no mutations in the B-RAF or N-RAS gene, as in most cutaneous melanomas (10-12). Some evolutionary progression theories of spitzoid tumors exist and are being studied at the level of molecular biology; although still inconclusive, they may help understand spitzoid lesions as well as melanocytic neoplasias in general in the future (13).

The management of spitzoid melanomas must follow that of melanomas in general, as well as the sentinel lymph node, with the positivity of the latter possibly related to some atypical histopathologic characteristics of spitzoid tumors, such as incomplete maturation, two or more dermal mitoses per mm², and deep dermal mitoses (14). In relation to the prognosis, spitzoid melanoma does not differ from other melanomas. There are cases in which evolution is better, especially in younger patients, but with long-term follow-up, the risk of metastasis is greater and can emerge one decade after the diagnosis (15).

The present case was documented by dermoscopy and the histopathologic diagnosis was established independently by two experienced dermatopathologists.

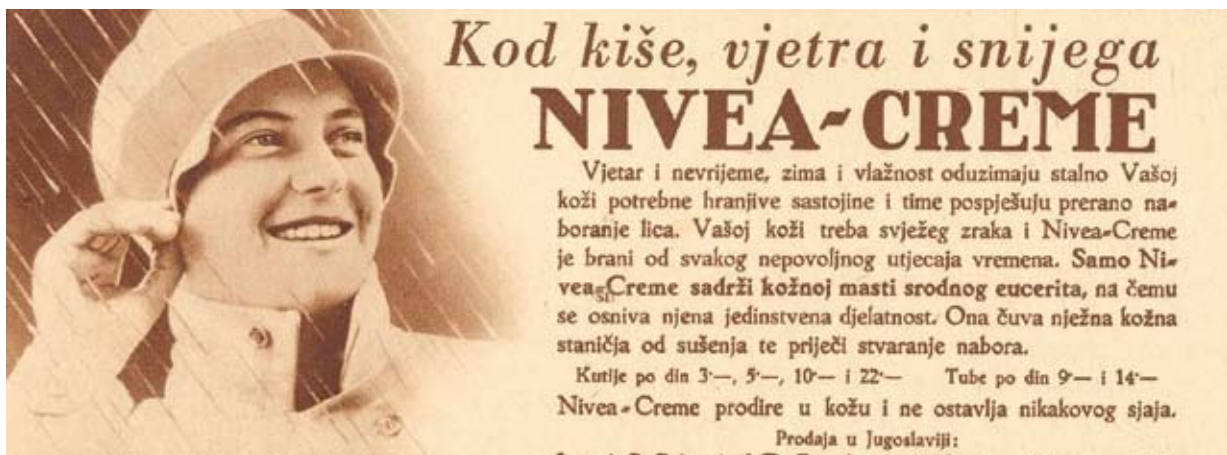CONCLUSION

The purpose of this single case report is to emphasize the relevance of dermoscopic examination to establish a more precise clinical diagnosis of several cutaneous conditions, in particular melanocytic lesions. We stress the importance of this examination at the time of the clinicopathologic correlation, since dermoscopic findings highly indicative of benignity or malignancy may orient the pathologist's definitive diagnosis at the microscope, and sometimes being an encouragement for additional histologic cuts or more cautious observation.

References

1. Campos-do-Carmo G, Ramos-e-Silva M. Dermoscopy: basic concepts. *Int J Dermatol* 2008;47:712-9.
2. Argenziano G, Scalvenzi M, Staibano S, Brunetti B, Piccolo D, Delfino M, *et al.* Dermoscopic pitfalls in differentiating pigmented Spitz naevi from cutaneous melanomas. *Br J Dermatol* 1999;141:788-93.
3. Ferrara G, Argenziano G, Soyer HP, Chimenti S, Di Blasi A, Pellacani G, *et al.* The spectrum of Spitz nevi: a clinicopathologic study of 83 cases. *Arch Dermatol* 2005;141:1381-7.
4. van Dijk MC, Aben KK, van Hees F, Klaasen A, Blokx WA, Kiemeneij LA, *et al.* Expert review remains important in the histopathological diagnosis of cutaneous melanocytic lesions. *Histopathology* 2008;52:139-46.
5. de Giorgi V, Sestini S, Massi D, Papi F, Lotti T. Atypical Spitz tumour: a 'chameleon' lesion. *Clin Exp Dermatol* 2008;33:309-11.

6. Handfield-Jones SE, Smith NP. Malignant melanoma in childhood. *Br J Dermatol* 1996;134:607-16.
7. Gurbuz Y, Apaydin R, Muezzinoğlu B, Buyukbabani N. A current dilemma in histopathology: atypical Spitz tumor or spitzoid melanoma? *Pediatr Dermatol* 2002;19:99-102.
8. Top H, Aygit AC, Bas S, Yalcin O. Spitzoid melanoma in childhood. *Eur J Dermatol* 2006;16:276-80.
9. King MS, Porchia SJ, Hiatt KM. Differentiating spitzoid melanomas from Spitz nevi through CD99 expression. *J Cutan Pathol* 2007;34:576-80.
10. van Dijk MC, Bernsen MR, Ruitter DJ. Analysis of mutations in B-RAF, N-RAS, and H-RAS genes in the differential diagnosis of Spitz nevus and spitzoid melanoma. *Am J Surg Pathol* 2005;29:1145-51.
11. Lee DA, Cohen JA, Twaddell WS, Palacios G, Gill M, Levit E, *et al.* Are all melanomas the same? Spitzoid melanoma is a distinct subtype of melanoma. *Cancer* 2006;106:907-13.
12. Da Forno PD, Fletcher A, Pringle JH, Saldanha GS. Understanding spitzoid tumours: new insights from molecular pathology. *Br J Dermatol* 2008;158:4-14.
13. Takata M, Lin J, Takayanagi S, Suzuki T, An-sai S, Kimura T, *et al.* Genetic and epigenetic alterations in the differential diagnosis of malignant melanoma and spitzoid lesion. *Br J Dermatol* 2007;156:1287-94.
14. Murali R, Sharma RN, Thompson JF, Stretch JR, Lee CS, McCarthy SW, *et al.* Sentinel lymph node biopsy in histologically ambiguous melanocytic tumors with spitzoid features (so-called atypical spitzoid tumors). *Ann Surg Oncol* 2008;15:302-9.
15. Fabrizi G, Massi G. Spitzoid malignant melanoma in teenagers: an entity with no better prognosis than that of other forms of melanoma. *Histopathology* 2001;38:448-53.



By rain, wind and snow – use Nivea cream; year 1935.
(From the collection of Mr. Zlatko Puntijar)