

LANKESTERELLA ALENCARI N. SP.,  
A TOXOPLASMA-LIKE ORGANISM IN THE  
CENTRAL NERVOUS SYSTEM OF AMPHIBIA  
(PROTOZOA, SPOROZOA)<sup>1\*</sup>

**SYLVIO CELSO GONÇALVES DA COSTA \*\***

and

**NEIZE DE MOURA PEREIRA \*\***

Instituto Oswaldo Cruz, Rio de Janeiro, GB.

(With 38 figures)

The classification of the *Toxoplasma*-like parasites found in tissues of cold blooded vertebrates has been uncertain for many years. It is also noteworthy that the occurrence of parasitic protozoon in the nervous system is extremely rare. **Doflein** (1898) reported a microsporidan protozoon within the sensory and spinal ganglia of a fish, *Lophius piscatorius*. Recently **Marquet & Sebel** (1970) found a protozoon in the Central Nervous System of the lung-fish *Polypterus enlicheri*.

Altho *Toxoplasma*-like invasion of *Amphibia* central nervous system was observed some years ago by **Alencar** (1957), this problem remains incompletely known. **Alencar** found body cysts in the CNS of the toad *Bufo marinus* and of the frog *Leptodactylus ocellatus*. Recently **Stensaas & col.** (1967) found an intra-axonal protozoon in the spinal cord of the toad *Bufo arenarum* but the problem of its identity remains to be solved.

Our work, referring *Toxoplasma*-like parasites of cold-blooded animals really began some years ago for the fact that the existence of naturally acquired toxoplasmosis in poikilothermic vertebrate, tho sometimes claimed, has always been regarded to doubtful identifications based on morphological aspects.

---

<sup>1</sup> Received for publication July, the 8th, 1971.

\* The present work was supported by Instituto Oswaldo Cruz and by a research grant from Conselho Nacional de Pesquisas.

\*\* Department of Zoology, Instituto Oswaldo Cruz, CP 926, GB - Brazil.

This is specially remarkable when we study the hemoparasites of amphibia because they present tissue forms that resemble to *Toxoplasma* (Costa & col. 1970a, 1970b, 1971). To be sure that an organism closely resembling *Toxoplasma* belongs really to this genus successful infection of white-mice — a highly susceptible host — is always necessary.

Since Stone & Manwell (1969) had obtained successful experimental toxoplasmosis in cold-blooded animals by their maintenance under warmer conditions we have tried the inoculation of *T. gondii* of human origin in *Leptodactylus*.

The present study was undertaken in order to determine the specific status of the parasite that we had included in previous report (Costa & col. 1971) as a member of subphylum *Sporozoa* in the genus *Lankesterella*. The new specie is named in honour of Dr. Alexandre Alencar who first observed this parasite in the CNS of *L. ocellatus*.

Finally, it is interesting to note that *Leptodactylus ocellatus* is very common in Brazil, being employed with frequency in researches in the field of Physiology, Biochemistry and Bacteriology is good animal for work in Zoology classes as well.

## MATERIALS AND METHODS

Frogs and toads were captured in some localities in Brazil during 1964-1971 and all of them had the blood examined to determine the presence of haematozoa.

Blood smears were air-dried and stained with May-Grünwald-Giemsa. Parasites were examined under the Olympus Filar micrometer eyepiece. Brain and others tissue organs were taken out and fixed in formalin 10% or Carnoy, but in some cases the organs were not available.

Sectioned tissues, between 8-10 micra thick, were ordinarily stained with Delafield's Hematoxilin-Eosin, and in some cases we employed Giemsa adapted for tissues. Impressions and sectioned tissues were also stained by Methyl-Green Pyronin, Feulgen and PAS for best characterization of the cysts.

Attempt of experimental toxoplasmosis infection in *L. ocellatus* was accomplished by intra-peritoneal inoculation with heavily infected ascitic fluid from mice in which a *Toxoplasma* strain was routinely maintained. This strain was isolated by Dr. Nery-Guimarães from a human case, who kindly furnished it for our work. Only frogs without blood parasites were chosen for inoculations and maintained

at room temperature (that in Rio de Janeiro was about 34°C-39°C in the opportunity), for the observations of ascitic fluid after 30 minutes, 2 and 5 hours.

These frogs were observed daily, all of them after 7 days being killed and its tissues were also examined after the usual stain methods.

Brain of frogs with bodies cysts was also inoculated by intraperitoneal inoculation in white mouse and the mice inoculated were also examined for microscopic evidence of *Toxoplasma*. Human brain of a toxoplasmosis case was sectioned and stained by silver carbonate method but PAS was used in this case too. The measuring of *Toxoplasma gondii* was done with PAS stain.

## RESULTS

Table I lists the number of *Leptodactylus ocellatus* examined for haematozoa as well as the presence or absence of parasites and the localities from which they were taken.

A total of 100 amphibia belonging to different species were examined but only 22 brains have been investigated. It is also worth noting that only *Leptodactylus ocellatus* have presented cysts in the Central Nervous System. Since two types of cysts included in the *Toxoplasma*-like complex were found in the CNS of *Amphibia* (Costa & col., 1970a, b and 1971), the correlations between the occurrence of several haematozoa and these cysts are reported in Table II.

The localities from which non-infected amphibia were taken are reported in Table III.

TABLE I

*Leptodactylus ocellatus* examined for blood Sporozoa.

Localities	Number examined	Number negative	<i>Lankes- terella</i>	<i>Hepato- zoon leptoda- ctyli</i>	<i>Haemo- barto- nella</i>	<i>T. rota- torium</i>	<i>Dacty- losoma</i>	<i>Cyta- moeba</i>
1. <i>Guanabara</i>								
. Manguinhos	27	12	5	3	2	11	—	1
. Cordovil	2	—	1	—	—	—	—	1
. Bangu	1	—	1	1	—	—	—	—
. Campo Grande	1	1	—	—	—	—	—	—
2. <i>Est. do Rio de Janeiro</i>								
. Rio Bonito	20	3	5	5	4	8	7	5
. Terezópolis	1	—	—	—	—	1	—	—
. S. João de Meriti	2	—	1	1	1	2	—	—
. Niterói	7	—	4	2	2	6	2	5
. Alcântara	6	1	3	—	3	4	2	4
. Cantagalo	5	—	1	2	3	2	1	3
. Caxias	1	—	—	1	—	1	—	—
. Guandu	2	1	1	—	1	—	—	1
TOTAL	75	18	22	15	16	35	12	20

TABLE II  
CORRELATIONS BETWEEN BLOOD PARASITES AND CYSTS IN DIFFERENT  
ORGANS OF *L. OCELLATUS* (H = CYSTS OF *HEPATOZOON*; L = CYSTS OF  
*LANKESTERELLA*).

Blood infection	Number of cases	Tissue infection				
		liver	spleen	kidney	lung	brain
<i>Lankesterella</i> (with other parasites like: <i>T. rotatorium</i> , <i>Haemobartonella</i> , <i>Cytamoeba</i> )	11	—	—	—	—	(L)
Only <i>Lankesterella</i>	3	—	—	—	—	(L)
<i>Lankesterella</i> and <i>Hepatozoon</i> (with other parasites like: <i>T. rotatorium</i> , <i>Haemobartonella</i> , <i>Cytamoeba</i> , too)	5	(H)	(H)	—	(H)	(H) *
<i>Lankesterella</i> and <i>Dactylosoma</i> (with other parasites like: <i>T. rotatorium</i> , <i>Cytamoeba</i> and <i>Haemobartonella</i> )	3	—	—	—	—	(L)

\* Only one case presented *Hepatozoon* in brain.

TABLE III

## COLLECTION SITES OF AMPHIBIA NEGATIVE FOR SPOROZOA IN BLOOD

Amphibia	Localities
<i>Atelopus moreirae</i> Mir. Ribeiro, 1920	Itatiaia (Rio de Janeiro)
<i>Bufo crucifer</i> Wied	Teresópolis (Rio de Janeiro)
<i>Bufo marinus</i> (L. 1758)	Alto da Boa Vista, Quintino Bocaiúva, Padre Miguel and Vista Alegre (Guanabara); Friburgo (Rio de Janeiro) and Utinga (Pará)
<i>Hyla faber</i> Wied, 1821	Teresópolis (Rio de Janeiro)
<i>Hyla langsdorffi</i> Dum & Bibr., 1841	Higienópolis (Guanabara)
<i>Hyla albomarginata</i> Spix, 1824	Manguinhos (Guanabara)

*Lankesterella alencari* n. sp.

**Blood Forms:** we have observed in the peripheral blood an erythrocytic stage whose elongated forms have 10,79  $\mu$  long by 2,4-3,3  $\mu$  wide; the nucleus measures 0,8  $\mu$ .

The parasite presents a slightly blue cytoplasm, when stained by Giemsa and has the nuclear material in strands (Figs. 15, 22) or granules (Fig. 21).

A vacuole was visible at one pole sometimes. Granules were usually present in the cytoplasm and stained very lightly with Giemsa (Fig. 20), but no hemozoin pigment was observed in these parasites. Both intracorpuseular and extra-cellular parasites were found in the peripheral circulation, but free forms were found too. Free forms measure from 10, 79  $\mu$  to 12,4  $\mu$  long and from 1,2  $\mu$  to 1,6  $\mu$  broad. The nucleus is vesicular and measures about 1,6  $\mu$ .

Some intracorpuseular forms present a cytoplasm that stain fairly heavy with Giemsa (Fig. 21) and can form a  $\wedge$  — shape and in this case seems to be inclosed in a sheath. The nucleus is small and vesicular (Figs. 14a and c, 19, 23). The forms measure 12  $\mu$  long by 2,5  $\mu$  wide.

Occasionally, the parasites infect young erythrocytes, white cells and large lymphocytes, multiple infection of these cells may also occur. In one frog heavily infected we found schizogony in white cells (Fig. 10, 24 and 25).

**Effect in host cell:** the parasitized host cell and nucleus were not greatly altered. Sometimes we observe hypertrophied erythrocytes and in figure 26 the erythrocyte lost its nucleus.

**Tissue Forms:** Four out of 20 specimens of *L. ocellatus* taken at Rio Bonito, Estado do Rio, with a *Lankesterella*-like parasite in the peripheral blood had an infection of its brains by a very characteristic cyst.

The cysts had an approximately 49,03  $\mu$  length when they were stained with Delafield's Hematoxylin or Giemsa adapted for tissues.

Cyst wall is thin, without compartment and it is both argyrophilic and PAS positive (Figs. 8, 9, 32). Sometimes we found several cysts together (Figs. 9, 33) and this may simulate compartments. We have the opportunity to observe a cyst with a nucleated wall. The cysts are formed by the parasitism in the neurones (Figs. 31, 35, 36 and 38) or in the glia cells and occur either in grey matter or in white matter (see Alencar, 1957 fig. 6). There is no cellular reaction in the brain to the presence of these cysts.

The cyst contains large numbers of crescentic toxoplasma-like organisms each of which contains a glycogen granule, approximately the size of the nucleus, that we can see clearly with PAS (Figs 8, 9, 30 and 32). These organisms have a small, delicated structure, measuring  $4 \times 1,7 \mu$ , with a subterminal nucleus measuring  $1,5 \mu$  in diameter. The nucleus stained weakly with Feulgen.

TYPE HOST: *Leptodactylus ocellatus*.


TYPE LOCALITY: Rio Bonito, Estado do Rio de Janeiro.

TYPE SPECIMENS: Deposited in Department of Zoology Instituto Oswaldo Cruz, Brazil.

#### EXPERIMENTAL INOCULATIONS :

A *Toxoplasma gondii* strain was inoculated in the frog *L. ocellatus* at room temperature of  $34^{\circ}\text{C}$ - $39^{\circ}\text{C}$  and ascitic fluid observed after 30 minutes, 2 and 5 hours showed the litic action on the parasites (Figs. 1 to 4). Tissues of 5 frogs inoculated were also examined for microscopic evidence of *Toxoplasma*, without being successful.

Attempt of experimental infection with frog brains containing cysts bodies of *Lankesterella alencari* in mice was unsuccessful.



Figs. 1-4: Show photomicrographs of postmortem smears of peritoneal exudates of *L. ocellatus*, inoculated with *Toxoplasma gondii* of human origin. The survival of intact organisms occurs only for 30 minutes; after this we can see the effects of lise (Figs. 2-4).



## DISCUSSION

Regarding the descriptive aspects of these studies we need to emphasize 2 points: the description of a new specie and the occurrence of cysts of this parasite in the central nervous system. Since **Alencar** (1957) had reported *Toxoplasma* in the brain of amphibia from Brazil and **Stone & Mannwell** (1969) had obtained successful experimental toxoplasmosis in cold-blooded vertebrates, we must emphasize the experimental aspect of these studies too. **Splendore** (1913) had infected the frog *Cystiguatus ocellatus* and recently **Stone & Mannwell** (1969) had obtained successful infection in the American toad *Bufo americanus*. Negative results were found by **Mannwell & col.** (1953) and **Stone & col.** (1969) with *Rana pipiens* and by **Kozar** (1952) using *Rana esculenta*.

The susceptibility of cold-blooded vertebrates to infection with *Toxoplasma* had an important proof with the experiments of **Stone & col.** (1969) using lizards kept under special conditions of temperatures.

The existence of naturally acquired toxoplasmosis in amphibia of South America was mentioned by **Scorza & col.** (1956) and **Alencar** (1957) as we had remarked recently (**Costa & col.** 1970, a, b and 1971). About this problem **Ball** (1965) stated the following: "Although it can persist for some time when transferred experimentally, *Toxoplasma* probably does not occur naturally in amphibians or reptiles".

As suggested **Stone & col.** (1969) we tested a new group of amphibia for *Toxoplasma* infection and survival but our results showed that *Leptodactylus* were not susceptible to this parasite. On the other hand, the inoculation of brain parasited with cyst bodies in a highly susceptible host, mice, was negative. Otherwise, the cysts occurring in *Leptodactylus* are greater than those of *Toxoplasma* that measure about 40  $\mu$  in diameter by Silver stain method and 18,5  $\mu$  in diameter (average) with PAS stain.

It seems clear that the parasite found in the CNS of *Leptodactylus* is not *Toxoplasma*; we can also exclude other *Toxoplasma*-like, as *Besnoitia* that occur in lizard, by the structure of cysts which are thin-walled, without compartments; in *Besnoitia* they have thick, nucleus-lined walls; in *M-cyst* and *Sarcocystis* occur compartments. *Besnoitiosis* of lizard can be transferred to mice; the cysts of *Leptodactylus* give no infection in this host. Like *Toxoplasma* the parasite that we are now describing have predilection for nervous system — we have not seen cysts in lung, liver, spleen, heart, gut or kidney; *Besnoitia* is generally present in tissue organs.

Since we have not found schizogony neither in blood nor in liver or lung, we can exclude the relationship of this parasite with the family *Haemogregarinidae* whose common member in *Leptodactylus* of Brazil, *Hepatozoon leptodactyli* (Figs. 6 and 7), has the cycle well known (see **Cunha & Muniz**, 1927; **Costa & col.**, 1970c and **Pessoa**, 1970).

If we consider the development of erythrocytic forms and the occurrence of this parasite in large lymphocytes as well as schizogony in white cells, the only one of the families of that heterogeneous group of hemogregarines into which our organism could be placed is the *Lankesterellidae*.

The question now arises as to whether or not there are any generic differences between our parasite and *Lankesterella*. In our attempt to classify this parasite, we put it in the genus *Lankesterella* based in the blood forms, since the lankesterellid group is becoming very heterogeneous. In our present state of incomplete knowledge of life cycle of this organism we think that it is not justified the establishment of a new genus. In *Eimeriidae* it appears that differences in the site of development of division stages in vertebrate host are specific rather than generic.

Thus, in our specie, the greatest difference from other species of *Lankesterella* is the chief site of the division process in the CNS. Nevertheless, the blood forms resemble those forms belonging to *L. corvi* Baker, Lainson and Killick-Kendrick, 1959 and *L. bufonis* Mansour and Mohammed, 1962 chiefly by the lack of affinity for Giemsa's stain in some forms (Figs. 20 and 26) and curved body (Figs. 19 and 23). Sporozoites of *L. alencari* differ from the species above mentioned by the large size.

It is also worth noting that **Lainson** (1959) extended the distribution of *Lankesterella* to warm blooded vertebrates when he put the genus *Atoxoplasma* as synonym of *Lankesterella* and **Mansour & Mohammed** (1962) extended this genus to toads with the description of *L. bufonis* for *Bufo regularis* (Family *Bufo* *regularis* (Family *Bufo* *regularis*)). The parasite now described belongs to a new host, *Leptodactylus ocellatus*, that some authors put in *Bufo* *regularis* (Storer, 1960) [a new family *Leptodactylidae* was formed by other authors too], since it is not a true frog.

**Pessoa & Cunha Neto** (1967) had found forms resembling *Lankesterella* in the blood of *Leptodactylus pentadactylus* and this was the first reference of *Lankesterella* in Brazil.

In our previous papers (**Costa, Silva, Martinez & Pereira**, 1970a and b) we point out the two other toxoplasma-like organisms —

*Dactylosoma* and *Hepatozoon* — that occur in *Amphibia* and can appear in multiple infection with *Lankesterella* as was seen in Table II (see also Figs. 5, 6, 7, 18, 29, 34, 37, 38).

The merozoite of *Dactylosoma* closely resembles the organisms seen in the cysts of *L. alencari* and both are figured in the present paper for comparison (Figs. 37 and 38).

We have indicated previously that *Toxoplasma serpai* described by **Scozza** (1956) in *Bufo marinus* is a confusion with some stages of *Dactylosoma ranarum* and that the *Toxoplasma* found by **Alencar** (1957) in *Bufo marinus* is a confusion with *Haemogregarine*.

By the way, it is not uncommon as stated **Ball** (1967), especially in heavy infections, for schizogony to occur predominantly in one organ, for exemple liver or lung, and to be present also in a lesser degree in heart, spleen or intestine. In a case of *Leptodactylus ocellatus* with a hard parasitism by *Hepatozoon leptodactyli* we found the liver, spleen (Fig. 34) and lung heavy infected and the CNS infected also in a lesser degree (Fig. 29) as was discussed by **Costa & col.** (1970). In the case of *Lankesterella alencari*, however, we found a great specificity for this localization, like that observed with *Toxoplasma*.

### SUMMARY

*Lankesterella alencari* n. sp. a Sporozoa that occur in the blood and CNS of the South American frog *Leptodactylus ocellatus* is described. Since the tissue forms of this parasite have been previously reported as belonging to the genus *Toxoplasma*, we attempted infection of 2 species of amphibia (*Bufo marinus* and *Leptodactylus ocellatus*) with a *Toxoplasma* strain of human origin; inoculation was by intraperitoneal injection of parasite-containing ascitic fluid from infected mice.

Attempt of experimental inoculation of the parasite found in the CNS of *L. ocellatus* in a highly susceptible host (mice) was unsuccessful.

These results suggest that *Toxoplasma* does not occur naturally in amphibia; furthermore, the possibility of cyst bodies found in CNS of *L. ocellatus* be related to *Toxoplasma* is excluded. The following genera of haematozoa found in Brazilian amphibia have been considered briefly: *Haemobartonella*, *Cytamoeba*, *Dactylosoma*, *Hepatozoon* and *Trypanosoma*.

### RESUMO

#### LANKESTERELLA ALENCARI N. SP., UM "TOXOPLASMA-LIKE" NO SISTEMA NERVOSO CENTRAL DE AMPHIBIA (PROTOZOA, SPOROZOA).

Os autores descrevem uma espécie do gênero *Lankesterella* considerada nova para a ciência, que ocorre com certa frequência parasitando a rã *Leptodactylus ocellatus* no Brasil.

Como os cistos deste parasito, encontrados no SNC, foram anteriormente relacionados ao gênero *Toxoplasma* por outro autor, realizamos uma série de inoculações experimentais para eliminar a hipótese. Tanto as inoculações com amostra de *Toxoplasma gondii* de origem humana em anfíbios, como as de macerados de SNC de rã contendo cistos em camundongos, foram negativas. As inoculações de *T. gondii* em anfíbios foram realizadas em temperatura ambiente que no Rio de Janeiro, na época, era 30°C-39°C. Não encontramos, por outro lado, cistos no SNC de anfíbios do gênero *Bufo*, fato assinalado por outros autores. Realizamos algumas técnicas citoquímicas para melhor caracterização do parasito.

Tendo em vista o grande número de hemoparasitos encontrados nas rãs brasileiras e as infecções múltiplas ocorrerem com frequência, apresentamos também a incidência destes parasitos que compreendem os gêneros: *Haemobartonella*, *Cytamoeba*, *Dactylosoma*, *Hepatozoon* e *Trypanosoma*. Apresentamos também uma lista de todos os anfíbios examinados, bem como dados sobre a distribuição geográfica dos hemoparasitos encontrados.

Os autores chamam a atenção para o fato de *Leptodactylus ocellatus* ser uma rã muito comum no Brasil e utilizada com muita frequência em trabalhos experimentais de Bioquímica, Fisiologia, Bacteriologia, etc. No caso de infecções intensas por esporozoários os órgãos sofrem lesões extensas e por este motivo julgamos necessário que em tais trabalhos experimentais esse parasitismo seja levado em consideração.

#### ACKNOWLEDGMENTS

We should like to thank Dr. Nery Guimarães for the *Toxoplasma* strain, Dr. Guido Schäffer for a human case of toxoplasmosis and Dr. Alexandre Alencar for the opportunity to discuss the problem. We should also like to thank Dr. Antenor Leitão de Carvalho by the identification of some *Amphibia*. We wish to acknowledge the assistance of Mr. J. Carvalho in the preparation of the photomicrographs.

#### REFERENCES

- ALENCAR, A. A., 1957, Toxoplasmose espontânea e inaparente em anfíbios dos gêneros *Leptodactylus* e *Bufo*. *J. Bras. Neurol.*, 9: 137-146.
- BALL, G. H., 1965, Some protozoa and other bodies found in the blood of reptiles and amphibians. *Second International Conference on Protozoology*, London, August, 1965. *Excerpta Medica International Congress Series* 91.
- BALL, H. C., 1967, Some blood Sporozoans from East African Reptiles. *J. Protozool.*, 14 (2): 198-210.
- BAKER, J. R.; LAINSON, R.; KILLICK-KENDRICK, R., 1959, *Lankesterella corvi* n. sp., a blood parasite of the English Rook, *Corvus f. frugilegus* L., *J. Protozool.*, 6 (3): 233-238, 16 figs.

- COSTA, S. C. G. da; SILVA, A. M.; MARTINEZ BERNAOLA, N. & PEREIRA, N. M., 1970, The problem of Toxoplasmosis in *Amphibia* (Part I), Forms related to the "Dactylosoma" life cycle (Protozoa, Sporozoa), *Atas Soc. Biol. Rio de Janeiro*, 12 — Suplemento, 7-13, 11 figs.
- COSTA, S. C. G. da; SILVA, A. M.; MARTINEZ BERNAOLA, N. & PEREIRA, N. M., 1970, The problem of Toxoplasmosis in *Amphibia* (Part II) (Protozoa, Sporozoa), *Rev. Brasil. Biol.* 30 (3): 367-370, 9 figs.
- COSTA, S. C. G. da; SILVA, A. M.; MARTINEZ BERNAOLA, N., 1970, Hemoparasitos de anfibios do Brasil. Estudo citoquímico de "*Haemogregarina leptodactyli*" Lésage, 1908, *Atas Soc. Biol. Rio de Janeiro*, 13 (1 e 2): 55-59, 9 figs.
- COSTA, S. C. G. da; PEREIRA, N. M. & MARTINEZ BERNAOLA, N., 1971, The problem of Toxoplasmosis in *Amphibia* (Part III). A Protozoon in the Central Nervous System of *Leptodactylus ocellatus* (Protozoa, Sporozoa). *Atas Soc. Biol. Rio de Janeiro*, 14 (3 e 4): 45-48, 7 figs.
- CUNHA, A. M. & MUNIZ, J., 1927, Sôbre o ciclo endógeno da *Haemogregarina leptodactyli* Lésage, 1908 (*Karyolysus*), Uber den endogen Zyklus der *Haemogregarina leptodactyli* Lésage, 1908 (*Karyolysus*), *Mem. Inst. Oswaldo Cruz*, 20: 307-315.
- DOFLEIN, F., 1898, Studien zur Naturgeschichte der Protozoen III. Ueber Myxosporidien. *Zool. Jahrb. Anat.*, 11: 19-350 (c.f. Marquet E. and Sobel, H., 1970).
- KOZAR, Z., 1952, Attempted adaptation of human toxoplasma to cold-blooded animals. *Bull. State Inst. Mar. Trop. Med. Gdansk.*, IV (1): 23-28.
- LAINSON, R., 1959, *Atoxoplasma* Garnham, 1950, as a synonym for *Lankesterella* Labbé, 1899, Its life cycle in the english sparrow (*Passer domesticus*, Linn.), *J. Protozool.*, 6 (4): 360-371.
- MANSOUR, N. S. & MOHAMMED, H. A. H., 1962, *Lankesterella bufonis* Reuss, in Egypt, *J. Protozool.*, 9 (2): 243-248.
- MANNWELL, R. D.; BERNSTEIN, E. & DILON, R., 1953, Toxoplasma in frogs. *J. Parasit.*, 39: 406-407.
- MARQUET, E. & SOBEL, H., 1970, A protozoon in the Central Nervous System of the lungfish *Polypterus enlicheri*, *J. Protozool.*, 17 (1): 71-76.
- PESSOA, S. B., 1970, Formas evolutivas do *Hepatozoon leptodactyli* (Lésage, 1908) na sanguessuga *Haementeria lutzi* Pinto, 1920, *Rev. Goiana Med.*, 16: 35-39, 9 figs.
- PESSOA, S. B. & CUNHA NETO, A. G., 1967, Notas sôbre hemoparasitas de rãs de Goiânia, *Rev. Goiana Med.*, 13: 101-116, 41 figs.

- SCORZA, J. V.; DAGERT, C. & AROCHA, L. I., 1956, Estudo sôbre hemoparasitos de *Bufo marinus* L. da Venezuela. 1. Hemogregarinas. 2. Uma nova espécie de *Toxoplasma*, *Mem. Inst. Oswaldo Cruz*, 54 (2) : 373-392, 17 figs.
- SPLENDORE, A., 1913, Nuove osservazione sull *Toxoplasma cuniculi*, *Rend. R. Accad. Lincei*, 23: 722-727.
- STENSAAS, L. J.; STENSAAS, S. S. & SOTELO, J. R., 1967, An intra-axonal protozoon in the spinal cord of the toad *Bufo arenarum* (Hensel), *J. Protozool.*, 14 (4) : 585-595, 19 figs.
- STONE, W. B. & MANNWELL, R. D., 1969, Toxoplasmosis in cold-blooded hosts, *J. Protozool.*, 16 (1) : 99-102, 6 figs.
- STORER, T. I. & USINGER, R. I., 1960, *Zoologia General*. Omega, S. A. ed. Barcelona 1003 pp.

PLATE I

- Fig. 5: A segmenter with six chromatin masses of the toxoplasma-like *Dactylosoma ranarum* (Lankester, 1882) Labbé, 1894. Giemsa stain.
- Fig. 6: Methyl-green pyronin stained impressions of *Hepatozoon leptodactyli* schizont in the liver of *L. ocellatus*.
- Fig. 7: Feulgen stained body cyst of *Hepatozoon leptodactyli* in the liver.
- Figs. 8-9: PAS stained section from central nervous system of *L. ocellatus* showing cysts of *Lankesterella alencari*. In figure 9 we found some cysts together simulating one cyst with compartments.






Fig. 5



Fig. 6

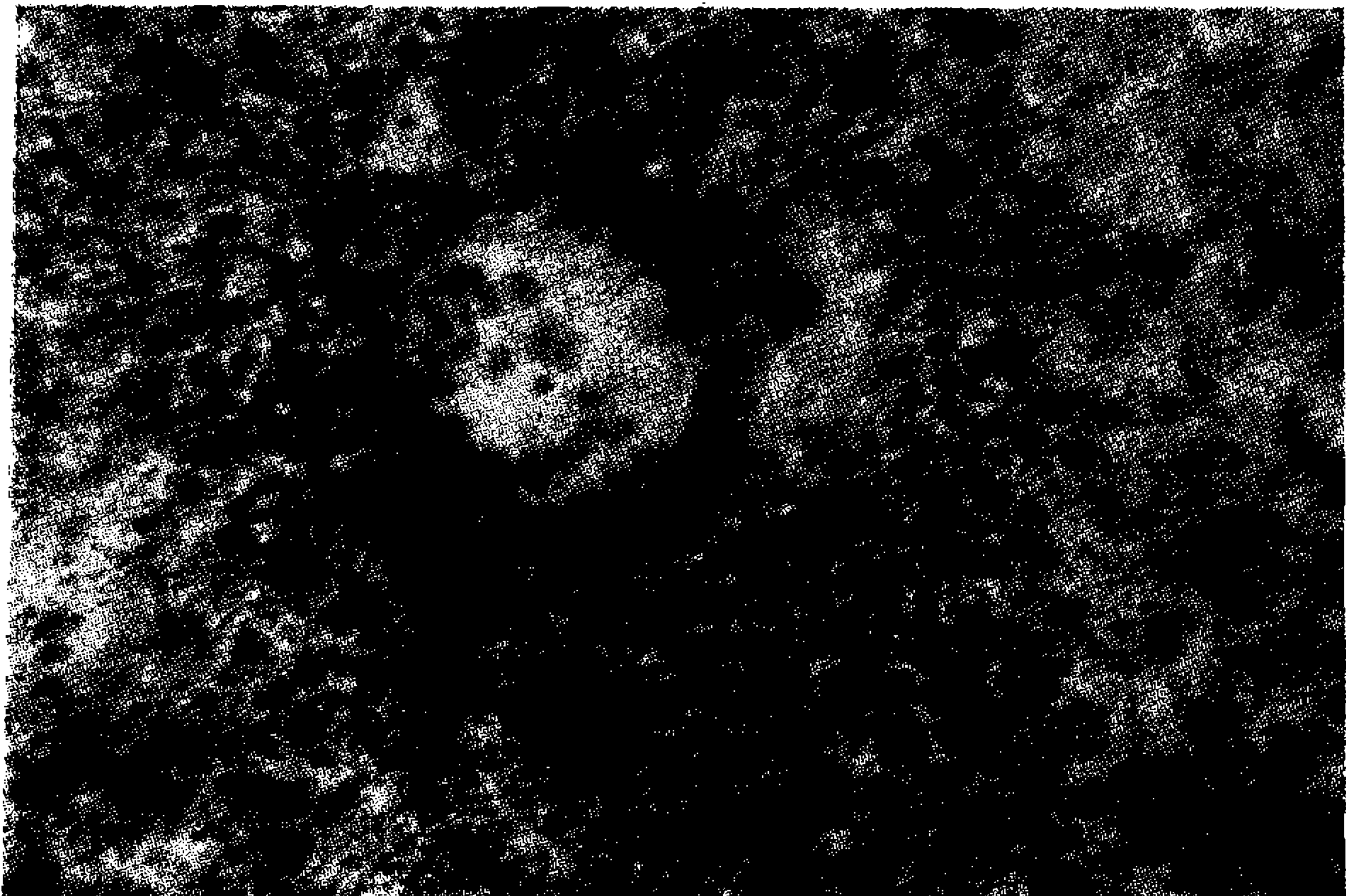


Fig. 7



Fig. 8




Fig. 9

PLATE II

Figs. 10-14: Drawings of *Lankesterella alencari* in blood of *Leptodactylus ocellatus*.

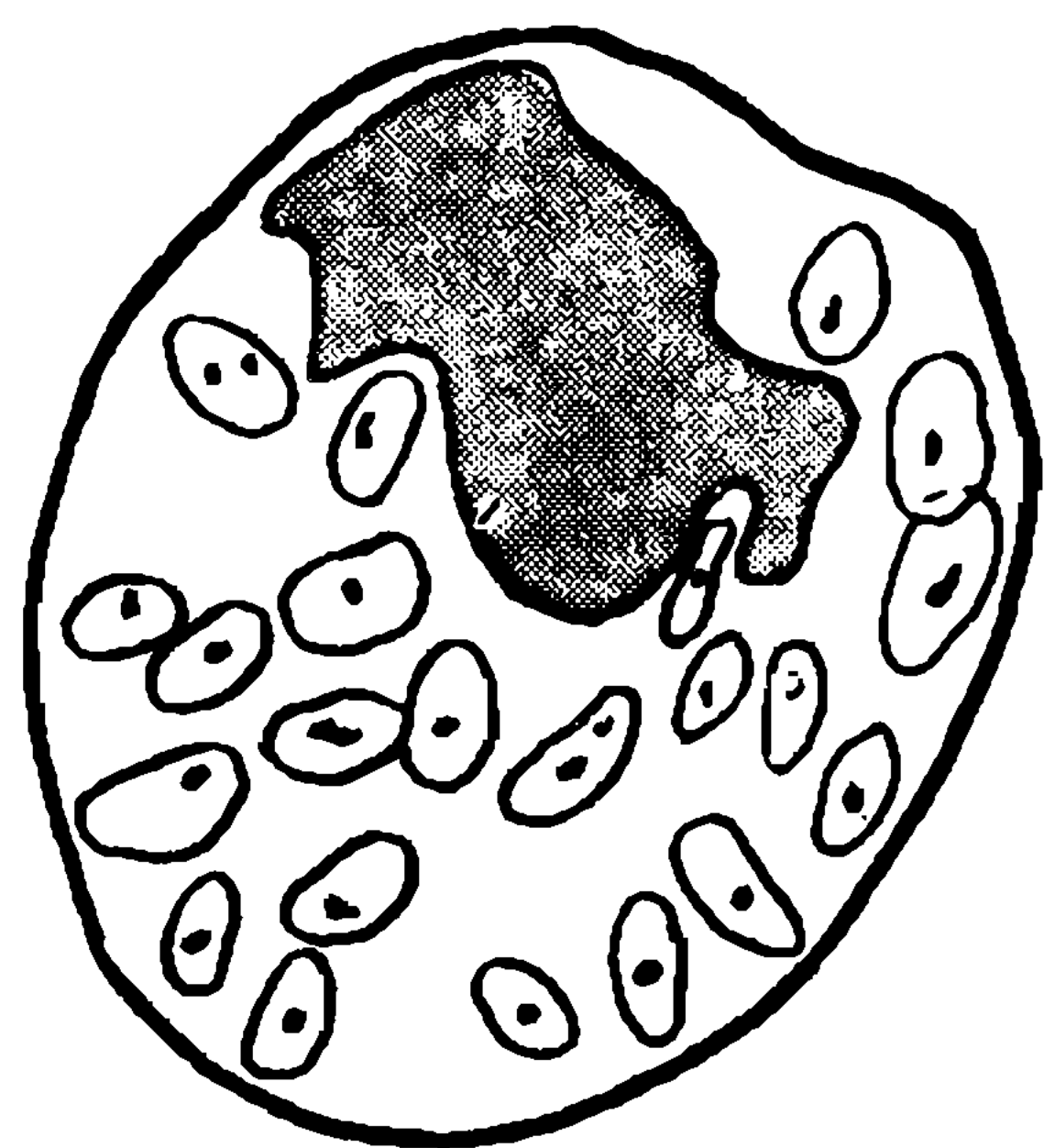
Fig. 10: White cell of a frog with a heavy infection by *L. alencari* showing several parasites. It seems to be the result of schizogony.

Fig. 11: Two parasites in white cell.

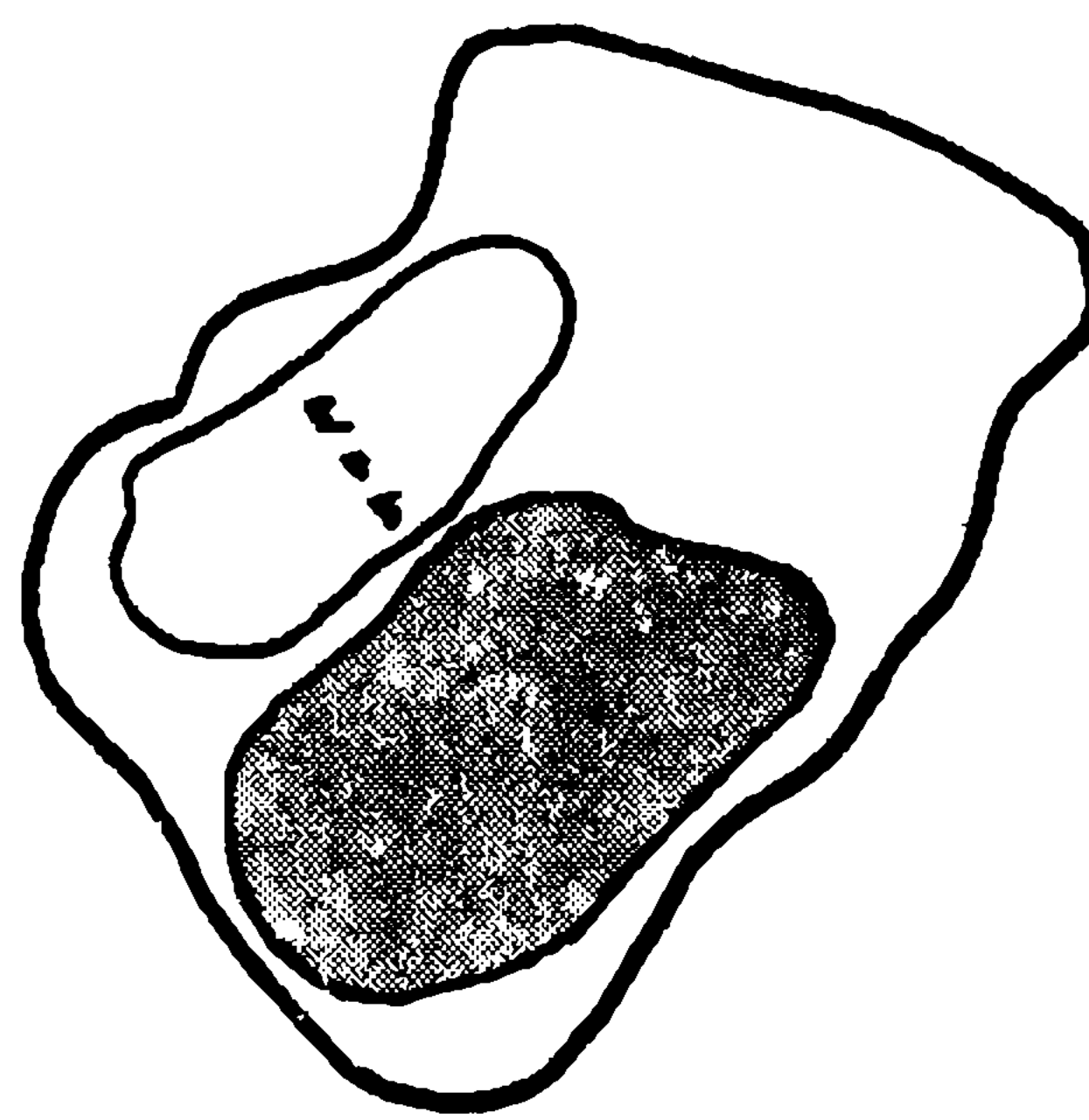
Fig. 12: Erythrocytic stage whose form is similar to those forms of photomicrographs 16 and 17.

Fig. 13: A large form occurring in lymphocyte.


Fig. 14, In fig. 14a we can see a sporozoite like photomicrographs of fig. 19. In fig. 14b we represent the lack of affinity for Giemsa's stain of some forms. Finally we represent in fig. 14c those forms like photomicrograph 21, in which the cytoplasm stains very lightly with Giemsa.



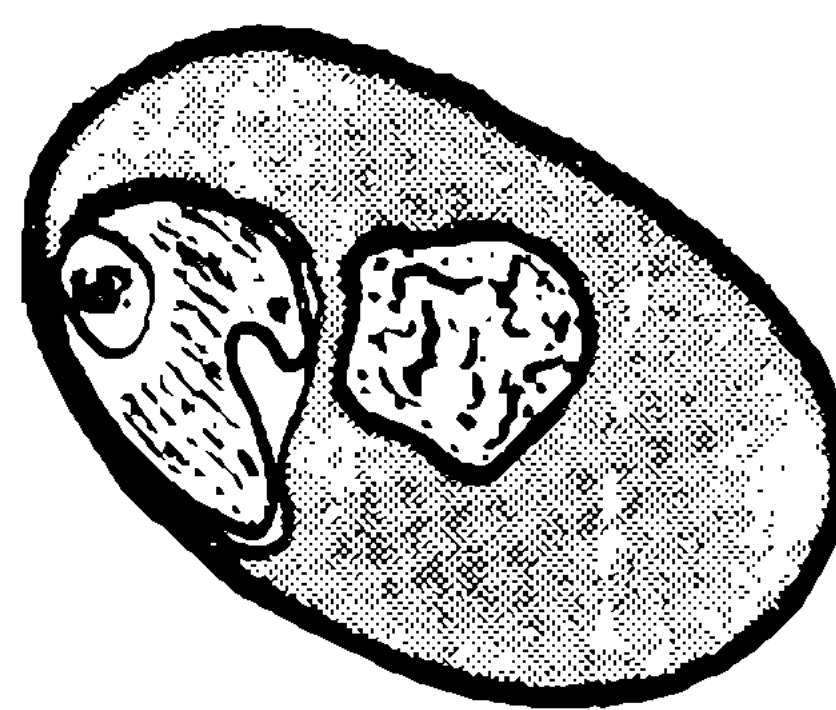
**10**



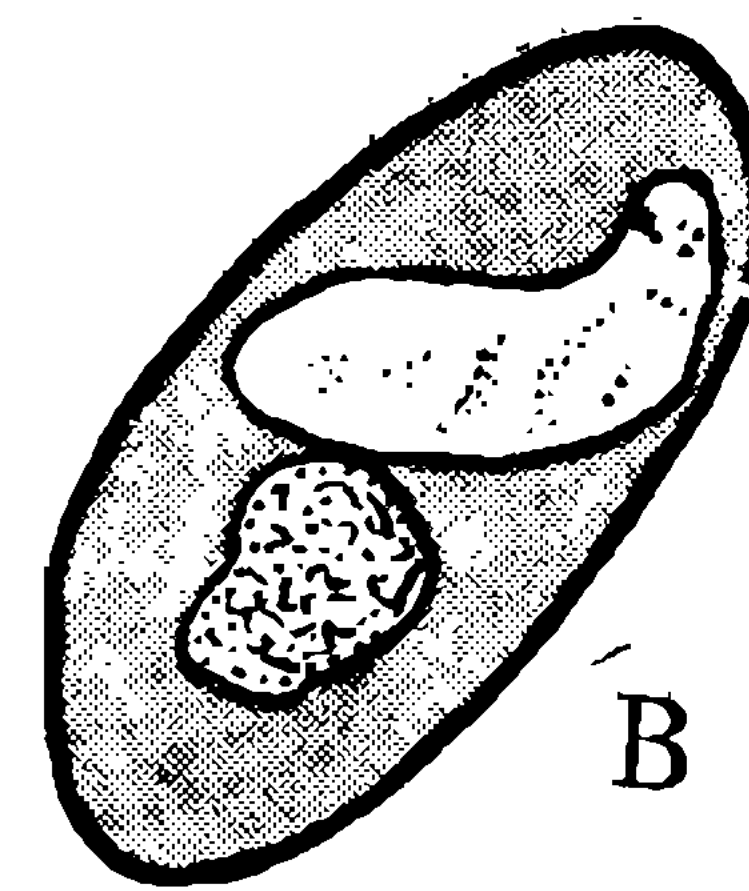
**13**



**11**

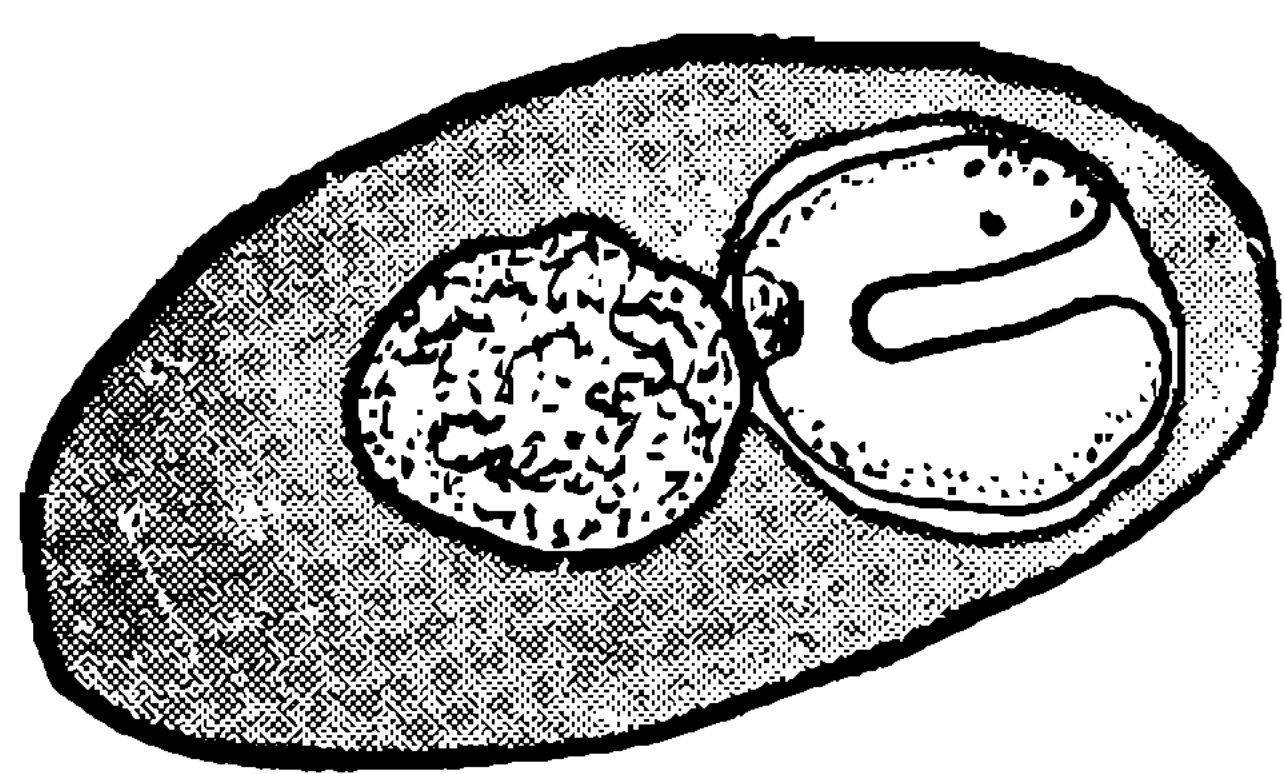


A



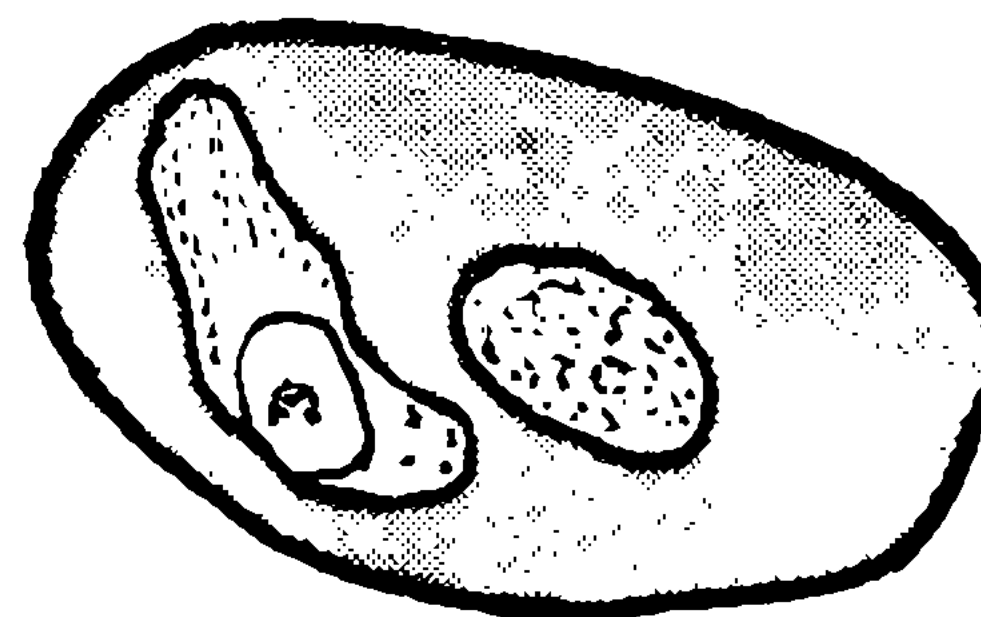
B

0,02 mm.



0,01 mm.

**12**



C

**14**

### PLATE III

Figs. 15-26: Photomicrographs of *Lankesterella alencari* (except fig. 18) in blood of *Leptodactylus ocellatus*. Giemsa stain.

Fig. 15: A small form in which the cytoplasm stains heavy with Giemsa in the periphery. X 1420.

Figs. 16-17: A roundish form. We think that these forms are enclosed in a sheath. X 1420.

Fig. 18: *Cytamoeba bacterifera*, an organism very frequent in *L. ocellatus* that can be confused with the form presented in figure 16. In figure 16, however, the organism presents a nuclear structure. X 2000.

Fig. 19: A characteristic form of *L. alencari*. These small folded bodies present a cytoplasm heavy stained. See the camera lucida drawing in figure 14a for best understanding. X. 920.

Fig. 20: A large form where we can observe the lack of affinity for Giemsa's stain. Several dark granules can be seen in the periphery of the body. X 2000.

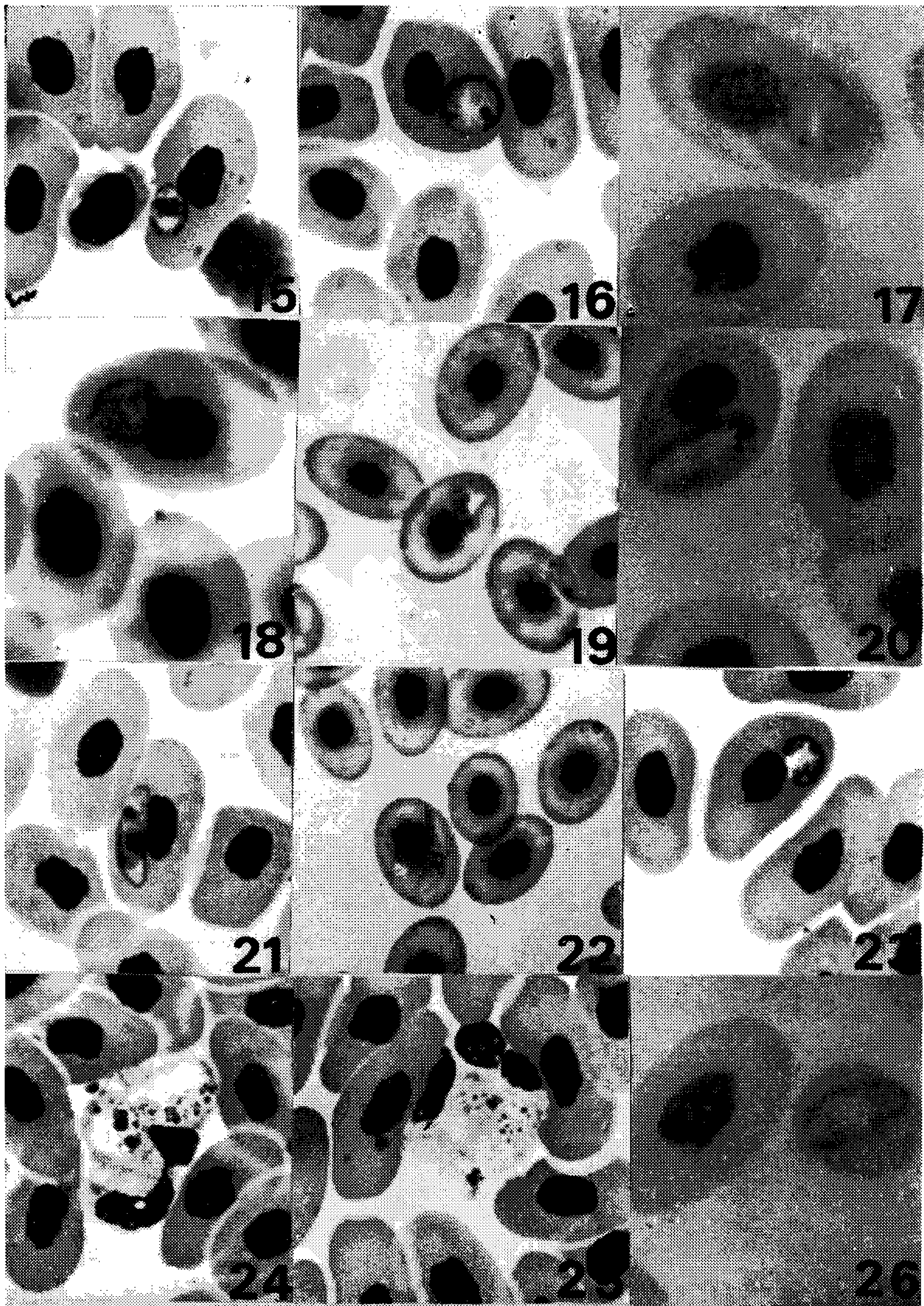
Fig. 21: An intraerythrocytic elongated form whose cytoplasm stains with Giemsa. The nucleus is vesicular. X 1420.

Fig. 22: An intraerthrocytic hemogregarina of *Lankesterella alencari* in which the cytoplasm is homogeneous and hyaline. This form presents a curved body and can occur free in the plasm. X 920.

Fig. 23: A heavy Giemsa stained cytoplasm of a folded body. X 1420.

Figs. 24-25: White cells with division forms of *Lankesterella alencari*. X 1420.

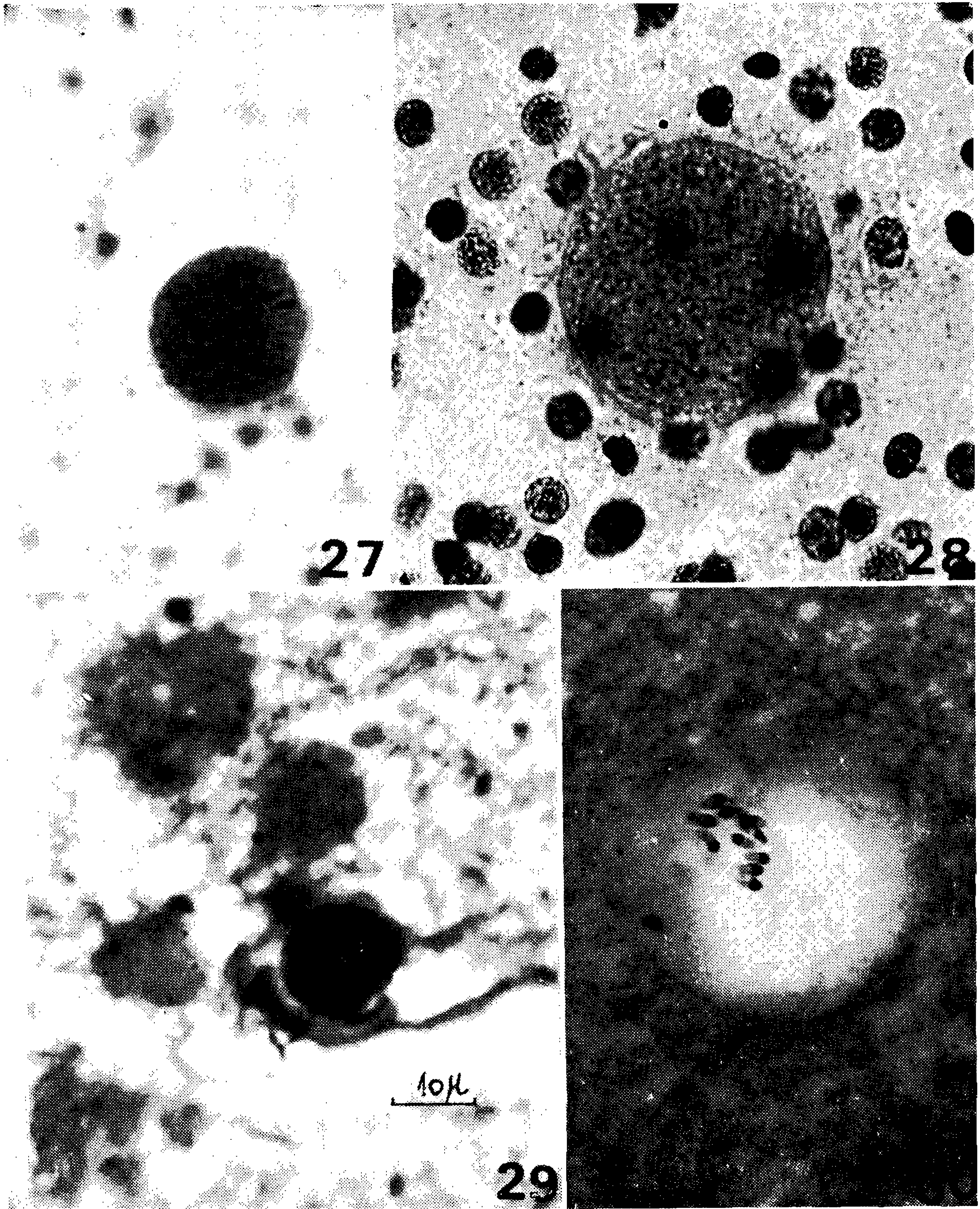
Fig. 26: A large form similar to figure 20 in an erythrocyte that have lost its nucleus. X 2000.



Costa & Pereira: A Toxoplasma-like organism

PLATE IV

- Fig. 27: PAS stained section of human CNS shows a *Toxoplasma gondii* cyst for comparison. Oc. 7 X. Obj. 100 X Olympus.
- Fig. 28: Silver stained section of human CNS showing a *T. gondii* cyst. Oc. 7 X, Obj. 100 X Olympus.
- Fig. 29: PAS stained section of the CNS of *Leptodactylus ocellatus* showing a schizont of *Hepatozoon leptodactyli* in the blood vessel.
- Fig. 30: PAS stained section of *L. ocellatus* CNS showing a cyst with *Lankesterella alencari*. The cyst contains a few organisms each of which contains a glycogen granule approximately the size of the nucleus. X 920.



Costa & Pereira: A Toxoplasma-like organism

#### PLATE V

- Fig. 31: Hematoxylin-eosin stained section of the CNS of *L. ocellatus* shows a parasited neuron (Alencar, A., 1957, fig. 4).
- Figs. 32-33: PAS stained section of CNS showing *Lankesterella alencari*. Figure 32, at high magnification, shows several parasites containing glycogen granules and the cyst wall PAS positive. X 920. In figure 33, at low magnification, we can see great number of cysts in brain of a specimen which had a heavy infection in blood.
- Fig. 34: PAS stained section of *L. ocellatus* lung, presenting several cysts of *Hepatozoon leptodactyli*. X 1440. When heavy infections of this parasite occur in blood, we find a great number of *H. leptodactyli* cysts in lung, liver and spleen.



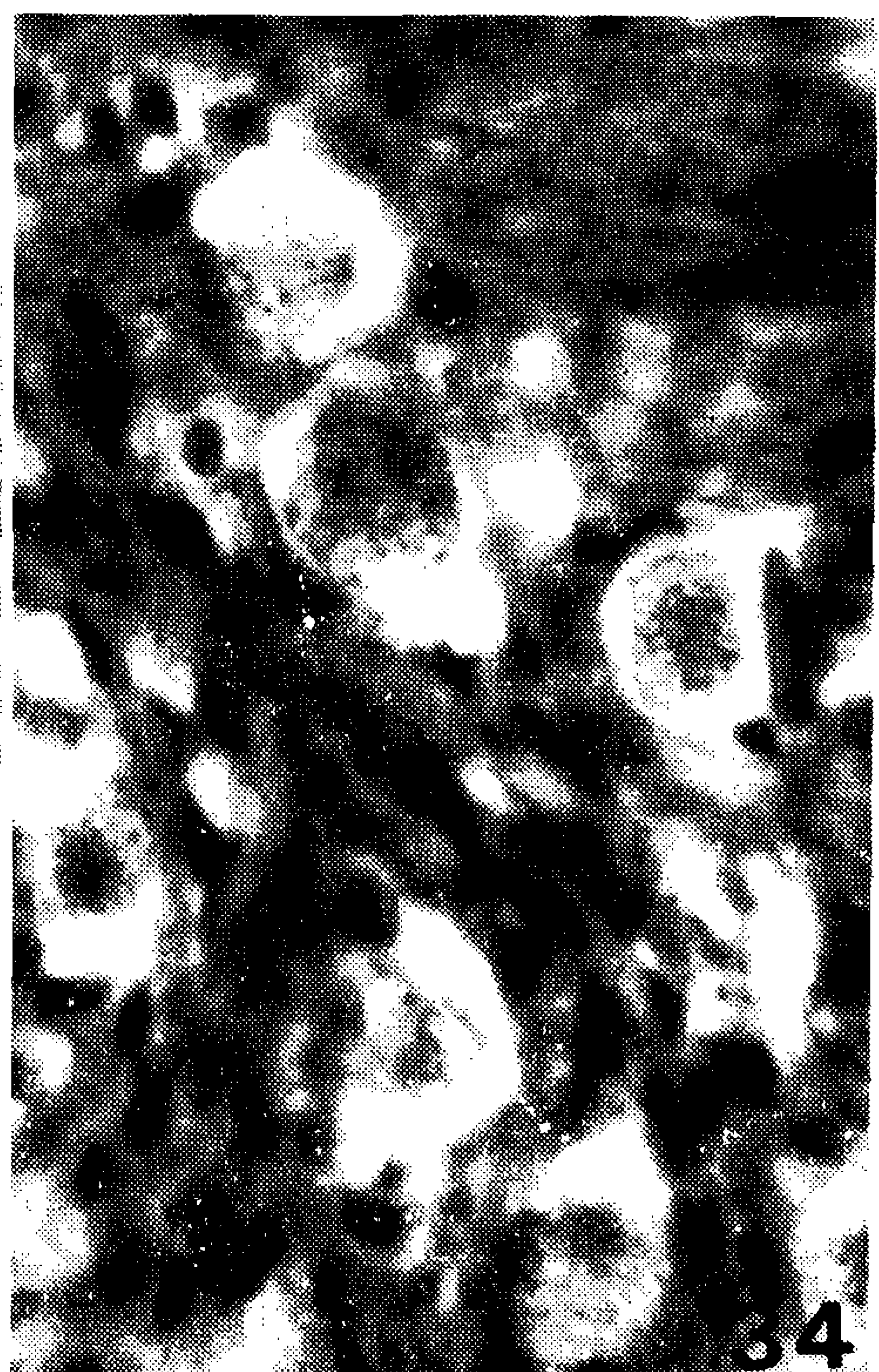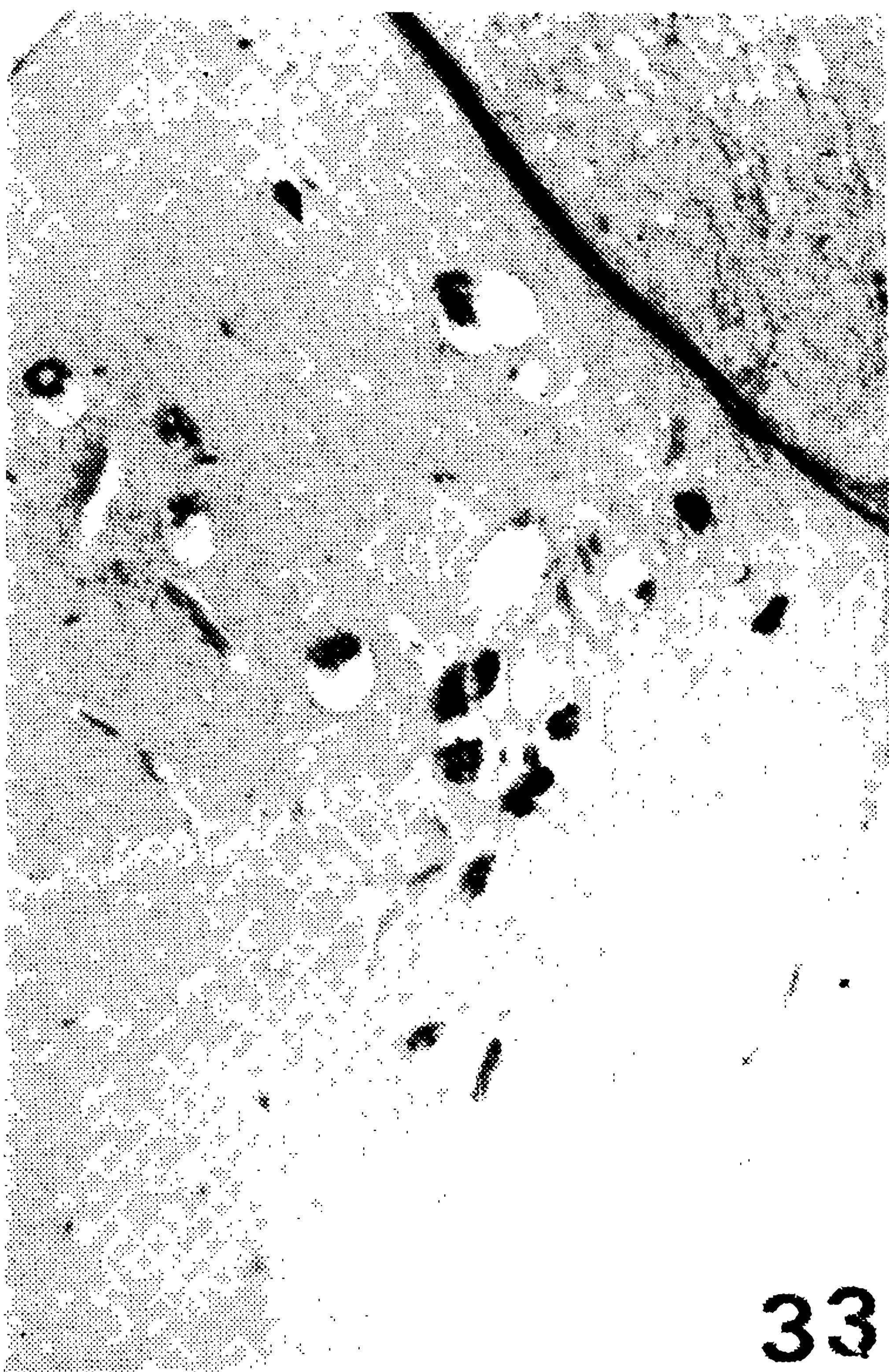
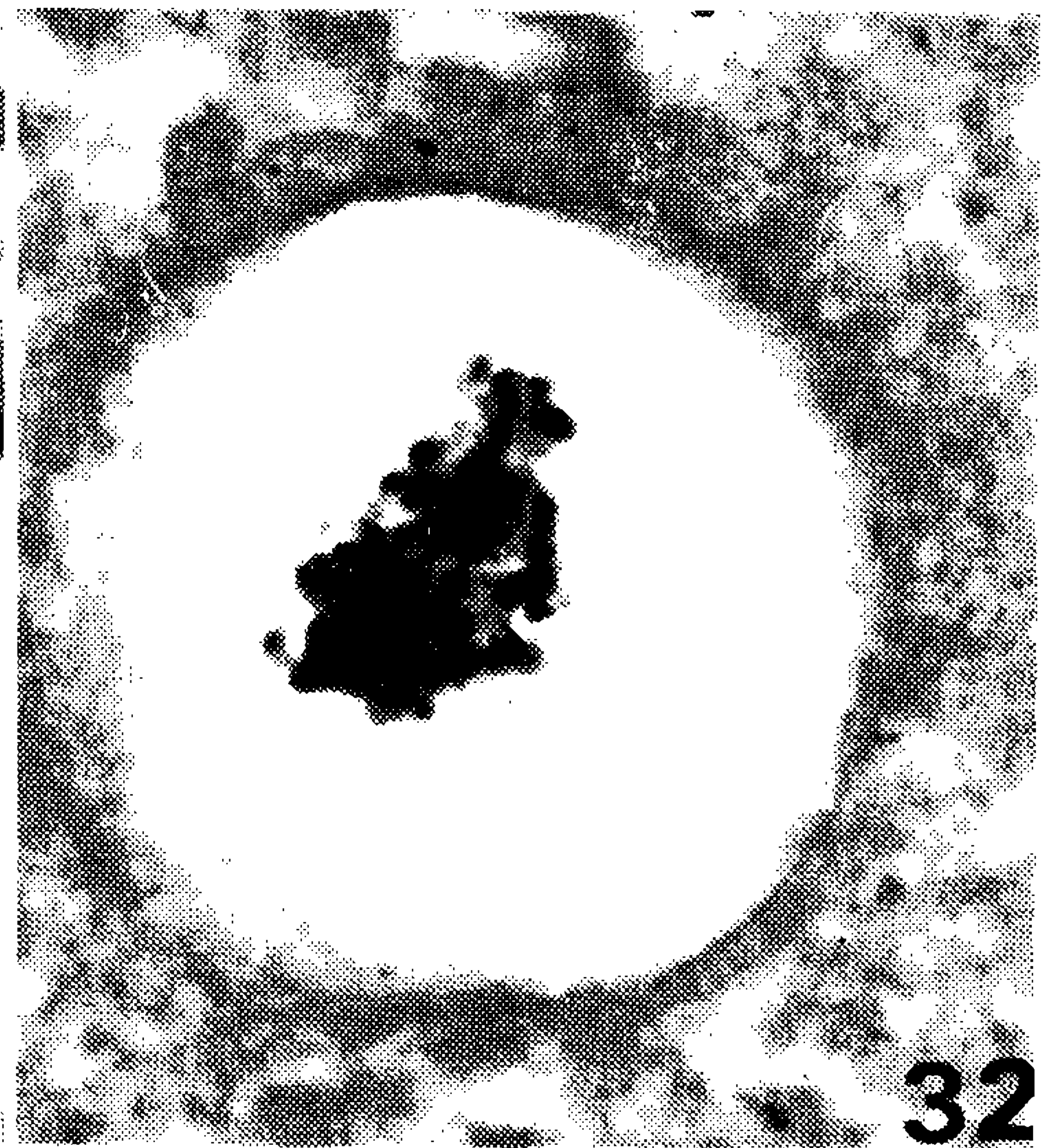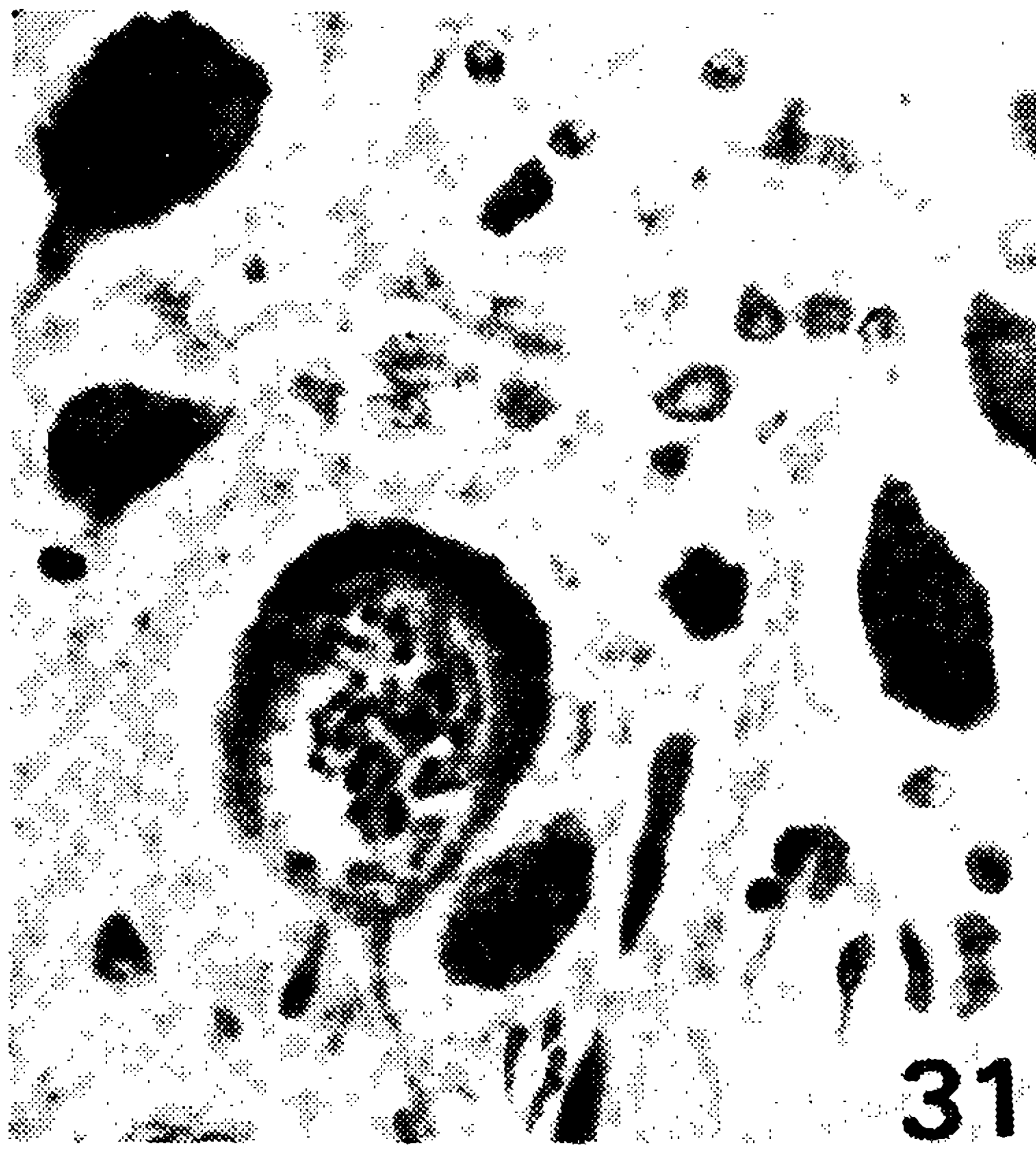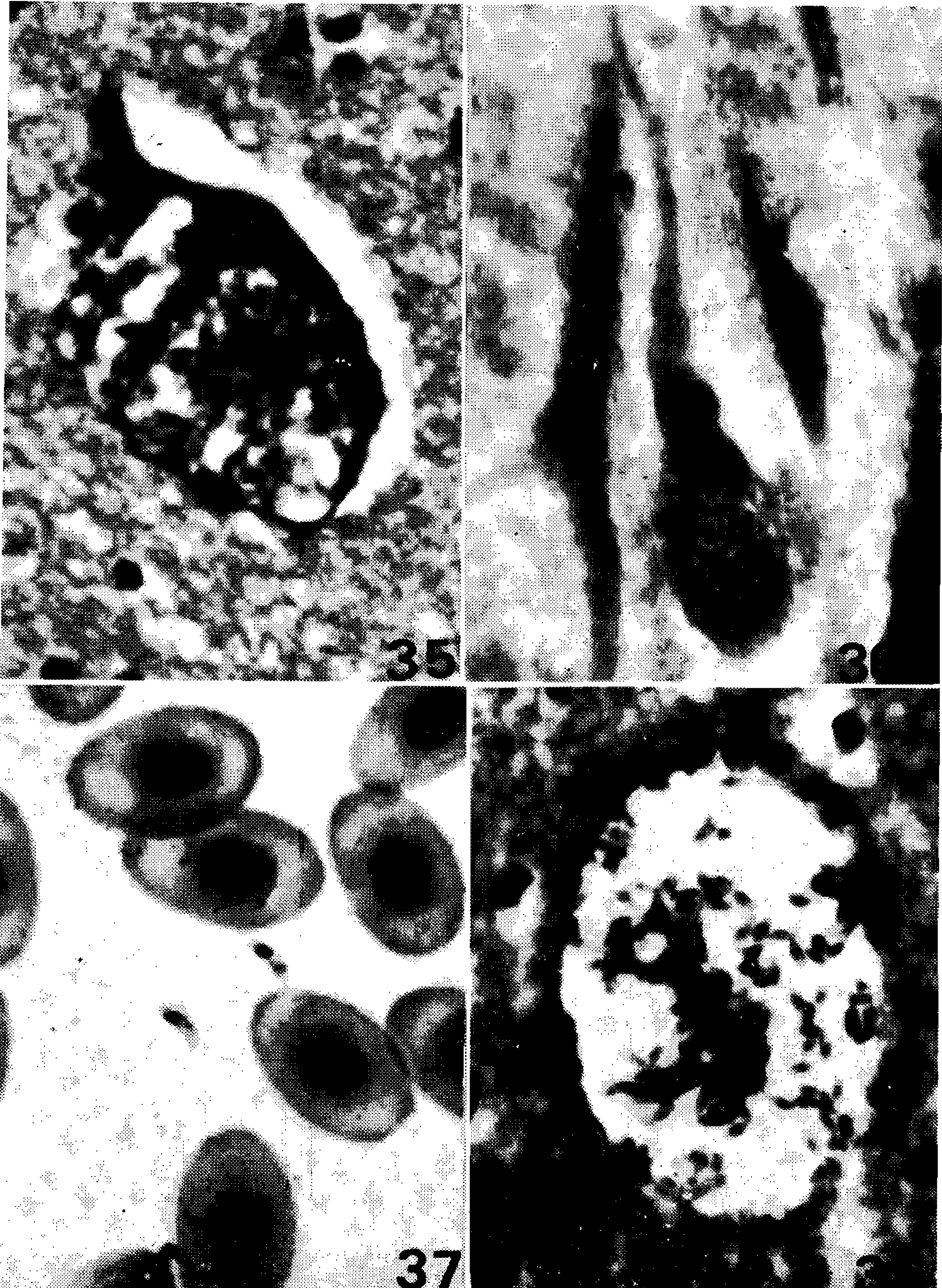


PLATE VI

- Fig. 35: Hematoxylin-eosin stained section of the CNS of *L. ocellatus* showing the destructive effect of *Lankesterella alencari* in the neuron. X 920.
- Fig. 36: The initial stage of the parasitism by *L. alencari* in the neuron.
- Fig. 37: Merozoites of *Dactylosoma ranarum* free in the plasm. Note that this crescentic organism is very similar to those of figure 38. X 1560.
- Fig. 38: Hematoxylin-eosin stained section of the CNS of *L. ocellatus* parasited by *Lankesterella alencari*. X 920.



Costa & Pereira: A Toxoplasma-like organism