

Neisseria meningitidis: A Neglected Cause of Infectious Haemorrhagic Fever in the Amazon Rainforest

David E. Barroso¹ and Luciete A. Silva²

¹Enteroviruses Laboratory; Oswaldo Cruz Institute, FIOCRUZ, Rio de Janeiro, RJ; ²Biodiversity Laboratory, Leônidas & Maria Deane Research Center, FIOCRUZ, Manaus, AM; Brazil

Neisseria meningitidis has not been seen as a significant cause of infectious haemorrhagic fever in the Amazon inlands; most reported cases are from the city of Manaus, the capital of the State of Amazonas. This picture is sustained by the lack of reliable microbiology laboratories, the perception of the health care workers, and the difficult to reach medical assistance; thus the number of confirmed cases is even lower with no reference of the strains phenotype. We report here the investigation of a case of suspected meningococemia and his close contacts in a rural community in the Coari Lake, up the Amazon River.

Key-Words: *Neisseria meningitidis*, meningococcal disease, haemorrhagic fever, Amazon forest.

Neisseria meningitidis is a normal commensal of humans, usually restricted to the upper respiratory tract, with baseline prevalence of carriage in the general population between 5 and 10% [1]. Truly, some symptom-free persons may carry pathogenic strain intermittently, for many months or years without developing invasive disease [2]. The progression from carriage to host invasion often occurs within the first weeks (1 to 14 days) after acquisition of a pathogenic *N. meningitidis*, however it is an event observed with different frequencies according to the population and its geographic location [3]. The most common clinical presentation is acute meningitis, but it has ability to cause occult bacteremia and septicaemia [3,4]. It is important to take notice that *N. meningitidis* is the major cause of purpura fulminans, followed by *Streptococcus pneumoniae*, in adults [5]. Focal disease has also been diagnosed in a low frequency, many times because a bacterial aetiology has not been searched [6,7]. When a susceptible person develops invasive disease this can be rapidly progressive, evolving to death in a few hours or producing permanent dysfunction in at least 10% of the survivals [3,7]. The patient's life depends on early recognition, prompt parenteral antibiotic therapy, careful evaluation during the first 24 h of hospitalization, and, frequently, immediate admission in an intensive care unit [5,8].

Meningococcal disease is a major medical emergency and a serious threat to the welfare of people living in Brazil, where 23,204 cases have been reported between 2000 and 2005 to the Brazilian Ministry of Health; 4,570 (20%) of these cases died and the number of survivals with permanent neurological sequelae is unknown [9]. Of the total, 690 (3%) cases were recorded in the Amazon, mostly were from the city of Manaus (67%), the capital of the State of Amazonas. The overall case fatality rate in Manaus was 19% (87/465) and for those with

septicaemia was 55% (64/117). Laboratory has only been instrumental in identifying meningeal pathogens in the capital; however results of strains identification and characterization are just available since 2000. With this improvement for meningococcal disease surveillance, 64% (299/465) of the notified cases from that city were confirmed by culture or latex agglutination test. From 2000 to 2005, strains of serogroup B (89%) and, to lesser extent, serogroup C (11%) dominated in clinical isolates (Manaus City Department of Health).

The transportation around that vast rivered land is normally possible either by boats or by aircraft, which transport people and goods between the main cities along the Amazon River and its large tributaries (Figure 1). This aggravates the outcome of inlands patients with life-threatening diseases because medical assistance is absent in the villages or even precarious in the nearest city, which can be located a few hours to days far by dugout canoe or launch. The perception of the population and health care professionals about meningococcal disease is another serious issue, because early clinical features - fever, headache, sore throat, and myalgia - are indistinguishable from those of many other so far more prevalent virus and parasitic diseases [6,10-13]. Besides atypical presentations, manifestations suggesting a diagnosis of other less serious infectious diseases also occur. Gastrointestinal symptoms - nausea, vomiting, and diarrhea - may precede the haemorrhagic rash and other more characteristic features of meningococemia, especially in an infant or an elderly patient, sometimes suggesting the diagnosis of gastroenteritis [7,12,13]. Thus it is seldom thought as a differential diagnosis of infectious haemorrhagic fever in an early stage, resulting in delay in diagnosis and thus in the initiation of specific therapy.

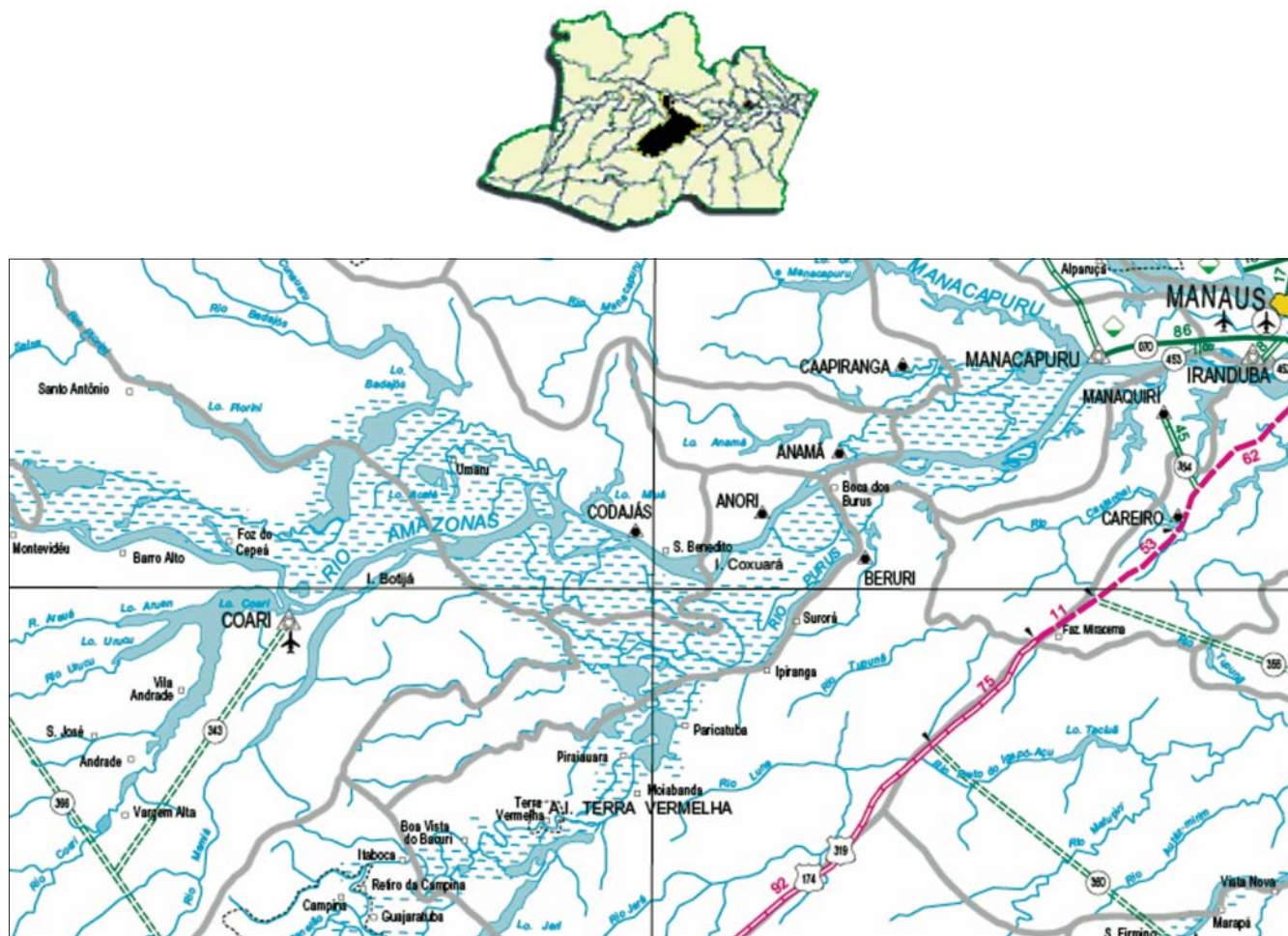
Case Report

During the last five years, suspected meningococcal disease cases have been noticed in remote areas of the rainforest, affecting rural and indigenous communities, by local health agents of the State of Amazonas (Fundação Nacional de Saúde - AM, Coordenação de Epidemiologia de Coari e Antazes). Recently in the Leônidas & Maria Deane Research Center, Manaus, we were contacted as consultants to discuss

Received on 28 August 2007; revised 25 October 2007.

Address for correspondence: Dr. David E. Barroso, Laboratório de Enterovírus, Instituto Oswaldo Cruz, FIOCRUZ, Av. Brasil 4365, Rio de Janeiro, RJ. Zip code: 21040-900, Brazil; E-mail: barroso@ioc.fiocruz.br; Phone\Fax: 55.21.2564-7638.

Figure 1. On the top, the map of the State of Amazonas with the Coari Region detached. On the bottom, the city of Coari and the Coari Lake in the left inferior quadrant located 463 km away from the city of Manaus, the capital of the State.



a case of septicaemia with purpura diagnosed four days before in the city of Coari. A 46-years old man was healthy until two days prior to hospital admission when he developed fever, headache, and general malaise. On the next day, he had the onset of myalgia, vomiting, and a petechial rash. Patient became confused, and his level of consciousness deteriorated progressively. The rash disseminated with appearance of extensive purpuric eruptions over all four extremities and the face. Then, he was transported by households in a rustic launch (“voadeira”) from a rural community in the Coari Lake to the local hospital in the city of Coari. Upon arrival, the patient was unconscious with systemic shock and died a few minutes later in the emergency room. One episode of seizure was described before the fatal outcome. Biological samples for the search of an infectious agent have not been collected. The clinical course was suggestive of *N. meningitidis* aetiology and our presence was requested to investigate a suspected meningococcal disease in the rural community of the Divino Espírito Santo do Izidório, one of the 17 communities within the Coari Lake (Figure 1).

In the same day, the field work was immediately planned and prepared taking into account the necessity to give out information, administer a 2-day course of rifampicin to households and offer selective chemoprophylaxis to close contacts outside the immediate family. The boat went off in the next day up the Amazon River and after 24 h it arrived in the city of Coari (population density: 1.46 persons/Km²) located 463 Km away from Manaus, with a population of 84,309 inhabitants (2005), with 17,597 (21%) living in one of the 110 rural communities (Figure 1). The Coari City Department of Health had received the notification of 12 cases of unspecified bacterial meningitis (G00.9, ICD-10) with a case fatality rate of 73%, over a 5-year period; a petechial rash was present in three and arthritis in one, suggesting a possible diagnosis of meningococcal meningitis. Of these cases, 73% were younger than five years old and eight were from rural communities, but none were from the patient’s village. On the next morning, we went to the Divino Espírito Santo do Izidório community, where 72 families (median of five individuals per nucleus family) live in wood houses into a humid forest area. The central village

comprises 18 families with a total of 50 adults and 29 children. The other 54 families like the patient's one lived close to rivers, in the surrounded small tributaries of the Coari Lake. One week before his disease, the patient left home only once to spend one night in the central village. At that time, he had close contact with one nucleus family and almost none with the majority of the people living in that small village, which is at least 1 h far by launch from his house in a narrow river into a remote area of the forest.

In the affected family group (n = 30), in the closest neighbouring family (n = 6), and in the central village (n = 79), throat swabs were analyzed for colonization of *N. meningitidis*, *Neisseria lactamica*, and *S. pneumoniae*. The whole population of the three investigated groups were examined after obtaining informed consent. Information about meningococcal disease was provided to all participants in this investigation. The households of the patient were medicated with a 2-day course of rifampicin just after the throat swabs were taken. Outside the immediate family, selective chemoprophylaxis was administered to the identified carriers of a bacterium characterized as Gram-negative diplococcus and positive for oxidase and catalase reactions. The investigation has taken about 6 h with a total of 115 duplicated throat swabs collected by a single investigator. While in the field, the first swab was immediately inoculated onto 5% sheep blood agar (Müeller-Hinton Oxoid CM0337) with VCNT selective supplement (Oxoid SR091E) to isolate *N. meningitidis* and *N. lactamica*, and then a second swab onto 5% sheep blood agar (Müeller-Hinton Oxoid CM0337) supplemented with 5 µg/mL gentamicin to isolate *S. pneumoniae*. All plates were brought back to the laboratory in the city of Coari and streaked to permit the growth of isolated colonies before appropriate incubation. On the next day, the culture plates were transported to the city of Manaus at room temperature (35–36°C). In the capital, it was observed the procedure of isolate and transport resulted in equal survival rates for the three searched species. The growth of one oxidase-positive colony, with the appearance of Gram-negative diplococci was identified by means of api NH system (bioMérieux). On the duplicate plate, α-hemolytic isolates with a 5 µg optochin disk (Oxoid DD1) inhibition zone > 15 mm when they were incubated in a 5% CO₂ atmosphere were considered to be *S. pneumoniae* [14]. The bacteria isolated from nasopharyngeal specimens were saved on sheep blood agar slant and transported to Oswaldo Cruz Institute, where serogroup of *N. meningitidis* was determined by means of slide agglutination with specific antiserum (Difco). Minimal inhibitory concentrations (MIC) were determined for the three bacterial species by using the E-test (AB BIODISK) according to the manufacturer's instructions.

The median age of the participants (n = 115) was 22 years (range, two months to 72 years); 5% (n = 5) were infants, 31% (n = 36) were up to ten years old, 18% (n = 21) were between 11 and 19 years old, and 46% (n = 53) were with 20 years old or more. Sixty-seven (58%) inhabitants were male and 48 (42%)

were female. The overall carriage rates were 8% (9/115) for *N. meningitidis*, 6% (7/115) for *N. lactamica*, and 6% (7/115) for *S. pneumoniae*. There has not been observed mixed infection in the samples collected from the nasopharynx. In the meantime, different rates were identified according to the group examined with throat swabs. *N. meningitidis* carriage rate in the affected family was 20% (6/30), whilst in the closest neighbouring family was 17% (1/6) and in the villagers was 3% (2/79); 67% (n = 6) were adults with 19 to 56 years old and 33% (n = 3) were children with 4 to 10 years old. The different proportions of carriers found in the household contacts of the case and in the villagers were statistically significant (Yates $\chi_2 = 7.36$; p < 0.01). All *N. meningitidis* strains expressed a capsular serogroup B. The only household member who used to share the same patient's bedroom and one villager who had close contact with him were harbouring a *N. meningitidis* serogroup B. *N. lactamica* colonization, which is thought to be important in the development of meningococcal immunity, was found only in the villagers in a rate of 9% (7/79); 71% (n = 5) were between one and ten years old. *S. pneumoniae* colonization was found in 7% (2/30) of the immediate family of the case and in 6% (5/79) of the villagers; they were children aging from seven months to seven years.

The E-test for testing susceptibility of *N. meningitidis* did not show resistance to penicillin, chloramphenicol, ceftriaxone or ciprofloxacin. However, one strain was rifampicin-resistant (MIC > 32 µg/mL) and five showed resistance to sulfadiazine (MIC 64 to 256 µg/mL). All *N. lactamica* were resistant to sulfadiazine (MIC > 256 µg/mL) and three were penicillin-resistant (MIC 0.125 to 0.38 µg/mL); however they were susceptible to ceftriaxone (MIC 0.002 to 0.003 µg/mL). Amongst the *S. pneumoniae* carrier isolates, one was resistant to erythromycin (MIC > 256 µg/mL) and four were relatively resistant to penicillin (MIC 0.125 to 0.19 µg/mL) with 1 µg oxacillin disk (Oxoid CT 159) inhibition zone between 14 to 17 mm. In spite of all *S. pneumoniae* penicillin-resistant strains were susceptible to ceftriaxone, the MIC were relatively high (range, 0.094 to 0.125 µg/mL).

Discussion

The carriage rates found for the three species in the villagers were similar as previously reported for the general population elsewhere, with the same pattern of early acquisition in life [15,16]. Nevertheless, the carriage rate reported here for *N. meningitidis* in the immediate family of the patient is normally encountered in household contacts of a case and a few specific close contacts outside the domestic context [1,3,12,16,17]. Besides that, there is a high rate of carriage of the pathogenic strain of *N. meningitidis* in patients' household members, which makes the benefit of chemoprophylaxis only marginal to other contacts [3,17]. For this reason selective chemoprophylaxis was chosen to the villagers and closest neighbouring family [18]. Although less probable, the acquisition of the disease-causing strain by the patient during the time his spent in the village can not be

discarded based only on the carriage rates. The presence of highly rifampicin-resistant *N. meningitidis* may soon hinder the administration of this antibiotic for prophylaxis in that area. The identification of penicillin-resistant *N. lactamica* has been found since the late 1970s as a suspected source (presumably by genetic transformation) of penicillin resistance within the genus *Neisseria* [19], with its presence now identified for the first time into Brazil. Also the isolation of penicillin-resistant *S. pneumoniae* from carriers may complicate the treatment of meningitis patients and point to the need of antibiotic resistance survey for meningeal pathogens in the Amazon.

Seven days after the patient died, the case was notified as suspected meningococcal disease (A39.9, ISCD-10) based on the clinical criteria [20] and other evidences found in the field. The presence of a petechial-purpuric rash in this setting should suggest meningococcal disease, which in this case has been favoured by the high prevalence of *N. meningitidis* carriage rate in the household members [6,7]. Many other conditions may cause acute fever with vasculitic rash and impaired consciousness into this country, like aetiologies rarely involved with this presentation – *S. pneumoniae*, *Haemophilus influenzae*, *Staphylococcus aureus*, and echovirus type 9 – or aetiologies presenting a later rash (4th - 6th day) in the course of the disease – group *Rickettsia* species, dengue viruses, and other various viral haemorrhagic fevers –, many times with a different presentation and outcome [6,7,10,11,21-23]. The most significant point to identify a meningococcal aetiology is a suggestive rash, which is a common feature of *N. meningitidis* invasive disease – meningitis and/or septicaemia – appearing on the first to second day of disease in 50 to 70% of reported cases [8,12,13,24,25]. Therefore, the early recognition of a petechial rash is fundamental to improve the outcome, as well as other features of acute meningitis, the most frequent presentation of meningococcal disease [13,21,24].

The Amazon is a malaria-endemic area and bacterial infections often complicate severe malaria. This is an additional problem to epidemiological surveillance because cerebral malaria is not easily distinguishable from bacterial meningitis and viral encephalitis. Lumbar puncture should be seriously considered in patients with clinically diagnosed cerebral malaria, even when *Plasmodium* parasitemia is detected because it does not exclude coexisting bacterial meningitis [7,22,26]. The epidemiological surveillance of bacterial meningitis in remote areas demands a diagnostic technology suitable for confirmation, where conditions of collection and transport are not always adequate [25]. Also the absence of reliable laboratories for culture and strain identification hinders microbiological surveillance outside the capital. The implementation of PCR assays for diagnostic purposes at a central level become absolutely essential to detect the most common etiologic sources of bacterial meningitis into the Amazon. Information about the disease must be given out in

an attempt to improve the prognosis, including early treatment with parenteral antibiotics and training of the communities' health agents to recognize a suggestive rash. In that forest land, short-course treatment protocols and antibiotics with simple treatment schedules with the possibility of intramuscular injection for prior antibiotic therapy are necessary [3]. One daily dose of ceftriaxone (100 mg/Kg to a maximum of 4 g) administered intramuscularly seems to be a suitable option for the treatment of meningococcal disease and bacterial meningitis taking into account the circumstances found in Amazon inlands, its efficacy, and ease of use [27,28]. The occurrence of meningococcal disease in rural communities in the Amazon Region represents a public health challenge to decisions that are made regarding case ascertainment, outcome, and control of linked cases.

Acknowledgments

We want to thank the Staff of the Coari City Department of Health, in particular Dr. Alexandre M.G. Silva and Dr. Anderson C. Soares for their kind assistance, support and collaboration. We appreciate the local technical support of Prof. Joaquim M. Ferreira, Amazon Federal University, Coari and Dr. Sérgio L.B. Luz, Leônidas & Maria Deane Research Center, Manaus, State of Amazonas. Many thanks to Dr. Leila Melo Brasil of the Manaus City Department of Health for providing the epidemiological surveillance data.

References

- Greenfield S., Sheeche P.R., Feldman H.A. Meningococcal carriage in a population of "normal" families. *J Infect Dis* **1971**;12:67-73.
- Caugant D.A., Høiby E.A., Magnus P., et al. Asymptomatic carriage of *Neisseria meningitidis* in a randomly sampled population. *J Clin Microbiol* **1994**;32:323-30.
- Stephens D.S. Conquering the meningococcus. *FEMS Microbiol Rev* **2007**;31:3-14.
- Wall R.A., Hassan-King M., Thomas H., Greenwood B.M. Meningococcal bacteremia in febrile contacts of patients with meningococcal disease. *Lancet* **1986**;ii:624.
- Betrosian A.P., Berlet T., Agarwal B. Purpura fulminans in sepsis. *Am J Med Sci* **2006**;332:339-45.
- Scheld W.M. Meningococcal diseases. In KS Warren, AAF Mahmoud, *Tropical and Geographical Medicine*, McGraw-Hill, New York, **1990**:798-814.
- Greenwood B.M. Meningococcal disease. In GT Strickland, *Hunter's Tropical Medicine*, WB Saunders, Philadelphia, **1991**:385-92.
- Hazelzet J.A. Diagnosing meningococemia as a cause of sepsis. *Pediatr Crit Care Med* **2005**;6:50-4.
- Ministério da Saúde. Vigilância epidemiológica das doenças transmissíveis **2007**. Available from <http://www.saude.gov.br/saude>.
- Nogueira S.A. Dengue. *J Pediatr* **1999**;75:S9-14.
- De Figueiredo R.M., Thatcher B.D., de Lima M.L., et al. Exanthematous diseases and the first epidemic of dengue to occur in Manaus, Amazonas State, Brazil, during 1998-1999. *Rev Soc Bras Med Trop* **2004**;37:476-9.
- Barroso D.E., Pedro L.G.F., Machado S.C. Doença meningocócica. In Coura JR, *Dinâmica das Doenças Infecciosas e Parasitárias*, Guanabara Koogan, Rio de Janeiro, **2005**:1449-69.
- Thompson M.J., Ninis N., Perera R., et al. Clinical recognition of meningococcal disease in children and adolescents. *Lancet* **2006**;367:397-403.

14. Kaijalainen T., Rintamäki S., Herva E., Leinonen M. Evaluation of gene-technological and conventional methods in the identification of *Streptococcus pneumoniae*. *J Microbiol Methods* **2002**;51:111-8.
15. Garcia-Rodriguez J.A., Fresnadillo M.J. Dynamics of nasopharyngeal colonization by potential respiratory pathogens. *J Antimicrob Chemother* **2002**;50:S59-73.
16. Trotter C.L., Gay N.J., Edmunds W.J. The natural history of meningococcal carriage and disease. *Epidemiol Infect* **2006**;134:556-66.
17. Kristiansen B.E., Tveten Y., Jenkins A. Which contacts of patients with meningococcal disease carry the pathogenic strain of *Neisseria meningitidis*? A population based study. *BMJ* **1998**;317:621-25.
18. Kristiansen B.E., Tveten Y., Ask E., et al. Preventing secondary cases of meningococcal disease by identifying and eradicating disease-causing strains in close contacts of patients. *Scand J Infect Dis* **1992**;24:165-73.
19. Lujan R., Zhang Q.Y., Saez Nieto J.A., et al. Penicillin-resistant isolates of *Neisseria lactamica* produce altered forms of penicillin-binding protein 2 that arose by interspecies horizontal gene transfer. *Antimicrob Agents Chemother* **1991**;35:300-4.
20. Fundação Nacional de Saúde. Meningites. Guia de Vigilância Epidemiológica, Ministério da Saúde, Brasília, **2005**:531-59.
21. Brogan P.A., Raffles A. The management of fever and petechiae: making sense of rash decisions. *Arch Dis Child* **2000**;83:506-7.
22. Owusu-Ofori A., Agbenyega T., Ansong D., Scheld W.M. Routine lumbar puncture in children with febrile seizures in Ghana: should it continue? *Int J Infect Dis* **2004**;8:353-61.
23. Chadwick D., Arch B., Wilder-Smith A., Paton N. Distinguishing dengue fever from other infections on the basis of simple clinical and laboratory features: application of logistic regression analysis. *J Clin Virol* **2006**;35:147-53.
24. Toews W.H., Bass J.W. Skin manifestations of meningococcal infection: an immediate indicator of prognosis. *Am J Dis Child* **1974**;127:173-6.
25. Pedro L.G.F., Boente R.F., Madureira D.J., et al. Diagnosis of meningococcal meningitis in Brazil by use of PCR. *Scand J Inf Dis* **2007**;39:28-32.
26. Berkley J.A., Mwangi I., Mellington F., et al. Cerebral malaria versus bacterial meningitis in children with impaired consciousness. *Quart J Med* **1999**;92:151-7.
27. Scholtz H., Hofmann T., Noack R., et al. Prospective comparison of ceftriaxone and cefotaxime for the short term treatment of bacterial meningitis in children. *Chemotherapy* **1998**;44:142-7.
28. Nathan N., Borel T., Djibo A., et al. Ceftriaxone as effective as long-acting chloramphenicol in short-course treatment of meningococcal meningitis during epidemics: a randomised non-inferiority study. *Lancet* **2005**;366:308-13.