



CASE REPORT

Maternal SARS-CoV-2 Infection Associated to Systemic Inflammatory Response and Pericardial Effusion in the Newborn: A Case Report

Andressa R. O. Lima,^{1a} Cynthia C. Cardoso,^{2a} Priscilla R. B. Bentim,¹ Carolina M. Voloch,² Átila D. Rossi,² Raissa Mirella M. S. C. da Costa,^{2,3} Juliana Aparecida S. da Paz,³ Rafael F. Agostinho,⁴ Valéria R. F. S. Figueiredo,⁴ Jarba S. S. Júnior,⁵ Luiz G. P. de Almeida,⁶ Alexandra L. Gerber,⁶ Clarissa A. Abuassi,⁷ Natalia F. Rodrigues,⁸ Amílcar Tanuri,² Patricia T. Bozza,⁸ Cesar S. Bastos,⁷ Ana Tereza R. de Vasconcelos,⁵ Stella Beatriz Kruger,⁵ Giovanna Geórgia P. C. A. Vallim,¹ Roberto J. Nishihara,¹ Shana Priscila C. Barroso,³ and Alexandre Morrot^{9,10}

¹Neonatal Intensive Care Unit, Pediatric Clinic, Naval Hospital Marcílio Dias—Brazilian Navy, Rio de Janeiro, RJ, Brazil, ²Departamento de Genética, Instituto de Biologia, Universidade Federal do Rio de Janeiro, Rio de Janeiro, RJ, Brazil, ³Biomedical Research Institute, Naval Hospital Marcílio Dias—Brazilian Navy, Rio de Janeiro, RJ, Brazil, ⁴Pediatrics Clinic, Naval Hospital Marcílio Dias—Brazilian Navy, Rio de Janeiro, RJ, Brazil, ⁵Obstetrics Department, Naval Hospital Marcílio Dias—Brazilian Navy, Rio de Janeiro, RJ, Brazil, ⁶Laboratório de Bioinformática, Laboratório Nacional de Computação Científica, Petrópolis, RJ, Brazil, ⁷Pathological Anatomy Laboratory, Naval Hospital Marcílio Dias—Brazilian Navy, Rio de Janeiro, RJ, Brazil, ⁸Immunopharmacology Laboratory, Oswaldo Cruz Institute, Rio de Janeiro, RJ, Brazil, ⁹Faculty of Medicine, Federal University of Rio de Janeiro, Rio de Janeiro, RJ, Brazil, and ¹⁰Laboratory of Immunoparasitology, Oswaldo Cruz Institute, Rio de Janeiro, RJ, Brazil

Vertical transmission of SARS-CoV-2 has already been described, while clinical consequences to the fetus are still under investigation. This article reports a case of systemic fetal inflammatory response and pericardial effusion. As far as is known, this is the first case of fetal/neonatal cardiac complications related to SARS-CoV-2 infection.

Key words. COVID-19; pericardial effusion; severe acute respiratory syndrome coronavirus 2; vertical transmission.

INTRODUCTION

The emergence and rapid spread of the new coronavirus SARS-CoV-2 have become a worldwide public health problem. On March 2020, the “Coronavirus Disease-2019” (COVID-19) was classified as a pandemic. Transmission of SARS-CoV-2 mostly occurs between people through respiratory droplets, although alternative routes have also been suggested [1].

Pregnant women and newborns are considered groups of greater attention in viral epidemic situations. Recently, a case of transplacental transmission of SARS-CoV-2 with neurological manifestations in the neonate was reported, confirming the potential for vertical transmission route [2].

This report, briefly, informs about the case of a 27-year-old woman admitted to the hospital at 32 weeks of gestation with SARS-CoV-2 infection. We describe for the first time in the literature a case of fetal pericarditis due to SARS-CoV-2 maternal transmission, accompanied by systemic inflammatory profile.

CASE REPORT

Mother: 27 years old, second pregnancy, blood group O, Rh positive, without comorbidities, performed prenatal care with no complications, negative serologies, sterile urine culture, and without changes in morphological ultrasound and nuchal translucency. She presented with flu-like symptoms in the 29th week of gestation, during the SARS-CoV-2 pandemic, and received symptomatic treatment. At 32 weeks and 4 days, the fetal echocardiogram performed routinely in the prenatal period revealed significant pericardial effusion with dilation of the vena cava, which demonstrates an overload in the cardiovascular system. Thus, interruption of pregnancy was recommended. During the hospitalization, the mother underwent corticosteroid therapy to prevent hyaline membrane disease in the baby after birth. Maternal blood was negative for a panel of agents that may cause fetal pericardial effusion, such as parvovirus, Epstein-Barr virus, adenovirus, and influenza A and B, while a rapid serological test for SARS-CoV-2 showed both reagents Immunoglobulins IgM and IgG. The fetal echocardiogram was repeated after 6 days and an increase in the volume of the pericardial effusion was observed, suggesting a risk of fetal death from cardiac tamponade (Figure 1A).

An emergency cesarean section was performed at 33 weeks in an isolated operating room. The mother wore an N95 mask and immediate clamping of the umbilical cord was performed. The newborn had no contact with the mother at birth, being immediately taken to a radiant heat unit. The newborn, a female, was premature at 33 weeks and 4 days by the New Ballard Score and weighed 2400 g, which is suitable for gestational age.

Received 14 September 2020; editorial decision 23 October 2020; accepted 27 October 2020; Published online October 30, 2020.

^aThese authors contributed equally to this manuscript.

Corresponding Author: Cynthia C. Cardoso, PhD, Laboratório de Virologia Molecular, Instituto de Biologia, Universidade Federal do Rio de Janeiro, Av Carlos Chagas Filho 373, CCS, Bloco A, Sala 121, Cidade Universitária, Ilha do Fundão, Rio de Janeiro, 21941-902, Brasil. E-mail: cynthiac@biologia.ufrj.br.

Journal of the Pediatric Infectious Diseases Society 2020;XX(X):1–4

© The Author(s) 2020. Published by Oxford University Press on behalf of The Journal of the Pediatric Infectious Diseases Society. All rights reserved. For permissions, please e-mail: journals.permissions@oup.com.

DOI: 10.1093/jpids/piaa133

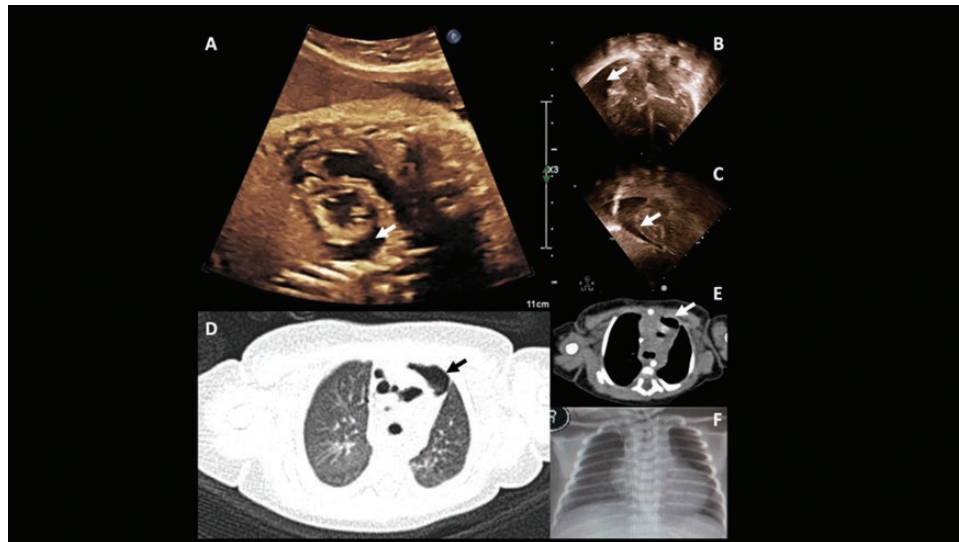


Figure 1. Fetal and postnatal echocardiogram and image exams. (A) Fetal echocardiogram at 32 weeks and 4 days. (B and C) postnatal echocardiogram showing no signs of cardiac tamponade. (D and E) Sagittal chest tomography images showing the “ground-glass pattern” of inflammatory infiltrate in lungs (D) and pericardial effusion at mediastinal region (E). (F) Chest X-ray showing well-expanded pulmonary parenchyma, without infiltrate. Tomography and X-ray images were obtained 2 hours after birth. The arrows indicate pericardial effusion.

She presented with apnea and bradycardia at birth, requiring neonatal resuscitation according to international guidelines. She responded well after a mask-bag ventilation cycle, with Apgar scores at 7 and 9 in the first and fifth minutes, respectively, maintaining a satisfactory respiratory drive. She was immediately transferred to a neonatal intensive care unit using a transport incubator, where a bedside echocardiogram was performed, confirming the pericardial effusion. No signs of cardiac tamponade were observed at that time (Figure 1B and C).

During the first hour of life, the newborn was cleaned and blood samples were obtained. The results of blood tests collected were satisfactory, and biochemical parameters were also considered normal (Supplementary Table S1). Nasal and oropharynx swabs were also collected, and reverse transcription polymerase chain reaction (RT-PCR) tests for SARS-CoV-2 were positive. A rapid serological test of cord blood and peripheral blood of the newborn was performed, and results were nonreactive for anti-SARS-CoV-2 IgM and reactive for IgG, as expected in the case of maternal infection. Blood culture and serology for toxoplasmosis, cytomegalovirus, rubella, herpes, hepatitis A, B, and C, anti-HIV, and Venereal Disease Research Laboratory (VDRL) were negative, as well as a complementary viral panel. Amniotic fluid and maternal blood samples were negative for SARS-CoV-2. The results of RT-PCR and serology tests are summarized in Supplementary Table S2.

Fragments from different placental regions were negative for SARS-CoV-2, while data obtained from chorion were inconclusive, with amplification of a single target (Supplementary Table S2). Histopathological analysis of the placenta showed mild and nonspecific circulatory changes, with varying sizes of

chorionic villi, intervening space with foci of calcification and hemorrhage, and deciduous with slight deposition of fibrin and fibrinoid necrosis in the wall vessels.

Two-hour-old patient was transferred to a referral service in pediatric cardiology for follow-up, and tests for cardiac enzymes and inflammatory markers such as D-dimer, ferritin, and serum transaminases were found altered (Supplementary Table S1). The *electrocardiogram* showed *sinus rhythm*. On the first day of life, RT-PCR tests for SARS-CoV-2 on peripheral blood were also positive.

Although the chest X-ray did not show clinical expression, a computed tomography scan showed an inflammatory ground-glass pattern affecting less than 25% of the lung parenchyma, remaining under clinical surveillance (Figure 1D and F).

On the third day of life, the newborn evolved with hemodynamic instability, bradycardia, respiratory discomfort, and apnea associated with metabolic acidosis (pH = 7.12, pCO₂ = 45, pO₂ = 107, HCO₃ = 15, BE = 13.7, O₂ saturation = 96%, and lactate = 12.4). After sedation, orotracheal intubation combined with invasive mechanical ventilation support, pericardiocentesis, and amine administration in continuous infusion was performed. Empirical antibiotic therapy with Ampicillin and Gentamicin was also started. Twenty-eight milliliters of pericardial fluid were drained, and it showed a cloudy aspect, cytology content of 350 cells (11% polymorphonuclear and 89% mononuclear cells), and 8900 red blood cells. Biochemistry analysis of the fluid revealed glucose dosage of 118 mg/dL, 3.2 protein mg/dL, 530 LDH lactate dehydrogenase activity, and negative bacterioscopy. RT-PCR for SARS-CoV-2 and viral panel was negative.

The pericardial drain was removed after 24 hours, along with sedation, and a new echocardiogram showed resolution of

pericardial effusion. The newborn was transferred to the Neonatal Unit at the place of birth when she was 5 days old, still under invasive mechanical ventilation. Nasal and oropharyngeal swabs and blood samples remained positive for SARS-CoV-2 at that time (Supplementary Table S2). Results of a cytokine panel indicated increased plasma levels of proinflammatory cytokines such as interleukin (IL)-1 β , interferon- γ , IL-6, and tumor necrosis factor α in the newborn's sample when compared with the mother. High levels of IFN- γ and IL-6 were observed in pericardial fluid (Supplementary Table S3). In brief, the patient presented changes in cardiac enzymes, D-dimer, ferritin, and serum transaminases, in addition to proinflammatory cytokines that, associated with the clinical picture and the presence of pericardial effusion, showed a systemic inflammatory response.

SARS-CoV-2 RNA obtained from the newborn oropharyngeal sample collected 1 hour after birth was sequenced using Illumina Platform, and 88% of the viral genome was covered. The consensus sequence was aligned to reference genome NC_045512.2 and classified as lineage B. The mutation Asp614Gly was identified in the region of the S gene. Phylogenetic analysis revealed that the sequenced genome falls within one of the Brazilian transmission clusters (Supplementary Figure S1).

At 5 days of life, the patient presented generalized hypotonia, even without sedation, and a worsening of the infection associated with the use of invasive devices such as pericardial drain and deep venipuncture. Therefore, antibiotic therapy was modified to Cefepime and Vancomycin after the collection of a new blood culture. Thyroid hormone tests were conducted on the newborn and showed to be within normal limits (Supplementary Table S1). A neonatal screening test was performed (heel prick test) and, shortly thereafter, the patient received red blood cell concentrate due to low hematimetric levels. After 2 days, on the seventh day of life, she was already more active, and programmed extubation was performed. Patient was coupled to noninvasive ventilation, evolving from respiratory weaning to nasal Continuous Positive Airway Pressure CPAP and ambient air. Transfontanelar and total abdominal ultrasounds were performed, in addition to a new echocardiogram, and normal patterns were observed. Sucking was stimulated and the mother's breast was allowed with hygiene measures and the use of a mask by the mother. Nasal and oropharyngeal swabs collected from newborn on the 13th and 14th days of life were negative for SARS-CoV-2 (Supplementary Table S2), and contact isolation was suspended. Patient was discharged at 22 days of life, weighing 2405 g.

DISCUSSION

Vertical transmission of SARS-CoV-2 has been investigated in case reports and case series studies, and the transplacental transmission route has recently been confirmed [2]. Nevertheless, literature data regarding the clinical consequences of SARS-CoV-2 infection for the fetus and newborn are still limited. Mild

symptoms are usually observed, although cases of pneumonia, respiratory distress, abnormal liver function, and even death have also been reported [3]. Recently, a single case of neurologic damage after intrauterine infection by SARS-CoV-2 was also described [2]. In this study, we report a case of vertical transmission confirmed by the detection of the SARS-CoV-2 RNA in the newborn's nasal cavity, oropharynx, and blood shortly after birth. Unlike other studies, the symptoms of the newborn were critical, with severe inflammatory response evidenced by the presence of pericardial effusion. The virus was not detected in the pericardial fluid, suggesting that tissue damage results from inflammatory response. Pulmonary involvement was detected by tomography, which showed signs of a ground-glass aspect. The mother presented positive serology and signs of a controlled inflammatory response.

A phylogenetic analysis showed that the SARS-CoV-2 genome sequence obtained falls within one of the Brazilian transmission clusters [4]. The substitution detected at S protein is commonly observed in sequences from European countries and Brazil. Although residue 614 does not directly interact with SARS-CoV-2 receptor Angiotensin-converting enzyme 2 (ACE2) ACE2 or cellular proteases, a possible role in the protein S stability cannot be ruled out [5].

Herein, we report the first case of neonatal pericarditis and systemic inflammatory response after maternal infection with SARS-CoV-2. The lack of significant variations in the SARS-CoV-2 genome suggests that clinical complications are probably attributed to host-related factors.

Supplementary Data

Supplementary materials are available at the *Journal of The Pediatric Infectious Diseases Society* online (<http://jpids.oxfordjournals.org>). Supplementary materials consist of data provided by the author that are published to benefit the reader. The posted materials are not copyedited. The contents of all supplementary data are the sole responsibility of the authors. Questions or messages regarding errors should be addressed to the author.

Notes

Acknowledgments. We thank Thais Giangiarulo, Jéssica Oliveira, Raissa Costa, Samila Ferreira, Juliana Paz, Tailah Almeida, and Ana Paula C. Guimarães for technical assistance.

Financial support. This work was supported by Fundação Carlos Chagas Filho de Amparo à Pesquisa do Estado do Rio de Janeiro (FAPERJ) (grant numbers: E-26/202.791/2019 to C.C.C., E-26/010.000168/2020 to S.P.C.B., and E-26/210.179/2020 and E-26/202.826/2018 to A.T.R.V.) and the Brazilian National Council of Scientific and Technological Development (CNPq) (grant number 303170/2017-4 to A.T.R.V.).

Potential conflicts of interest. All authors: No reported conflicts. All authors have submitted the ICMJE Form for Potential Conflicts of Interest. Conflicts that the editors consider relevant to the content of the manuscript have been disclosed.

References

1. World Health Organization. Report of the WHO-China Joint Mission on Coronavirus Disease 2019 (COVID-19) 16–24 February 2020. Geneva; 2020. Available at: [https://www.who.int/news-room/commentaries/detail/modes-of-](https://www.who.int/news-room/commentaries/detail/modes-of)

[transmission-of-virus-causing-covid-19-implications-for-ipc-precaution-recommendations](#). Accessed 20 July 2020.

2. Vivanti AJ, Vauloup-Fellous C, Prevot S, et al. Transplacental transmission of SARS-CoV-2 infection. *Nat Commun* **2020**; 11:3572.
3. Zeng L, Xia S, Yuan W, et al. Neonatal early-onset infection with SARS-CoV-2 in 33 neonates born to mothers with COVID-19 in Wuhan, China. *JAMA Pediatr* **2020**; 174:722–5.
4. Candido DS, Claro IM, de Jesus JG, et al.; Brazil-UK Centre for Arbovirus Discovery, Diagnosis, Genomics and Epidemiology (CADDE) Genomic Network. Evolution and epidemic spread of SARS-CoV-2 in Brazil. *Science* **2020**; 369:1255–60.
5. Maitra A, Sarkar MC, Raheja H, et al. Mutations in SARS-CoV-2 viral RNA identified in Eastern India: possible implications for the ongoing outbreak in India and impact on viral structure and host susceptibility. *J Biosci* **2020**; 45:76.