

On a rare type of necrosis of the liver

by

Dr. C. Magarinos Torres.

(With plate 32).

Following Dr. B. C. CROWELL's advice and instructions, I made a study of some anatomical lesions of the liver found during an autopsy which are comparatively rare.

Necrosis of the liver may be central or focal. In focal necrosis, there are small necrotic areas in the hepatic lobules, which are not in direct relation with the central vein; this type is found in acute infectious diseases such as pneumonia, yellow fever, eclampsia, scarlet fever and diphtheria. These lesions are sometimes of infectious and sometimes of toxic origin.

In central necrosis, the lesions surround the central vein of the lobule and are due to toxic conditions. This kind of necrosis is often observed in certain infectious diseases, and also in some other cases; it is found, for instance, in acute yellow atrophy of the liver and also in chloroform poisoning. Central necrosis with hemorrhage is found in some cases of chronic passive congestion. In a recent paper on chronic passive congestion, LAMBERT and ALLISON (1) indicate the following five types of lesions:

A) dilatation of the capillaries with atrophy of the central cells of the lobules:

B) central degeneration with or without dilatation of the capillaries:

(1)—LAMBERT, R. A. and ALLISON, B. R.—Types of Lesion in Chronic Passive Congestion of the Liver (Illustrated).

Bull. of the John Hopkins Hosp. 1916. XXVII. 350.

C) marked fatty infiltration in the cells around the hepatic vein, with congestion of the middle zone:

D) central necrosis with hemorrhage:

E) Cirrhosis of cardiac origin.

I shall have to refer to some of these types of lesions while describing the present case, though strictly speaking, these types were not found in our case.

It is not difficult to observe our type of necrotic lesion in experimental conditions and it is often found in other organs at post-mortem examinations; it has no apparent connection with the limits of the lobules, and is associated with a relatively slight inflammatory reaction.

Microscopic preparations revealed thrombosis of some capillaries of the liver caused by long, thick, rectilinear or slightly curved, Gram-positive bacilli without spores or capsules (*Bacterium coli*?). These capillaries were found more or less in the centre of the necrotic areas, but some were found in the liver tissue not necrosed.

The liver is enlarged and macroscopically the appearance of the lesion is quite peculiar. (Plate 32, Fig. 2).

The lesions may be partly explained by the bacterial thrombosis of the capillaries, if one supposes also the existence of a toxin

chronic passive congestion due to compression of the vena porta by a much enlarged lymphatic gland of the hilus of the liver must also be taken into account.

The process was evidently acute and recent, the subject being a young male, 22 years old, whose clinical history is unknown.

The autopsy was made 10 hours after death.

From the protocol we extracted the liver description and the anatomic diagnosis.

Liver—Liver enlarged; left edge in contact with the left abdominal wall covering the stomach, spleen and left kidney.

Weight 3.200 grs.

A lymphatic gland enlarged to about the size of a hen's egg envelops the common bile duct like a short sleeve; it is yellowish and soft. On section the pulp is found to be yellowish and gelatinous.

Bile ducts perfectly permeable, not compressed by the above-mentioned gland.

Liver surface reddish brown, capsule smooth, transparent, shining. On the antero-superior surface some white lines ramified like branches, which form a net with large meshes. In certain parts of the surface, small yellowish confluent spots with clear edges can be seen through the capsule; their diameter is about 3 or 4 mm.

General color of surface of section dark brownish-red. Lobular outlines indistinct; connective tissue not increased.

There are small confluent yellowish areas of different sizes, the largest 3 or 4 mm. in diameter, the smallest hardly visible distributed over the whole of the liver, but especially in certain regions around the capsule. Hepatic tissue around these areas, and all over the liver, dark brownish red in color.

After fixing in 10% formol, the specimens changed from the general brownish red color, when fresh, to a more or less marked brown. After the piece was fixed the small foci of necrosis became more distinct, looking like small opaque spots of a light yellowish-green color, the larger ones

measuring 2-3 mm. in diameter, neither prominent nor depressed. (Plate 32, Fig. 2). The hepatic tissue forms a slender ring of more accentuated brown color (congestion) than the rest of the tissue.

In some places, there are 2 or 3 small foci almost touching each other, the zone of hepatic tissue that separates them not being more than 2 or 3 mm. wide; about 3 or 4 cms. from such a group one finds other similar groups. The distribution of the lesions is thus irregular; in certain regions, chiefly around the capsule, the kind of group just described; in other regions mostly in central part of the organ, the foci are fewer, and appear as isolated spots in the midst of the dark brownish mass of the liver tissue, (dark brownish-red when fresh).

Anatomic diagnosis:

Icterus.

Hyperplasia, hyperaemia et necrosis hepatis.

Hyperplasia nodorum lymphaticorum hepaticarum et lumbarum.

Nephritis parenchymatosa chronica.

Hypertrophia et dilatatio ventriculi sinistri.

Oedema pulmonum.

Pleuritis chronica adhaesiva.

Leptomeningitis chronica, (syphilis?).

Hypoplasia lienis.

Microscopic description

Fragments of the liver, in which the lesions were very marked, were removed at the time, fixed in ZENKER-FORMOL (ZENKER'S LIQUID without acetic acid).

The paraffin sections were stained by hematoxylin-eosin; other fragments were fixed in 10% formol and stained by Scharlach R-hematoxylin.

Some of the lesions were distributed over the whole liver, others were focal lesions.

A) Focal lesions

I will describe two of the most typical of these lesions, of which there are many variations, some of them representing more,

and others less advanced stages of the same process.

Ist. Aspect.

These lesions have distinct outlines. (Plate 32, Fig. 1). They are round shaped and coincide with the hepatic lobules, in the centre of which is the efferent vein.

Often two or three of these lesions merge into one another, so that the outline of one or more of the contiguous spaces disappears.

They look then like a badly made 8, or a roughly drawn bunch of grapes. In each zone may be distinguished a central spot and marginal ones.

a) Central part

The liver cells, blood corpuscles, capillary endothelium and migratory cells become necrotic.

The trabecules of REMAK which can be recognised, are decreased in number, the cells which form them are deeply stained by eosin, and become very distinctly outlined, their granular protoplasm contains vacuoles, the nucleus is hardly seen or not at all (karyolysis).

It is easier to identify the cells by their mutual relation than by their structure (Plate 32, Fig. 1). The capillary walls are unaltered and show a clear outline.

Between the capillary walls clearly outlined and the trabecules there is a clear space where are found a few migratory cells and spheric masses which eosin stains red, and which are cellular detritus.

The liver sinusoids are much enlarged and very unequally. The lumen is occupied by spherical vacuolated masses which do not take eosin or hematoxylin stains, some of them are blood and others migratory cells.

In some of the areas of necrosis, one or more capillaries are completely obstructed by bacilli. These thrombotic capillaries are found more or less in the centre of the lesion.

The bacilli are Gram-positive, long, thick straight or slightly curved. No capsule so

spores were noticed. Unfortunately, no cultures were made at the time of the autopsy; it is therefore impossible to identify them.

They are very much like *Bacterium-coli* in appearance and staining properties. I also found capillaries outside the area of necrosis in more or less well preserved hepatic tissue, containing masses of bacteria with the same characteristics.

b) Margins

The lesions just described are clearly limited on the outside by a narrow zone of tissue where the capillaries are very much dilated and full of blood cells which stain well with eosin; round them are many migratory cells and leucocytes with polymorphous nuclei (Plate 32, Fig. 1). This narrow zone serves as a dividing line or uninterrupted frame which separates the necrotic degenerate areas from the neighbouring hepatic tissues. The focal lesions just described are often if not always surrounded by the following ones.

2nd Aspect

When observed with a low power, some of the sections of this liver show zones where the sinusoids are very much dilated and full of blood corpuscles and liver cells in which are seen signs of regressive changes. Some of these zones are small and round. Most of them however form narrow bands which are several times as long as the microscopic field.

The relations between these lesions and the hepatic lobules are not clear. The only evident fact is that they are found far from the portal spaces, from which they are separated by a region in which the liver tissue has retained its structure comparatively well. This brusque contrast is one of the best characteristics of the lesions.

At the level of the above-mentioned zones, the protoplasm of the hepatic cells stains deeply with eosin; it is granular and contains 2 or 3 larger vacuoles as well as many small ones. The outline of the cells is very distinct. The nucleus of the cell oc-

cupies an excentric position in the protoplasm; it is oval and not very distinct; the details of its inner structure are not visible as it stains rather diffusely with hematoxylin (karyolysis).

There are a few other hepatic cells, the nuclei of which are no longer visible; the protoplasm of these cells is vacuolated and stains deeply with eosin; in the marginal zone there are large granules some of which are close together, whereas others are far apart; the cellular outline is interrupted in that point.

In other cells the protoplasmic disaggregation is more marked, and there are spots where the hepatic cells are only round masses which take a uniform reddish-pink color, when stained with eosin; they are small and are found in groups of three or four different sizes.

The arrangement of the cells in trabecules of REMAK is completely blurred by the necrosis of the liver-cells.

In the focal lesions just described, the hepatic cells are isolated, or are remnants of the trabecules of REMAK composed of 3, 4 or at most 5 contiguous cells, all of which have the above-described appearance.

The liver sinusoids are dilated and filled with red blood corpuscles and migratory cells.

The most characteristic feature is certainly the presence of a great number of migratory cells which surround and limit the capillaries. These cells are very active phagocytes, as can be seen by the large quantity of material accumulated inside their protoplasm.

The lesions above described have some affinity to the lesions found in chronic passive congestion. It is, however, impossible to include them in any of the five types described by LAMBERT and ALLISON.

I noticed, on the other hand, that this type is always present in sections where the first aspect is found, or in sections which include bacterial thrombosis of the capillaries.

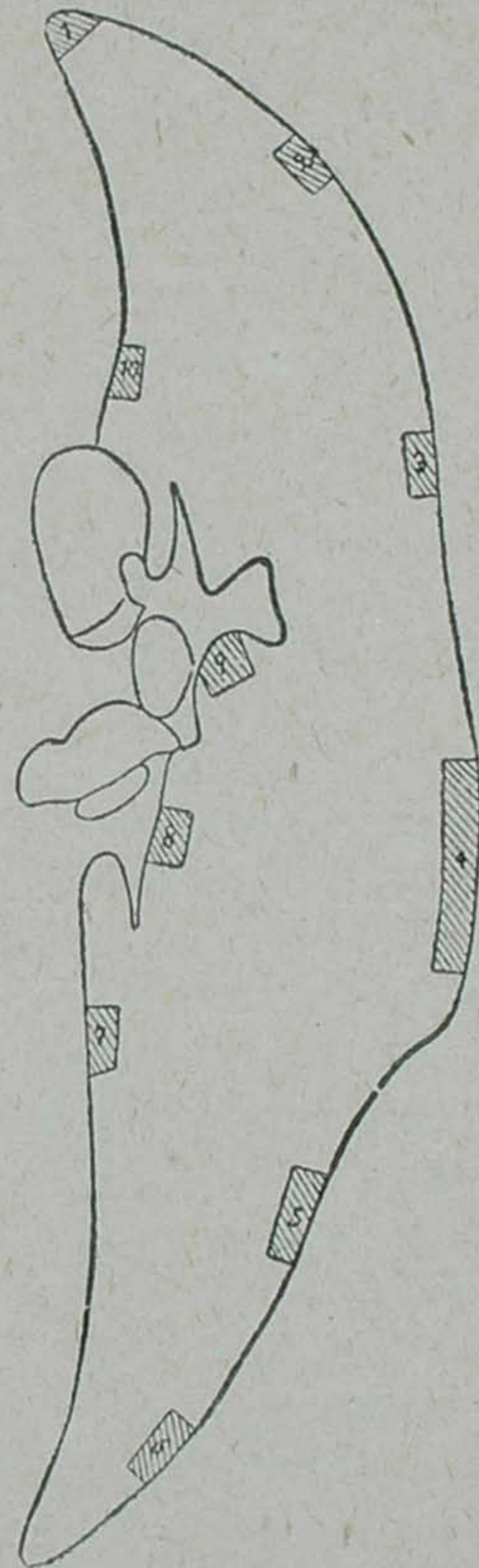
The lesions of chronic passive congestion found all over the liver make the characteristics of this type of lesion very un-

decided indeed.

B) Diffuse lesions.

Some of the types of chronic passive congestion described by LAMBERT and ALLISON were found all over the liver.

Pieces removed from the liver which is now in the Anatomical Museum of the Instituto Oswaldo Cruz, account for the distribution of the lesions (v. diagram). This specimen comprises a longitudinal section of the whole liver, passing more or less through the middle of the antero-superior surface.



Block 1: chronic passive congestion (central degeneration with or without dilatation of capillaries).

Block 2: Chronic passive congestion (dilatation of the capillaries with atrophy of the cells of the centre of the lobule).

Block 3: Acute diffuse hepatitis (1st and 2nd aspects). Chronic passive congestion (dilatation of the capillaries with atrophy of the central cells of the lobule).

Block 4: Chronic passive congestion (dilatation of the capillaries with atrophy of the central cells of the lobule and central degeneration, with or without dilatation of the capillaries).

Block 5: Thrombosis of a capillary by masses of bacteria (bacilli). Chronic passive congestion (dilatation of the capillaries with atrophy of the cells in the centre of the lobules and central degeneration, with or without dilatation of the capillaries).

Block 6: Thrombosis of a capillary by masses of bacteria (bacilli). Chronic passive

congestion (dilatation of the capillaries with atrophy of the cells in the centre of the lobules).

Block 7: Acute diffuse hepatitis (2nd aspect). Chronic passive congestion (dilatation of the capillaries, with atrophy of the cells of the centre of the lobules and central degeneration, with or without dilatation of the capillaries).

Blocks 8 & 9: Chronic passive congestion.

Block 10: Acute diffuse hepatitis (1st. & 2nd. aspects) and thrombosis of the capillaries by bacteria (bacilli). Chronic passive congestion.

We would here tender our most sincere thanks to Dr. B. C. CROWELL, under whose direction this work was carried out, for his patient instructions and kind advice.

Explanation to Plate 32.

Fig. 1--Section through liver, haematoxylin-eosin stain.

Acute diffuse hepatitis (1rst aspect).

The areas coincide with the hepatic lobules; in the centre of the latter the efferent vein.

The trabecules of REMAK are reduced in number and constituted by necrosed cells; the clearly outlined lighter spaces between the cells re-

present dilated capillaries with necrotic migratory cells and blood corpuscles.

Round the focus of necrosis a narrow inflammatory zone.

Fig. 2. -- Macroscopic appearance of lesion.

Circular or oval areas of a light yellowish-green, neither prominent nor depressed, round which the hepatic tissue constitutes a narrow ring a pronounced brownish tint.