



Diffusion tensor imaging metrics in diagnosis of HTLV-1-associated myelopathy

Sheila N. F. Liberato de Matos^{1,2} , Giovanna Ladeia-Rocha³, José Abraão Carneiro Neto¹, Cassius J. V. de Oliveira¹, César Araújo Neto³, Lúcia Passos¹, Jamary Oliveira-Filho^{4,5} & Edgar M. Carvalho^{1,6,7} 

¹Immunology Service, Professor Edgard Santos University Hospital, Federal University of Bahia, Salvador

²UniFTC, Salvador, Bahia, Brazil

³Image Memorial/DASA, Salvador, Bahia, Brazil

⁴Neurology Service, Professor Edgard Santos University Hospital, Salvador, Bahia, Brazil

⁵Instituto de Ciências da Saúde, Federal University of Bahia, Salvador, Bahia, Brazil

⁶Laboratório de Pesquisas Clínicas (LAPEC), Instituto Gonçalo Moniz, FIOCRUZ, Salvador, Bahia, Brazil

⁷National Institute of Science and Technology in Tropical Diseases (INCT-DT), CNPq, Brazil

Correspondence

Edgar M. Carvalho, Instituto Gonçalo Moniz (FIOCRUZ-BA), Rua Waldemar Falcão, 121, Candeal - Salvador/BA, CEP: 40296-710. Tel. (71) 3176-2356; E-mail: imuno@ufba.br

Received: 21 December 2021; Revised: 31 January 2022; Accepted: 31 January 2022

Annals of Clinical and Translational Neurology 2022; 9(0): 488–496

doi: 10.1002/acn3.51521

Abstract

Objective: In the diagnosis of HTLV-1-associated myelopathy (HAM), while magnetic resonance imaging (MRI) is essential to exclude other diseases, its power is limited regarding HAM diagnosis, as only 30% of affected patients present with spinal cord atrophy. Diffusion tensor imaging (DTI) may enable the detection of damage in the white matter microstructure. Here, we quantitatively assess spinal cord damage using DTI and evaluate conventional MRI parameters of the spinal cord in HTLV-1-infected individuals. **Methods:** This cross-sectional study involved 33 HTLV-1 carriers, 28 patients with definite-HAM, and 11 seronegative healthy subjects (HS). Region-of-interest (ROI)-based fractional anisotropy (FA) and mean diffusivity (MD) measurements were performed in the upper thoracic and lumbar regions of the spinal cord. Thoracic index was defined as $1/(\text{anteroposterior diameter} \times \text{transverse diameter})$ measured at the fifth 5th vertebral level. Receiver operating characteristic (ROC) curve analysis was used to determine optimal cutoff FA, MD, and thoracic index values. **Results:** Spinal cord atrophy was observed in 15 (53.6%) patients with definite-HAM. The area under the ROC curve in the thoracic spinal cord was 0.824 (95% CI, 0.716–0.932), 0.839 (95% CI: 0.736–0.942), and 0.838 (95% CI: 0.728–0.949) for FA, MD, and the thoracic index, respectively. Lower FA and higher MD values were observed in the definite-HAM group compared to HTLV-1 carriers and HS at the T5 vertebral level ($p < 0.01$). **Interpretation:** Complementary to conventional MRI, DTI analysis of the spinal cord and thoracic index determination can offer additional insight that may prove useful in the diagnosis of HAM.

Introduction

Human T-cell leukemia virus type 1 (HTLV-1) infection has afflicted 10 million people worldwide.¹ HTLV-1-associated morbidity is highly underestimated: While only 5% of infected individuals develop HTLV-1-associated myelopathy (HAM) or adult T-cell leukemia (ATL),² more than 50% of those not diagnosed with these conditions suffer from other related diseases or syndromes,

including HTLV-1-associated arthropathy, sicca syndrome, bladder dysfunction, erectile dysfunction, and infective dermatitis.^{3–5} Definite HAM is characterized by slowly progressive spastic paraparesis, which may initially present unilaterally, but invariably develops bilaterally, being associated with generalized hyperreflexia and extensor plantar reflex.⁶ Approximately 20% of HTLV-1-infected individuals without definite HAM may present bladder dysfunction, characterized by urinary urgency,

incontinence, and/or nocturia; in the absence of motor disability, these patients are classified as having probable HAM.^{4–6} Cerebrospinal fluid analysis and magnetic resonance imaging (MRI) of the spinal cord reveal no unique characteristics in patients with definite HAM, yet both are essential to exclude other diseases. Depending on the stage of disease, MRI may reveal an edematous, normal or atrophic spinal cord, with or without signal alterations.⁶ Neuropathological findings indicate that atrophy of the spinal cord seems to mainly occur in the antero-posterior direction.^{7,8} Most pathological alterations in HAM have been reported in the thoracolumbar cord.^{9,10} Spinal cord atrophy can be radiologically quantified^{8,9,11,12} and is the most common finding observed on conventional MRI. However, atrophy usually appears only years after the onset of disease.¹³ Moreover, the spinal cord is normal on MRI in up to 30% of patients presenting neurological findings compatible with definite HAM.¹²

Diffusion tensor imaging (DTI) combined with fiber tractography allows for the mapping and consequent evaluation of different tracts of white matter in the central nervous system.^{14,15} The DTI technique measures the diffusion of water molecules, describing movement in a three-dimensional space, thereby mapping directionality.¹⁶ The degree of anisotropy can be quantified by some measures, such as fractional anisotropy (FA) and mean diffusivity (MD).^{17,18} DTI-tractography of the spinal cord has been successfully used to evaluate subtle pathological abnormalities in cervical spondylotic myelopathy,¹⁹ monitor disease activity in patients with multiple sclerosis²⁰ and intramedullary tumors,^{21–23} and has been suggested as a possible tool to detect disease progression in patients with amyotrophic lateral sclerosis,²⁴ as well as to evaluate functional motor ability in patients with acute transverse myelitis.²⁵ The present study endeavored to quantitatively assess spinal cord alterations in HTLV-1-infected subjects using DTI and measures of anteroposterior and transverse diameters of the spinal cord.

Material and Methods

Study participants

The present cross-sectional study recruited 61 HTLV-1-infected subjects followed from 2 to 14 years at the Multidisciplinary HTLV-1 Clinic of the Prof. Edgard Santos University Hospital Complex, located in Salvador, Bahia-Brazil. All study subjects underwent recent neurological evaluations in 2020. HTLV-1 infection was diagnosed by positivity on serological enzyme-linked immunosorbent assay (ELISA) (Cambridge Biotech Corp., Worcester, MA, USA), with confirmation provided by western blot (HTLV blot, Genelab, Singapore). Of the 61 recruited

subjects, 33 were HTLV-1 carriers and 28 patients were diagnosed with definite HAM; 11 seronegative healthy subjects (HS) were also included. This study was approved by the Institutional Review Board of the Federal University of Bahia. All included participants freely agreed to participate and provided a written term of informed consent.

Case definition

The studied subjects were classified as either HTLV-1 carriers, that is, HTLV-1-infected individuals without neurological signs or symptoms, or infected patients with definite HAM.²⁶ Briefly, definite HAM is a non-remitting progressive spastic paraparesis in which sensory, urinary and anal sphincter signs or symptoms may or may not be present. All definite HAM cases presented an Osame motor disability score (OMDS) greater than 1, and other disorders that could mimic HAM were excluded. Seronegative controls were healthy workers who tested seronegative for HTLV-1 and did not present any signs or symptoms of neurological disease.

Study design

All subjects answered a standardized questionnaire and underwent neurological physical examination by two independent neurologists; proviral load was also quantitatively determined. Two scales were used to assess neurological disability in individuals infected with HTLV-1: The extended disability status scale (EDSS)²⁷ and OMDS.²⁸ Individuals additionally underwent a 10-m walking test as previously described.²⁹ The outcomes of interest were the presence of spinal cord atrophy, thoracic index quantification, and changes in diffusion tensor tractography metrics, that is, FA and MD. Exclusion criteria consisted of any history or signs of unrelated diseases with the potential to affect the central nervous system, spine radiation therapy, previous spine surgery, contraindication to MR imaging, and relevant motion artifacts.

HTLV-1 proviral load

DNA was extracted from 10^6 peripheral blood mononuclear cells (PBMC) using proteinase K and the salting-out method. HTLV-1 proviral load was quantified by real-time PCR as previously described using an ABI Prism 7700 Sequence detector system (Applied Biosystems),³⁰ with albumin DNA used as an endogenous reference. Normalized HTLV-1 proviral load values were calculated as the ratio of HTLV-1 DNA average copy number/albumin DNA average copy number $\times 2 \times 10^6$, and expressed as the number of HTLV-1 copies per 10^6 PBMCs.

MR examination

Conventional MRI with DTI was performed on all subjects using a 1.5-Tesla-MR scanner (Siemens; Symphony) with a 16-channel spinal coil. The protocol consisted of sagittal T2-weighted images (turbo spin echo sequence TE/TR = 131/5010 ms, 3.0 mm slice thickness, FOV = 320 mm), SPACE 3D sequence TE/TR 124/1500 ms, measured voxel size = 1.0 x 1.0 x 1.0 mm, FOV = 256 mm, and transversal T2-weighted sequence TE/TR 95/4990 ms, FOV = 170 mm) at the 5th thoracic vertebral level and the lower cord immediately above the conus medullaris. The 5th thoracic vertebral level was chosen to reflect the mid-thoracic spinal cord level. Diffusion weighting was applied in 12 gradient directions with a b-value = 0 and 1000s/mm² in the axial plane at the same levels, TE/TR 124/1500 ms, measured voxel size = 2.7 x 1.6 x 4.5 mm, FOV = 200 mm. The overall scanning time for the two DTI acquisitions was 1m49s. DTI data were analyzed using *syngo.via* imaging software (Siemens Healthcare GmbH, Erlangen-Germany). On axial images, individual regions of interest (ROI) were drawn freehand to circumscribe the hemicord, encompassing white and gray matter (Fig. 1). Due to the smaller size of the spinal cord cross-section analyzed, it was not possible to obtain valid measurements for separate more minute ROIs. The anteroposterior and transversal diameters were respectively defined as the distance from the ventral to the dorsal border and from the left to right border of the spinal cord. Spinal cord MRIs were examined for the presence of diffuse atrophy. The thoracic and lumbar index were calculated using the following equation: 1/ anteroposterior diameter (AP) x transverse diameter (TD), that is, higher values indicated greater degrees of spinal cord atrophy. Independent assessments of spinal cord images and FA and MD measurements

were conducted by a neuroradiologist and a neurologist with experience in neuroimaging; disagreements were settled by consensus. All evaluators were blinded to the clinical status of the subjects.

Statistical analysis

A database was built using REDCap, an internet-based software platform developed at Vanderbilt University.³¹ Data were tested for normality using the Kolmogorov–Smirnov test. Comparisons among categorical variables were made using Pearson's Chi-squared test or Fisher's exact test. Comparisons among DTI parameters and volumetric results were performed between the three groups using the Kruskal–Wallis test. Receiver operating characteristic (ROC) curve analysis considering the area under the curve (AUC) was employed to compare the performance of thoracic index, FA and MD measurements in predicting HAM. Spearman's rank correlation coefficients were calculated to evaluate correlations between thoracic index values, and DTI and clinical parameters. All statistical analyses were carried out using SPSS version 22 software; results were considered significant when $p < 0.05$.

Results

Patient demographic characteristics, duration of follow-up, the presence of associated diseases and proviral load determinations are listed in Table 1. No differences were seen regarding the demographic features of the three participant groups, nor with respect to time of follow-up. Median HTLV-1 proviral load was higher in definite-HAM patients than in HTLV-1 carriers ($p < 0.02$).

MRI inspection revealed atrophy of the spinal cord in 15 (53.6%) patients with definite-HAM in contrast to none of the HTLV-1 carriers or HS ($p < 0.001$). The

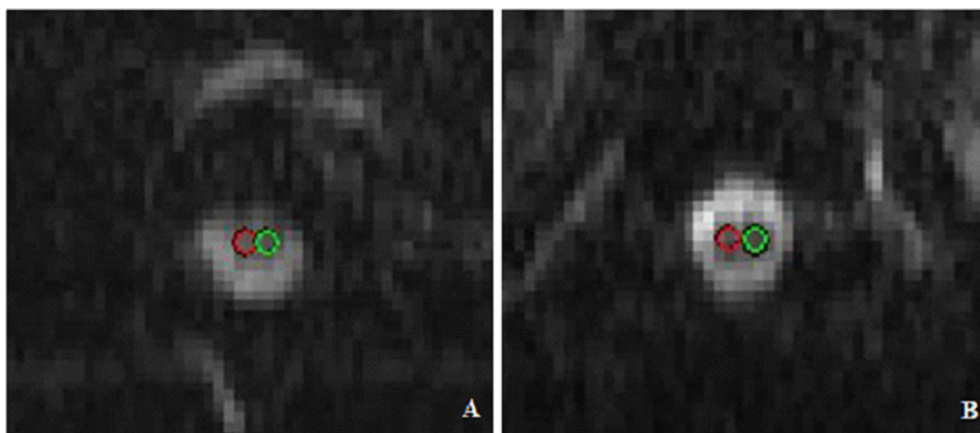


Figure 1. Region-of-interest (ROI) placement. Placement of the measurement ROIs on the axial B0 image at the 5th thoracic vertebral level (A) and the lower cord immediately above the conus medullaris (B).

Table 1. Demographic features, associated disease status and proviral load in HTLV-1-infected subjects and seronegative individuals.

Characteristics	HAM (<i>n</i> = 28)	HTLV-1 carriers (<i>n</i> = 33)	Seronegative (<i>n</i> = 11)	<i>p</i> value
Female sex <i>n</i> (%)	19 (67.9%)	19 (57.6%)	6 (54.5%)	0.63 ¹
Age (years)	53.86 (±12.16)	52.7 (±11)	52.2 (±14.38)	0.89 ²
Follow-up (years)	5.5 (2–8.75)	11 (5–14)	–	0.87 ³
Sicca syndrome	0	0	–	–
HTLV-1 associated arthropathy	5 (17.8%)	5 (15.1%)	–	>0.99 ⁴
Diabetes	6 (21.4%)	2 (6.1%)	–	0.12 ⁴
HBV infection	0	0	–	–
HCV infection	1 (3.6%)	1 (3%)	–	>0.99 ⁴
Proviral load ⁵ (copies/10 ⁶ PBMC)	93,893 (49,408–166,835)	20,692 (6,216–82,434)	–	0.12 ³

HAM, HTLV-1-associated myelopathy; HBV, Hepatitis B virus; HCV, Hepatitis C virus.

¹ χ^2 test.

²Kruskal–Wallis test.

³Mann–Whitney *U* test.

⁴Fisher's exact test.

⁵Median [interquartile range].

thoracic area of the spine, as well as the anteroposterior and transverse diameters measured at T5, were inferior in the group of patients with definite HAM compared to HTLV-1 carriers and seronegative individuals ($p < 0.001$, Kruskal–Wallis test). Higher thoracic index values were observed in the definite HAM group ($p < 0.001$, Mann–Whitney *U* test) (Table 2). DTI measurements of the spinal cord are shown in Table 3. FA values at the 5th thoracic vertebral level were reduced in the definite HAM group ($p < 0.001$) along with considerably elevated MD values ($p < 0.001$) (Table 3). Thoracic and lumbar spinal cord parameters did not differ significantly among HTLV-1 carriers and seronegative individuals.

ROC curve analysis using a cutoff FA value of 0.545 at the 5th thoracic vertebral level successfully discriminated

definite HAM subjects with 83.9% sensitivity, while the rate of false HAM patient detection (1-specificity) was 26.9% (AUC 0.824; 95% CI: 0.716–0.932). The optimal cutoff value established for MD was $1.3445 \times 10^{-3} \text{ mm}^2/\text{s}$, providing a sensitivity of 74.2% and specificity of 84.6% regarding the detection of definite-HAM patients (AUC 0.839; 95% CI: 0.736–0.942). ROC curve analysis also demonstrated the capability of the thoracic index assessment to discriminate between HTLV-1 carriers and definite-HAM patients using a cutoff value of 2.48 (AUC 0.838; 95% CI: 0.728–0.949), achieving 84.4% sensitivity, and 80.8% specificity (Figure 2). Lumbar spinal cord parameters were not found to discriminate between the HTLV-1-infected groups. The rate of HAM patients correctly classified using MD values (\geq cutoff) was 84.6%

Table 2. Frequency of spinal cord atrophy and MRI measurements of the spinal cord in HTLV-1-infected subjects and seronegative individuals.

	HAM (<i>n</i> = 28)	HTLV-1 carriers (<i>n</i> = 33)	Seronegative (<i>n</i> = 11)	<i>p</i> value
Spinal atrophy ¹ <i>n</i> (%)	15 (53.6%)	0	0	<0.001 ²
Vertebral level: T5				
Thoracic area (cm ²) ³	0.260 (0.220–0.320)	0.360 (0.330–0.390)	0.400 (0.387–0.442)	<0.001 ⁴
Anteroposterior diameter (cm) ³	0.480 (0.450–0.525)	0.540 (0.520–0.620)	0.590 (0.525–0.645)	<0.001 ⁴
Transverse diameter (cm) ³	0.730 (0.665–0.785)	0.820 (0.780–0.880)	0.870 (0.825–0.915)	<0.001 ⁴
Thoracic index (1/cm ²) ⁵	2.76 (2.52–3.43)	2.19 (2.01–2.46)	2.02 (1.74–2.19)	<0.001 ⁴
Vertebral level: T12–L1				
Lumbar area (cm ²) ³	0.550 (0.455–0.625)	0.580 (0.530–0.650)	0.675 (0.547–0.725)	0.01 ⁴
Anteroposterior diameter (cm) ³	0.690 (0.475–0.780)	0.730 (0.650–0.770)	0.760 (0.715–0.807)	0.06 ⁴
Transverse diameter (cm) ³	0.900 (0.815–0.935)	0.910 (0.850–0.960)	0.920 (0.880–1.012)	0.13 ⁴
Lumbar index (1/cm ²) ⁵	1.59 (1.37–1.94)	1.53 (1.37–1.76)	1.39 (1.27–1.58)	0.06 ⁴

HAM, HTLV-1-associated myelopathy.

¹On inspection.

² χ^2 test.

³Median (interquartile range)

⁴Kruskal–Wallis test.

⁵1/(anteroposterior diameter \times transverse diameter).

Table 3. Diffusion tensor imaging parameters in the spinal cords of HTLV-1 infected subjects and seronegative individuals.

Vertebral level	DTI parameters	HAM (<i>n</i> = 26) ¹	HTLV-1 carriers (<i>n</i> = 31)	Seronegative (<i>n</i> = 10)	<i>p</i> value ²
T5	Fractional anisotropy	0.519 (0.434–0.565)	0.642 (0.554–0.707) ³	0.688 (0.574–0.704) ³	<0.001
	Mean diffusivity	1.521 (1.409–1.736)	1.259 (1.135–1.425) ³	1.228 (1.084–1.408) ³	<0.001
T12-L1	Fractional anisotropy	0.433 (0.382–0.523)	0.482 (0.399–0.547)	0.545 (0.508–0.621) ³	0.015
	Mean diffusivity	1.140 (1.064–1.230)	0.963 (0.892–1.166) ³	1.116 (0.921–1.349)	0.037

Measurements presented as median values (interquartile range). DTI, diffusion tensor imaging; HAM, HTLV-1-associated myelopathy.

Level of significance for difference between definite-HAM versus carriers and versus seronegative is $p < 0.01$ (³) by Mann-Whitney-*U*-Test.

¹Due to artifacts, images were only analyzed in 26 of 28 patients with HAM.

²Kruskal-Wallis test.

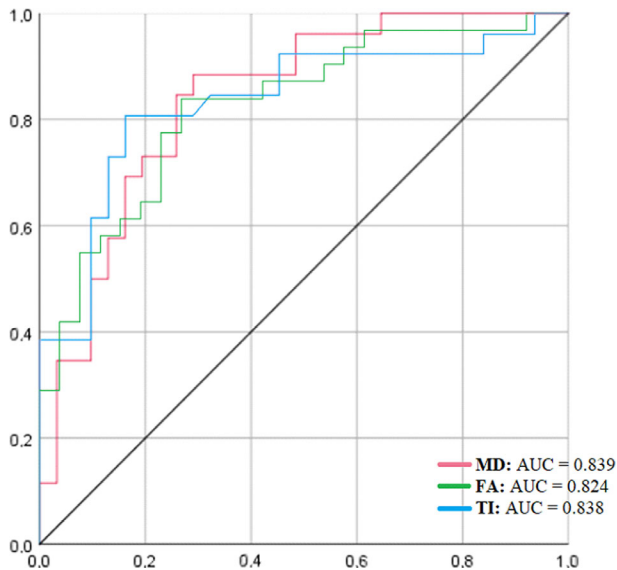


Figure 2. ROC curve analysis of fractional anisotropy (FA), mean diffusivity (MD), and thoracic index (TI) values in 31 asymptomatic HTLV-1 carriers and 26 HAM patients at the T5 vertebral level. MD: area under the curve: 0.839 (95% CI: 0.736–0.942), optimal cutoff: 1.3445, with 74.2% sensitivity and 84.6% specificity at cutoff. FA: area under the curve: 0.824 (95% CI: 0.716–0.932), optimal cutoff 0.545, 83.9% sensitivity, and 73.1% specificity at cutoff. TI: area under the curve: 0.838 (95% CI: 0.728–0.949), optimal cutoff 2.48, 84.4% sensitivity and 80.8% specificity at cutoff.

(22/26) compared to 73% (19/26) using FA. In addition, the rate of false identification of HAM (carriers with thoracic index \geq , or FA value \leq cutoff) was 18.7% (Table 4).

We did not find a correlation between illness duration and DTI parameters or the thoracic index, but there was a direct correlation between 10-m walk test and lumbar MD values ($r = 0.519$, $p = 0.03$). Clinical disability scores, expressed as median (interquartile range) values on the EDSS and OMDS were 5.5 (4–6.5) and 5 (3–6.75) in the HAM group, respectively. At the 5th thoracic vertebral level, EDSS and OMDS scores were found to strongly correlate with the following parameters: spinal cord area, anteroposterior and transverse diameters, thoracic index,

Table 4. MRI findings in HTLV-1-infected subjects and seronegative individuals, stratified by DTI parameter and thoracic index cutoff values.

	HAM <i>N</i> = 26 ¹	HTLV-1 carriers <i>N</i> = 31	Seronegative <i>n</i> (%) <i>N</i> = 11
Spinal atrophy ² present	<i>N</i> = 14	0	0
Thoracic index ≥ 2.48	14 (100)	0	0
Fractional anisotropy (T5) ≤ 0.545	14 (100)	0	0
Mean diffusivity (T5) $\geq 1.3445 \times 10^{-3}$ mm ² /sec	13 (92.8)	0	0
Normal spine ²	<i>N</i> = 12	<i>N</i> = 31	<i>N</i> = 11
Thoracic index ≥ 2.48	8 (66.6)	6 (18.7)	1 (9)
Fractional anisotropy (T5) ≤ 0.545	5 (41.6)	6 (18.7)	2 (18.2)
Mean diffusivity (T5) $\geq 1.3445 \times 10^{-3}$ mm ² /sec	9 (75)	9 (28.1)	3 (27.2)

¹Due to artifacts, images were only analyzed in 26 of 28 patients with definite HAM.

²On inspection.

FA, and MD. A negative correlation was noted between FA and thoracic index, while the former correlated positively with area, AP and TD parameters. A direct correlation was observed between MD and thoracic index, while negative correlations were detected between MD and the AP, TD, and area parameters (Table 5).

Discussion

HTLV-1 was the first retrovirus identified.³² However, as it remains a neglected infection, there are no complementary exams that assist in the diagnosis of HAM, and no effective antiviral drugs have been developed to treat HTLV-1. Conventional MRI has failed to demonstrate atrophy or other findings related to this disease in 33.4% to 76.5% of cases meeting the clinical criteria of definite HAM.^{8,10,12,33–35} Moreover, while conventional MRI may detect abnormalities in definite HAM, a more highly sensitive technique is required to investigate spinal cord involvement in individuals who do not present clinical

Table 5. Correlations between DTI parameters, imaging findings and disability scale scores in HTLV-1 carriers and HAM patients at the 5th thoracic vertebral level.

	DTI parameters		Disability scales	
	FA	MD	EDSS	OMDS
Area	0.67 (<0.001)	-0.54 (<0.001)	-0.64 (<0.001)	-0.66 (<0.001)
AP	0.56 (<0.001)	-0.45 (<0.001)	-0.54 (<0.001)	-0.58 (<0.001)
TD	0.55 (<0.001)	-0.46 (<0.001)	-0.49 (<0.001)	-0.58 (<0.001)
Thoracic index	-0.65 (<0.001)	0.54 (<0.001)	0.60 (<0.001)	0.62 (<0.001)
EDSS	-0.58 (<0.001)	0.59 (<0.001)		
OMDS	-0.60 (<0.001)	0.57 (<0.001)		

Spearman correlations were calculated between parameters. The 'r' indexes are shown (*p* value). FA, fractional anisotropy; MD, mean diffusivity; AP, anteroposterior diameter; TD, transverse diameter; thoracic index, 1/AP × TD; EDSS, Extended Disability Status; OMDS, Osame Motor Disability Score.

disease, as well as to determine whether the spinal cord injury detectable on imaging may bear correlations with illness duration and disease severity. DTI metrics are based on measurements of the three-dimensional diffusivity of water, which is directed by different "barriers", such as axons, cell membranes and particularly myelin sheaths.³⁶ Pathological processes impairing the microstructure of central nervous system tissue, for example, the diffuse loss of myelin and axons evidenced by neuropathological studies in definite-HAM patients, alter the anisotropy of water diffusion.^{7,36} Although previous studies have documented FA abnormalities in patients with HAM¹¹, the sensitivity of DTI parameters in the diagnosis of definite HAM has not been determined to date.

The definite-HAM and HTLV-1 carriers involved in the present study presented similar demographic and epidemiological profiles. As expected, proviral load was elevated in patients with HAM compared to HTLV-1 carriers. HAM development has been associated with increased HTLV-1 proviral load and the female sex,⁶ which explains the higher proportion of females in the definite-HAM group. The most common and nonspecific finding observed on MRI of the thoracic spinal cord is atrophy.¹³ On inspection, thoracic spinal cord atrophy was observed in 53.6% of the definite-HAM patients evaluated herein, which stands in agreement with previous findings.^{10,12,34} This greater sensitivity of the thoracic index when compared to binary categorization of atrophy reflects lower discrimination and accuracy of visual inspection alone by a radiologist.

In the spinal cord, inflammatory myelitis is characterized by decreased FA values in the region of T2-weighted lesions, with increased FA values seen at lesion boundaries.¹⁵ Vilchez et al.,¹¹ in addition to conventional MRI of the cervical cord and thoracolumbar spine, investigated DTI parameters in the evaluation of patients with definite HAM and HTLV-1 carriers. These authors identified significant correlations exclusively between reduced FA in

dorsal fiber and neurological findings. In the present study, the definite-HAM group showed significantly decreased FA and increased mean diffusivity values in the thoracic spine compared to HS and HTLV-1 carriers. The decreased FA values may be related to reduce amount of extracellular water due to cytotoxic edema, axonal cluster regeneration or cellular infiltration by inflammatory cells.¹⁵ Increased MD values could be related to larger extracellular spaces (due to axonal and neuronal loss) in combination with spinal cord atrophy.^{37,38}

The main pathological feature characterizing HAM is the presence of chronic inflammation with mononuclear cell infiltration and diffuse degeneration of both myelin and axons, notably in the thoracic cord.⁷ The pattern of DTI metrics found in patients with HAM is similar to the one observed in other infectious or inflammatory myelopathies as multiple sclerosis, but DTI parameters may rule out other neurologic disorders of the spinal cord as ischemic myelopathy and acute injury due to compression.^{15,20,39} Regarding the diagnosis of HAM, the DTI metrics seems a promising supplementary diagnostic tool in addition to the clinical criteria and liquor. Moreover, early signs of HTLV-1 medullary injury not observed in the conventional MRI may be detectable. The present results suggest that increased MD and decreased FA in the thoracic cord of HAM patients may reflect axonal loss, demyelination and parenchymal inflammatory infiltration, which precisely correlate with previously reported histological findings.^{7,40,41} Nonetheless, this remains a speculative hypothesis, as animal studies examining diffusion parameters and corresponding histology would be required to confirm or refute this premise.

In contrast to our findings, some previous reports do not demonstrate clear relationships between the severity of disease and spinal cord parameters.^{8,11,12,42} However, a study by Liu et al. (2014) did find that spinal cord atrophy was correlated with ambulatory index.⁹ Moreover, our results showed that clinical disability scores correlated with

spinal cord area, anteroposterior and transverse diameters and the thoracic index at the 5th thoracic vertebral level. With regard to DTI parameters, FA and MD in the thoracic cord were also found to correlate with disease severity, in contrast to previous findings.¹¹ This could be explained by the low number of patients with definite HAM in previous investigations, as well as the use of the American spinal injury association impairment (ASIA) scale to assess the effects of spinal cord injury. Unlike EDSS, neurological disability evaluations made using the ASIA scale do not account for bowel or bladder dysfunction.

Our study has several limitations. The number of seronegative controls included was relatively small, that is, by increasing the number of these individuals, differences in DTI derivative measures might approach significance between carriers and seronegative controls. As only a limited number of patients who presented probable HAM underwent MRI, comparisons between these patients and those with definite HAM were not performed. Although patients with probable HAM present no motor disability, these individuals should be evaluated in future studies, as abnormalities in DTI values were found to directly correlate with the EDSS; notably, patients with probable HAM present EDSS scores ≥ 2 .⁴ In addition, the present investigation employed a 1.5-T MRI system with a 16-channel spinal coil, which offers inferior image quality compared to 3.0 T systems; moreover, ROIs were defined manually and diffusion weighting was applied in 12 gradient directions, which may affect the measurement of DTI parameters. Despite these limitations, the thoracic index proved to be a simple and useful tool in the diagnosis of HAM, providing excellent accuracy (83%) to discriminate between HTLV-1 carriers and HAM patients.

The well-described histopathologic findings detailing damage to the spinal cord caused by the inflammatory response in HTLV-1-infected subjects may serve to explain the increased MD and decreased FA values seen in the thoracic spine of patients with definite HAM.^{7,43–47} Our results indicate that both methods (thoracic index and DTI derivative measures) evaluated herein may be applicable in the diagnosis of definite HAM; however, additional studies involving age-matched patients and a larger control group are essential to enhancing the diagnostic value of these parameters. Nonetheless, the findings presented herein clearly show that DTI offers high sensitivity in the detection of spinal cord damage and should be considered as a relevant diagnostic indicator in the evaluation of HAM. Moreover, correlations between DTI derivative measures and OMDS and EDSS scale results further corroborate the potential of FA and MD as biomarkers of the severity of spinal cord injury in HTLV-1-infected subjects.

Acknowledgments

The authors are grateful to Cristiano Franco and Andris Walter for assistance in the preparation of the manuscript. This research was supported by the Maria Emilia Freire Pedreira de Carvalho Foundation, the Brazilian National Research Council (CNPq) and Fundação de Amparo à Pesquisa do Estado da Bahia (FAPESB).

Author Contributions

S.N.F., J.A.C.N., J.O.F., and E.M.C. contributed to conception and design of the study and methods. S.N.F., G.L.R., C.J.V.O., C.A.N., L.P., J.O.F., and E.M.C. contributed to acquisition and analysis of data. S.N.F., G.L.R., J.O.F., and E.M.C. contributed to drafting the text and preparing the figures.

Conflict of Interest

Nothing to report.

References

- Gessain A, Cassar O. Epidemiological aspects and world distribution of HTLV-1 infection. *Front Microbiol.* 2012;3:388.
- World Health Organization. Human T-lymphotropic virus type 1: technical report. Geneva: World Health Organization; 2021. <https://apps.who.int/iris/handle/10665/339773>
- Poetker SKW, Porto AF, Giozza SP, et al. Clinical manifestations in individuals with recent diagnosis of HTLV type I infection. *J Clin Virol.* 2011;51(1): 54–58.
- Castro NM, Rodrigues W Jr, Freitas DM, Muniz A, Oliveira P, Carvalho EM. Urinary symptoms associated with human T-cell lymphotropic virus type I infection: evidence of urinary manifestations in large group of HTLV-I carriers. *Urology.* 2007;69(5):813–818.
- de Oliveira CJV, Neto JAC, Andrade RCP, Rocha PN, de Carvalho Filho EM. Risk factors for erectile dysfunction in men with HTLV-1. *J Sex Med.* 2017;14(10):1195–1200.
- Bangham CR, Araujo A, Yamano Y, Taylor GP. HTLV-1-associated myelopathy/tropical spastic paraparesis. *Nat Rev Dis Primers.* 2015;1:15012.
- Izumo S. Neuropathology of HTLV-1-associated myelopathy (HAM/TSP): the 50th Anniversary of Japanese Society of Neuropathology. *Neuropathology.* 2010;30:480–485.
- Taniguchi A, Mochizuki H, Yamashita A, Shiomi K, Asada Y, Nakazato M. Spinal cord anteroposterior atrophy in HAM/TSP: magnetic resonance imaging and neuropathological analyses. *J Neurol Sci.* 2017;381:135–140.

9. Liu W, Nair G, Vuolo L, et al. In vivo imaging of spinal cord atrophy in neuroinflammatory diseases. *Ann Neurol*. 2014;76(3):370-378.
10. Melo A, Moura L, Rios S, Machado M, Costa G. Magnetic resonance imaging in HTLV-I associated myelopathy. *Arq Neuropsiquiatr*. 1993;51(3):329-332.
11. Vilchez C, Gonzalez-Reinoso M, Cubbison C, et al. Atrophy, focal spinal cord lesions and alterations of diffusion tensor imaging (DTI) parameters in asymptomatic virus carriers and patients suffering from human T-lymphotropic virus type 1 (HTLV-1)-associated myelopathy/tropical spastic paraparesis (HAM/TSP). *J Neurovirol*. 2014;20(6):583-590.
12. Yukitake M, Takase Y, Nanri Y, et al. Incidence and clinical significances of human T-cell lymphotropic virus type I-associated myelopathy with T2 hyperintensity on spinal magnetic resonance images. *Intern Med*. 2008;47(21):1881-1886.
13. Romanelli LCF, Miranda DM, Carneiro-Proietti ABF, et al. Spinal cord hypometabolism associated with infection by human T-cell lymphotropic virus type 1 (HTLV-1). *PLoS Negl Trop Dis*. 2018;12(8):e0006720.
14. Shapey J, Vos SB, Vercauteren T, et al. Clinical applications for diffusion mri and tractography of cranial nerves within the posterior fossa: a systematic review. *Front Neurosci*. 2019;13:23.
15. Renoux J, Facon D, Fillard P, Huynh I, Lasjaunias P, Ducreux D. MR diffusion tensor imaging and fiber tracking in inflammatory diseases of the spinal cord. *AJNR Am J Neuroradiol*. 2006;27(9):1947-1951.
16. Jones DK, Simmons A, Williams SC, Horsfield MA. Non-invasive assessment of axonal fiber connectivity in the human brain via diffusion tensor MRI. *Magn Reson Med*. 1999;42(1):37-41.
17. El Maati AAA, Chalabi N. Diffusion tensor tractography as a supplementary tool to conventional MRI for evaluating patients with myelopathy. *Egypt J Radiol Nucl Med*. 2014;45:1223-1231.
18. Ribas ESC, Teixeira MJ. Tractografia: definição e aplicação na resseção de tumores cerebrais / tractography: definition and application in brain tumor surgery. *Arq Bras Neurocir*. 2011;30:30-33.
19. Cui JL, Li X, Chan TY, Mak KC, Luk KD, Hu Y. Quantitative assessment of column-specific degeneration in cervical spondylotic myelopathy based on diffusion tensor tractography. *Eur Spine J*. 2015;24(1):41-47.
20. Ohgiya Y, Oka M, Hiwatashi A, et al. Diffusion tensor MR imaging of the cervical spinal cord in patients with multiple sclerosis. *Eur Radiol*. 2007;17(10):2499-2504.
21. Ducreux D, Fillard P, Facon D, et al. Diffusion tensor magnetic resonance imaging and fiber tracking in spinal cord lesions: current and future indications. *Neuroimaging Clin N Am*. 2007;17(1):137-147.
22. Ducreux D, Lepeintre JF, Fillard P, Loureiro C, Tadié M, Lasjaunias P. MR diffusion tensor imaging and fiber tracking in 5 spinal cord astrocytomas. *AJNR Am J Neuroradiol*. 2006;27(1):214-216.
23. Czernicki T, Maj E, Podgórska A, et al. Diffusion tensor tractography of pyramidal tracts in patients with brainstem and intramedullary spinal cord tumors: relationship with motor deficits and intraoperative MEP changes. *J Magn Reson Imaging*. 2017;46(3):715-723.
24. Fukui Y, Hishikawa N, Sato K, et al. Detecting spinal pyramidal tract of amyotrophic lateral sclerosis patients with diffusion tensor tractography. *Neurosci Res*. 2018;133:58-63.
25. Lee JW, Park KS, Kim JH, et al. Diffusion tensor imaging in idiopathic acute transverse myelitis. *AJR Am J Roentgenol*. 2008;191(2):W52-W57.
26. De Castro-Costa CM, Araújo AQ, Barreto MM, et al. Proposal for diagnostic criteria of tropical spastic paraparesis/HTLV-I-associated myelopathy (TSP/HAM). *AIDS Res Hum Retroviruses*. 2006;22(10):931-935.
27. Kurtzke JF. Rating neurologic impairment in multiple sclerosis: an expanded disability status scale (EDSS). *Neurology*. 1983;33:1444.
28. Matsuzaki T, Nakagawa M, Nagai M, et al. HTLV-I-associated myelopathy (HAM)/tropical spastic paraparesis (TSP) with amyotrophic lateral sclerosis-like manifestations. *J Neurovirol*. 2000;6(6):544-548.
29. Bohannon RW. Comfortable and maximum walking speed of adults aged 20–79 years: reference values and determinants. *Age Ageing*. 1997;26:15-19.
30. Dehée A, Césaire R, Désiré N, et al. Quantitation of HTLV-I proviral load by a TaqMan real-time PCR assay. *J Virol Methods*. 2002;102(1-2):37-51.
31. Harris PA, Taylor R, Thielke R, Payne J, Gonzalez N, Conde JG. Research electronic data capture (REDCap)—a metadata-driven methodology and workflow process for providing translational research informatics support. *J Biomed Inform*. 2009;42(2):377-381.
32. Poiesz BJ, Ruscetti FW, Gazdar AF, Bunn PA, Minna JD, Gallo RC. Detection and isolation of type C retrovirus particles from fresh and cultured lymphocytes of a patient with cutaneous T-cell lymphoma. *Proc Natl Acad Sci USA*. 1980;77(12):7415-7419.
33. Ferraz AC, Gabbai AA, Abdala N, Nogueira RG. Magnetic resonance in HTLV-I associated myelopathy: leukoencephalopathy and spinal cord atrophy. *Arq Neuropsiquiatr*. 1997;55:728-736.
34. Howard AK, Li DK, Oger J. MRI contributes to the differentiation between MS and HTLV-I associated myelopathy in British Columbian coastal natives. *Can J Neurol Sci*. 2003;30(1):41-48.
35. Yamamoto F, Yamashita S, Yamamura A, et al. Abnormal spinal MRI findings in human T-cell lymphotropic virus type I-associated myelopathy. *Clin Neurol Neurosurg*. 2009;111(7):624-628.

36. Patzig M, Bochmann K, Lutz J, et al. Measurement of structural integrity of the spinal cord in patients with amyotrophic lateral sclerosis using diffusion tensor magnetic resonance imaging. *PLoS One*. 2019;14(10):e0224078.
37. Ellingson BM, Ulmer JL, Kurpad SN, Schmit BD. Diffusion tensor MR imaging in chronic spinal cord injury. *AJNR Am J Neuroradiol*. 2008;29(10):1976-1982.
38. Agosta F, Absinta M, Sormani MP, et al. In vivo assessment of cervical cord damage in MS patients: a longitudinal diffusion tensor MRI study. *Brain*. 2007;130(Pt 8):2211-2219.
39. Li DC, Malcolm JG, Rindler RS, et al. The role of diffusion tensor imaging in spinal pathology: a review. *Neurol India*. 2017;65(5):982-992.
40. Umehara F, Izumo S, Nakagawa M, et al. Immunocytochemical analysis of the cellular infiltrate in the spinal cord lesions in HTLV-I-associated myelopathy. *J Neuropathol Exp Neurol*. 1993;52(4):424-430.
41. Matsuura E, Nozuma S, Tashiro Y, Kubota R, Izumo S, Takashima H. HTLV-1 associated myelopathy/tropical spastic paraparesis (HAM/TSP): a comparative study to identify factors that influence disease progression. *J Neurol Sci*. 2016;371:112-116.
42. Evangelou IE, Massoud R, Jacobson S. HTLV-I-associated myelopathy/tropical spastic paraparesis: semiautomatic quantification of spinal cord atrophy from 3-dimensional MR images. *J Neuroimaging*. 2014;24(1):74-78.
43. Iwasaki Y. Pathology of chronic myelopathy associated with HTLV-I infection (HAM/TSP). *J Neurol Sci*. 1990;96(1):103-123.
44. Cartier LM, Cea JG, Vergara C, Araya F, Born P. Clinical and neuropathological study of six patients with spastic paraparesis associated with HTLV-I: an axomyelinic degeneration of the central nervous system. *J Neuropathol Exp Neurol*. 1997;56(4):403-413.
45. Matsuura E, Yoshimura A, Nozuma S, Higuchi I, Kubota R, Takashima H. Clinical presentation of axial myopathy in two siblings with HTLV-1 associated myelopathy/tropical spastic paraparesis (HAM/TSP). *BMC Neurol*. 2015;15:18.
46. Aye MM, Matsuoka E, Moritoyo T, et al. Histopathological analysis of four autopsy cases of HTLV-I-associated myelopathy/tropical spastic paraparesis: inflammatory changes occur simultaneously in the entire central nervous system. *Acta Neuropathol*. 2000;100(3):245-252.
47. Yoshioka A, Hirose G, Ueda Y, Nishimura Y, Sakai K. Neuropathological studies of the spinal cord in early stage HTLV-I-associated myelopathy (HAM). *J Neurol Neurosurg Psychiatry*. 1993;56(9):1004-1007.