



Volume 34, Issue suppl_1
1 August 2013

< Previous Next >

JOURNAL ARTICLE

Early changes in left ventricular diastolic function and left atrial function in chagas disease identified by tissue doppler and speckle tracking FREE

F. Bonamigo Thome, C.A.S. Nascimento, S.K. Silva, C.R.F. Santos, P.E.A. Brasil, A.S. Sousa, S.S. Xavier, A.M. Hasslocher-Moreno, A.B. Cunha, R.M. Saraiva

European Heart Journal, Volume 34, Issue suppl_1, 1 August 2013, 4542,

<https://doi.org/10.1093/eurheartj/eh310.4542>

Published: 01 August 2013



PDF

Split View

Cite

Permissions

Share ▼

failure. Impaired coronary velocity flow reserve (CFR) reflects endothelial dysfunction and is associated with poor outcome. We investigated whether CFR is associated to impaired myocardial deformation and adverse outcome in septic shock patients.

Methods: In 70 septic shock patients under mechanical-ventilation we examined a) S',E',A' mitral and tricuspid annular velocities and ratio E to E' (E/E') using tissue Doppler imaging, and b) CFR of Left Main Coronary Artery (LMCA) after adenosine infusion using Doppler echo during Transoesophageal Echocardiogram c) lactate, pyruvate, glycerol in peripheral blood samples and in tissue after inserting a Microdialysis (MD) catheter into the subcutaneous adipose tissue. Tissue Lactate is a marker of acidosis, ischemia and anaerobic metabolism, lactate to pyruvate (L/P) ratio, a marker of tissue ischemia and glycerole, a marker of cell membrane damage and stress. ICU mortality was recorded.

Results: All patients had EF>50%, with no history of heart failure. CFR correlated to (SOFA) score (r -0,386) APACHE II score (r -0.354) blood lactate (r -0.381), MD lactate (r =-0,258), E' (r=-0.262) (p<0.05 for all correlations). S' correlated with SOFA score (r -0.269), MD glycerol (r -0.346) and MD lactate to pyruvate (L/P) ratio (r 0,310 p=0.009). E' correlated to APACHE score (r =- 0.387), SOFA score (r -0.259) and MD glycerol (r -0.370). E/E' correlated with SOFA and APACHE II scores (r =-0,377, p=0,003 and r -0,517 p=0,001 respectively), blood lactate (r 0,317 p<0,015) and MD glycerol (r 0,397, p<0,001). CFR was 1.75±0.4 in non-survivors (n=35) compared to 2.1±0.4 in survivors (p<0.05). Cox regression analysis indicated that CFR independently predicted mortality in ICU [OR:0.365 [CI] 0.183-0.721 p=0,004]. A cut-off CFR value <1.90 predicted mortality (area under the curve 71% p=0.003) with sensitivity of 70% and specificity of 64%. CFR had an additive value to APACHE (chi square change: 4.358 p=0.037) and SOFA (chi square change:3.692 p=0.049) for the prediction of ICU mortality.

Conclusion: CFR is related with blood and tissue acidosis and impaired LV diastolic deformation in septic shock patients. LV deformation is also linked with tissue acidosis. Thus, acidosis is the common pathophysiological link between abnormal CFR and impaired LV myocardial deformation. CFR is an independent and additive predictor of mortality to traditional risk scores in septic shock patients.

4540 | BEDSIDE

Lack of systolic arterial stiffening in vascular Ehlers-Danlos syndrome

T. Mirault¹, M. Frank², M. Pernot³, M. Couade³, M. Tanter³, R. Niarra⁴, M. Azizi⁴, J. Albuissou², X. Jeunemaitre², E. Messas¹. ¹AP-HP - European Hospital Georges Pompidou, Vascular Medicine Service, Paris Descartes University, Paris, France; ²AP-HP - European Hospital Georges Pompidou, Cardiovascular Genetic Unit, Paris Descartes University, Paris, France; ³Institut Langevin, ESPCI ParisTech, Inserm, Paris, France; ⁴AP-HP - European Hospital Georges Pompidou, Clinical Investigation Center, Paris Descartes Univ., Paris, France

Background: Vascular Ehlers-Danlos syndrome (vEDS) is a rare vascular disease resulting from autosomic dominant mutation in COL3A1 encoding for type III collagen (col.III). Impaired mechanical properties of the arterial wall caused by col.III misfolding (arterial wall thinning and increase wall stress) could expose patients to premature arterial rupture at young age. In this study, we tested whether arterial stiffness could also be impaired in those patients and therefore play a potential role in the vEDS arterial vulnerability. Arterial pulse wave velocity (PWV) is known to be very well correlated to arterial stiffness. We therefore used Sphygmocor to evaluate regional carotid-femoral PWV (cf PWV) and ultrasound Ultrafast imaging (UF) technique to evaluate the local carotid PWV. UF is a new non-invasive tool that can image tissues with high temporal resolution (up to 10,000 images/s) enabling assessment of the local carotid arterial stiffness variation during the cardiac cycle by measuring the local carotid PWV at early and end-systole.

Methods: cf PWV by Sphygmocor and PWV of both carotid arteries by UF were performed on 30 patients with COL3A1 mutation and 102 healthy volunteers. 3 acquisitions of 1000 frames (1000 images/s frame rate) were performed on both common carotid arteries using a conventional linear ultrasonic probe (8MHz, 256 elements) connected to an ultrafast scanner (Aixplorer®). The arterial wall tissue velocities were computed off-line from which the two local carotid PWVs at early and end-systole were derived. cf PWV was acquired according to actual recommendations. Results are mean ± SD.

Results: vEDS patients only differed from controls on age (35.5 vs. 45.0 y, p=0.03) and weight (55.8 vs. 69.8 kg, p<0.0001) but not on sex ratio, systolic or diastolic blood pressures (BP), nor heart rate. The adjusted (age, sex, weight, BP) carotid PWV and cf PWV did not differ between patients and controls in early systole (6.1±1.7 vs. 5.2±1.9 m/s, p=0.07 for right carotid PWV; 5.4±1.4 vs. 4.8±1.2 m/s, p=0.94 for left carotid PWV; 7.6±1.7 vs. 7.3±1.8 m/s, p=0.69 for cf PWV). However, the relative increase of carotid PWV between early and end-systole was significantly reduced in vEDS patients vs. controls (7.1% vs. 26.3% in right carotid (p=0.013) and 9.9% vs. 25.1% in left carotid (p=0.043)).

Conclusion: In this study, we demonstrated a weaker systolic increase of PWV in vEDS patients which could reflect a less adaptative arterial wall stiffening during the cardiac cycle. This may explain the higher susceptibility to arterial rupture in vEDS patients

4541 | BEDSIDE

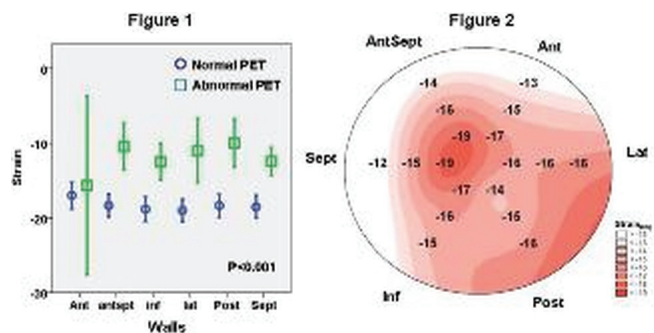
Deteriorated longitudinal strain in patients with cardiac sarcoidosis

K. Negishi¹, T. Negishi¹, Z. Popovic¹, R. Brunken¹, T. Marwick², B. Tamarappoo¹. ¹Cleveland Clinic, Department of Cardiovascular Medicine, Cleveland, United States of America; ²University of Tasmania, Menzies Research Institute Tasmania, Hobart, Australia

Purpose: Sarcoidosis is a multi-system granulomatous disease of unknown etiology. Cardiac involvement is associated with a poor prognosis. Early detection of cardiac sarcoidosis can allow us to treat the patients while the inflammation still exists. Perturbations in longitudinal strain may be the earlier sign of myocardial involvement. We sought to compare longitudinal strain with inflammation (INFL) and scar (SCR) assessed by positron emission tomography (PET).

Methods: We identified consecutive patients with systemic sarcoidosis with an echocardiography and PET within 60 days, excluding those with prior cardiac surgery, more than moderate valvular heart diseases and coronary artery disease. INFL and SCR were defined by FDG and Rb-82 PET in segmental basis. Longitudinal strain was measured by an independent blinded observer. Global longitudinal strain (GLS) was calculated from averaging 18 segmental strains. The wall strain (WS) was obtained by averaging three (base, mid and apex) segmental strains in the each wall of the heart and compared with PET findings.

Results: Of 35 patients (51±11y, 60% men), 28 had SCR and/or INFL by PET. There were 113 abnormal segments and 517 normal by PET. GLS and ejection fraction were higher in patients with normal PET (-22±3% and 60±6%), compared to patients with SCR (-13±4% p=0.001, 44±11% p=0.030) and SCR+INFL (-13±5% p=0.001, 41±15% p=0.007). WS of abnormal PET patients was significantly attenuated compared with the patients with normal PET, p<0.001 (Figure 1). There was a gradual deterioration of strain, worst in the basal septum (Figure 2).



Conclusions: GLS and WS are significantly impaired in patients with abnormal PET findings. Strain may be useful to detect of cardiac involvement in patients with systemic sarcoidosis.

4542 | BEDSIDE

Early changes in left ventricular diastolic function and left atrial function in chagas disease identified by tissue doppler and speckle tracking

F. Bonamigo Thome, C.A.S. Nascimento, S.K. Silva, C.R.F. Santos, P.E.A. Brasil, A.S. Sousa, S.S. Xavier, A.M. Hasslocher-Moreno, A.B. Cunha, R.M. Saraiva. National Institute of Cardiology, Rio de Janeiro, Brazil

Purpose: Up to 20 to 30% of chronic Chagas' disease patients are expected to develop the cardiac form of the disease. The identification of left ventricular (LV) diastolic dysfunction or left atrial (LA) dysfunction may yield a strategy to recognize early cardiac involvement. Our aim was to analyze these parameters in Chagas' disease patients with normal LV systolic function using new echocardiographic techniques.

Methods: Echocardiograms from 52 Chagas' disease patients with the indeterminate form, 29 patients at the stage A of the cardiac form (changes limited to the electrocardiogram) and 25 controls were consecutively acquired. LV diastolic function was analyzed by interrogation of the mitral inflow, pulmonary vein flow, color M-mode flow propagation velocity, LV untwist and tissue Doppler of the mitral annulus. LA function was analyzed by real-time 3 dimensional echocardiography and LA strain (ϵ) analysis including global peak positive LA ϵ (ϵ pos peak), peak negative LA ϵ and total LA ϵ .

Results: All groups presented similar age, gender distribution, chamber diameters, LV mass and LV systolic function. Diastolic dysfunction was more prevalent in stage A patients. While all controls presented normal LV diastolic function, 11.5% of the patients with the indeterminate form presented delayed relaxation and 2% pseudo-normal LV diastolic function and 35.5% of the patients at the stage A of the cardiac form presented delayed relaxation and 13.5% pseudo-normal LV diastolic function (p=0.0001). Tissue Doppler was the best index to discriminate the presence of diastolic dysfunction. E/E' ratio was progressively higher (C: 5.8±1.6; indeterminate: 7.0±1.7; stage A: 8.0±2.9; p=0.0008) and E'/A' ratio was progressively lower (C: 1.5±0.3; indeterminate: 1.2±0.5; stage A: 1.0±0.3; p=0.0004) from controls towards stage A patients. LA volumes were higher in stage A pa-

tients than in controls, but LA emptying fractions did not differ among the groups. LA ϵ pos peak was lower in stage A patients ($15.1 \pm 4.2\%$) than in patients with the indeterminate form ($17.9 \pm 4.8\%$) and controls ($17.8 \pm 4.3\%$; $p=0.02$), while the other LA ϵ parameters did not differ among the groups.

Conclusions: Patients with Chagas' disease and normal LV systolic function present LV diastolic dysfunction, which is more prevalent in patients at the stage A of the cardiac form. Tissue Doppler was the best index to discriminate the presence of diastolic dysfunction and routine evaluation of E'/A' ratio may enable its early recognition. Depression of LA conduit function in stage A patients was observed only by LA strain analysis.

4543 | BEDSIDE

CMR survey in a large cohort of TI patients categorized in different transfusional regimens

A. Meloni¹, S. Vacquer², M.E. Lai², L. Gulino¹, S. Campisi³, D. De Marchi¹, M. Midiri⁴, V. Positano¹, M. Lombardi¹, A. Pepe¹. ¹CMR Unit, Fondazione G. Monasterio CNR-Regione Toscana and Institute of Clinical Physiology, Pisa, Italy; ²Ospedale microcitico Centro Talassemici Adulti, Cagliari, Italy; ³U.O.S. Talassemia - A.O. Umberto I, Siracusa, Italy; ⁴Istituto di Radiologia Policlinico "Paolo Giaccone", Palermo, Italy

Purpose: We investigated myocardial iron overload (MIO), biventricular parameters and myocardial fibrosis assessed by cardiovascular magnetic resonance (CMR) in a large cohort of thalassemia intermedia (TI) patients categorized in different transfusional regimens. This survey is particularly significant considering the debate on the opportunity to transfuse the TI patients.

Methods: We studied retrospectively 252 adult TI patients (119 females, 39±10 yrs) enrolled in the MIOT Network. MIO was assessed by a multislice multiecho T2* approach. Cine sequences were obtained to quantify biventricular function parameters. Myocardial fibrosis was evaluated by late gadolinium enhancement (LGE) acquisitions.

Results: 188 patients showed no MIO in any segment, 56 had an heterogeneous MIO (52 with a global heart T2* <20 ms), and 8 showed an homogeneous MIO. Left ventricular (LV) and right ventricular (RV) dilatations were present in the 45% and in the 19% of cases, respectively. LV dysfunction was present in the 18.0% of the cases while RV dysfunction in the 3.63%. LV hypertrophy was found in the 8.7% of cases.

Myocardial fibrosis was found in the 22.9% of the patients and was associated with LV dysfunction (P=0.001) and hypertrophy (P=0.038).

48 patients were not transfused, 66 sporadically transfused and 138 regularly transfused. The 3 group were significantly different for the LV volume and mass indexes, the cardiac output and the myocardial fibrosis (Table).

	Transfusions			P
	No	Sporadic	Regular	
LV stroke volume (ml/m ²)	63±13	63±12	57±13	0.015
LV mass index (g/m ²)	72±14	68±14	64±13	0.001
LV cardiac output (l/min)	6.9±2.4	6.9±2.4	6.1±2.3	0.026
Fibrosis -%	8.7	27.1	26.1	0.037

Conclusions: Heart iron was not absent in TI and the majority of the patients showed an heterogeneous distribution. A consistent number of the TI patients had the stigmata of the high cardiac output state cardiomyopathy and myocardial fibrosis seems to be related to the high cardiac output state. The signs of the high cardiac output state were controlled in the regular transfused patients. Conversely, the regular transfusions seem to be started too late for preventing myocardial fibrosis.

4544 | BEDSIDE

Focal inflammation in basal septal portion is related to the development of advanced atrioventricular nodal block in cardiac sarcoidosis

M. Orii, K. Hirata, T. Tanimoto, K. Ishibashi, T. Yamano, Y. Ino, T. Yamaguchi, T. Kubo, T. Imanishi, T. Akasaka. *Wakayama Medical University, Department of Cardiovascular Medicine, Wakayama, Japan*

Background: We hypothesized that focal inflammation would be related to development of cardiac events in patients with cardiac sarcoidosis (CS).

Purpose: To assess the relationship between advanced A-V block (AAVB), the most common cardiac event, and inflammation using fluorodeoxyglucose (FDG)-PET in CS patients.

Methods: Thirty-nine CS patients (13 with and 26 without AAVB; groups AAVB+ and AAVB-) who were diagnosed by consensus criteria were studied. FDG-PET and MRI were performed on the same day immediately after diagnosis of CS and before implantation of permanent pacemaker. Delayed-enhancement in MR image was defined as myocardial fibrosis, and FDG uptake in PET image as myocardial inflammation. The left ventricle were divided into 16 segments and analyzed.

Result: There was no difference in age, gender, steroid use, angiotensin-converting enzyme, serum and urinary calcium and high sensitive C-reactive protein between the 2 groups. Focal FDG uptake in the basal septal portion, which is a site of A-V nodal pathway, was observed in 10 patients (77%) of AAVB+, while

those in 5 patients (19%) of AAVB- ($p = 0.003$). On the other hand, DE in the basal portion was observed in 12 patients (92%) of AAVB+ and 18 patients (69%) of AAVB-, and there was no significant difference between 2 groups ($p=0.111$).

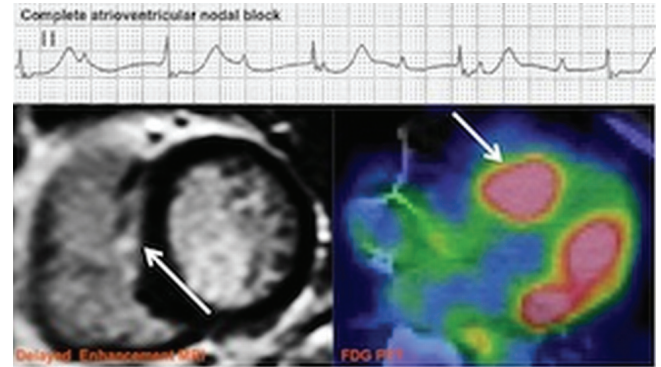


Figure 1. Inflammation of AV nodal pathway

Conclusion: Advanced A-V nodal block in CS was strongly related with inflammation of sarcoid lesion in the A-V nodal pathway than myocardial fibrosis.

4545 | BEDSIDE

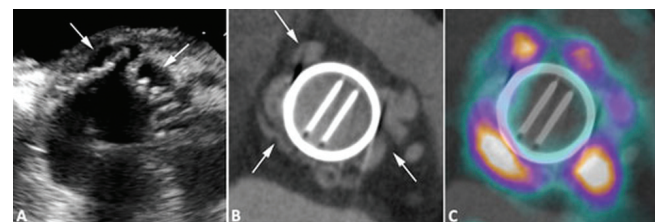
Fusion of cardiac computed tomography angiography and 18F-fluorodesoxyglucose positron emission tomography for the detection of complicated prosthetic heart valve endocarditis

W. Tanis¹, A. Scholtens², J. Habets³, R.B.A. Van Den Brink⁴, B. De Mol⁵, L. Cozijnsen⁶, L.A. Van Herwerden⁷, S.A.J. Chamuleau⁷, R. Budde³. ¹University Medical Center Utrecht, Department of Cardiology, Utrecht, Netherlands; ²University Medical Centre Utrecht, Department of Nuclear Medicine, Utrecht, Netherlands; ³University Medical Center Utrecht, Department of Radiology, Utrecht, Netherlands; ⁴Academic Medical Center, University of Amsterdam, Department of Cardiology, Amsterdam, Netherlands; ⁵Academic Medical Center, Department of Cardiothoracic Surgery, Amsterdam, Netherlands; ⁶Gelre Hospitals, Apeldoorn, Netherlands; ⁷University Medical Center Utrecht, Division Heart and Lungs, Department of Cardiothoracic Surgery, Utrecht, Netherlands

Purpose: PHV endocarditis is complicated by peri-annular extension (abscesses/mycotic aneurysms) in 50% of patients and has an in-hospital mortality of 30%. Transthoracic and Transesophageal Echocardiography (TTE and TEE) may fail to recognize peri-annular extensions, although this is an indication for urgent surgery. Therefore Computed Tomography Angiography (CTA) fused with 18F-Fluorodesoxyglucose Positron Emission Tomography (FDG-PET) may be of additional value.

Methods: PHV patients that underwent FDG-PET were selected from the hospital database. CTA images were fused with FDG-PET images and the Standardized Uptake Value (SUV) ratio was measured. Imaging findings were compared to the reference standard: surgical inspection.

Results: Eleven PHV endocarditis cases and four normal functioning PHV controls were identified. All cases and controls underwent TTE, TEE and CTA. In 11/11 (100%) endocarditis cases, imaging by fused FDG-PET and CTA detected high FDG uptake around the PHV. Surgical inspection confirmed peri-annular extension of endocarditis in all cases. Controls (n=4) were all free of significant FDG uptake. SUV ratios around the PHV ring were significantly ($p=0.001$) higher in endocarditis cases; 4.6 (IQR 3.8-5.1) compared to controls; 2.0 (IQR 1.7-2.1). SUV ratios around the PHV ring in cases were all above 2.6, whereas all controls had SUV ratio's below 2.3.



A: TEE, B: CTA, C: Fused CTA and FDG-PET

Conclusion: Fused cardiac FDG-PET and CTA imaging is a promising tool to correctly diagnose PHV endocarditis. SUV ratios may be used to discriminate PHV endocarditis with peri-annular extension from non-infected PHVs or PHVs endocarditis without peri-annular extension. Fused FDG-PET and CTA may be considered in patients with a high suspicion of PHV endocarditis but inconclusive routine work-up.