

## Clinical, histologic and serologic evaluation of patients with acute non-A–E hepatitis in north-eastern Brazil: is it an infectious disease?

Raymundo Paraná,<sup>(1,2)</sup> Liana Codes,<sup>(1,2)</sup> Zilton Andrade,<sup>(3)</sup> Luiz A. R. de Freitas,<sup>(3)</sup> Rogério Santos-Jesus,<sup>(1,2)</sup> Mitermayer Reis,<sup>(3)</sup> Helma Cotrim,<sup>(1,2)</sup> Simone Cunha<sup>(1,2)</sup> and Christian Trepó<sup>(4)</sup>

Non-A–E hepatitis and acute cryptogenic hepatitis are the names given to the disease of patients with clinical hepatitis, but in whom serologic evidence of A–E hepatitis has not been found. Over a period of 8 years, we evaluated in Brazil 32 patients who fulfilled the criteria for this diagnosis in order to determine patterns of the clinical illness, laboratory parameters, or histologic features. Each patient was subjected to virologic tests to exclude A–E hepatitis and cytomegalovirus/Epstein–Barr virus infection. Drug-induced hepatitis and autoimmune disease were also excluded. Wilson's disease was excluded in young patients. The course of the disease was clinical/biochemical recovery in 3 months in 25 patients and persistent alanine aminotransferase (ALT) elevation in 7 patients. Three of these had chronic hepatitis, and one had severe fibrosis on liver biopsy. During the acute illness, mean peak ALT was 1267 IU/L, bilirubin was 4.0 mg/dL, and ferritin was 1393 IU/mL. GB virus type C (GBV–C) was found in six patients, and TT virus (TTV) in five patients. We conclude that, in Brazil, non-A–E hepatitis probably originates from still unidentified viruses. The course of the disease and the histologic patterns are similar to those recorded for known viruses. Continuous survey for the specific etiologic agents is needed.

**Int J Infect Dis 2003; 7: 222–230**

### INTRODUCTION

Despite major progress in the development of new diagnostic tools for the etiologic determination of viral hepatitis, 20–30% of acute viral hepatitis cases remain unexplained.<sup>1</sup>

The existence of acute hepatitis of undetermined etiology suggests the possibility of infection by unknown viruses or autoimmune disease in the absence of the characteristic autoantibodies.<sup>2</sup> Therefore, while this enigma remains, the disease is alternatively designated as acute cryptogenic hepatitis or non-A–E hepatitis.

The clinical picture and the prognosis of this disease vary from mild forms with minimal symptoms to acute liver failure. Some cases may become chronic, with a potential to progress to cirrhosis.<sup>3,4</sup>

The new viruses, including GBV-C and TTV, do not seem to account for this disease, since the prevalence of

these viral agents in the asymptomatic population and their prevalence in acute non-A–E hepatitis are not significantly different from that observed in well-defined etiologic groups. Thus, clear evidence for their pathogenicity is still lacking.<sup>5,6</sup>

Owing to the wide variability in the clinical aspects and in the biochemical and histologic characterization of this syndrome, it is important to better define the clinical patterns and to explore whether different etiologies may exist.

Thus, the aim of this study was to describe the clinical, biochemical and histologic aspects of acute non-A–E hepatitis in Salvador-BA, north-eastern Brazil, and to evaluate the role of GBV-C, TTV and autoimmunity in the etiology of these selected cases.

### PATIENTS AND METHODS

From March 1992 to May 2000, 62 consecutive patients fulfilling the criteria of acute non-A–E hepatitis were evaluated. From these, 32 were enrolled in a prospective cohort study. The duration of follow-up ranged from 6 to 96 months ( $32 \pm 16$  months). A diagnosis of acute non-A–E hepatitis was made in patients with a clinical picture of acute hepatitis and alanine aminotransferase (ALT) level higher than 10 times the upper normal limit. Patients with a history of potentially hepatotoxic drug abuse, congestive heart failure, biliary obstruction and alcohol consumption higher than 40 g of ethanol daily were excluded.

<sup>(1)</sup>Gastro-Hepatology Unit, University Hospital of Bahia, Bahia, Brazil; <sup>(2)</sup>CPqMS-UFBA, Bahia-Salvador, Brazil; <sup>(3)</sup>CPqGM FIOCRUZ, Bahia, Brazil; <sup>(4)</sup>Inserm U. 271, Lyon, France.

This work had financial support from CNPq (Brazilian Agency for Research) and from CADCT (Center for Research Development of the State of Bahia, Brazil). The authors are also grateful to Dr Thomas Jones for reviewing this paper.

Address correspondence to Raymundo Paraná, Av Juracy Magalhães Jr 2096 Sala 510, Salvador-BA, Brazil 41920.000.

E-mail: unif@svn.com.br

Corresponding Editor: Jane Zuckerman, London, UK

A confidential questionnaire was filled out for the evaluation of clinical and epidemiologic data. Parenteral risks were also evaluated, such as dental treatment in the last 6 months, tattooing, blood transfusion and use of blood-derived products, and intravenous drug use (IVDU). Further data considered were living conditions, past personal or family hepatitis infections, sexual behavior, and alcohol consumption.

The serologic criteria used to accept non-A–E hepatitis were: virologic profile negative for anti-hepatitis A virus (HAV) IgM, anti-HBc IgM, hepatitis B surface antigen (HbsAg), anti-hepatitis E virus (HEV), anti-hepatitis C virus (HCV), anti-cytomegalovirus (CMV) IgM, anti-Epstein–Barr virus (EBV) IgM, HCV RNA, autoantibodies (ANA, ASMA, anti-LKM-I and AMA) with titers lower than 1/80, and negative Wilson's disease screening in patients younger than 25 years.

Viral hepatotropic markers were determined using commercial kits (Abbott, Chicago, IL, USA). CMV IgM and EBV IgM were tested in patients with none of the above-mentioned serologic markers for hepatotropic viruses, using Kits from BioMerieux (Lyon, France). Patients who tested positive for CMV and EBV were excluded.

HCV RNA was measured during the acute phase by two duplicate determinations at 15- and 30-day intervals, according to the method of Li et al.<sup>7</sup>

Autoantibodies were determined by indirect immunofluorescence during the acute phase and repeated from 30 to 90 days during follow-up.

Serum ferritin was determined in all patients during the acute phase and from 30 to 90 days during follow-up, using the chemiluminescence method of Sanofi-Pasteur (Paris, France). For comparison with known hepatitis viruses, we determined ferritin levels in stored serum samples from 54 patients with acute hepatitis A, 52 with acute hepatitis B, and 13 with acute hepatitis C.

Biochemical workups were carried out during the acute phase and every 15 days up to the third month. All analyses were then performed monthly up to the sixth month and then every 6 months.

GBV-C RNA was determined by PCR,<sup>8</sup> and TTV DNA was determined as previously described by Biagini et al.<sup>9</sup>

A liver biopsy was proposed during the acute phase, and always performed, at the latest, 6 months after disease onset in cases with still elevated ALT.

### Statistical analysis

Dichotomous variables were analyzed by the chi-square or Fisher exact test, when necessary. Group mean differences were compared by the Mann–Whitney test. The Spearman correlation coefficient was used to test the association between ALT and ferritin levels. All tests were performed using SPSS software, with the level of significance set at two-tailed  $\alpha = 0.05$  for all statistical tests.

## RESULTS

During the selection period, 62 patients were initially diagnosed as having acute cryptogenic hepatitis. Of these patients, 32 were admitted to the cohort study; 15 (47%) were females, and 17 (53%) were males. Patients who lived outside Salvador city and patients who did not consent to participate in the study were not included in this cohort. Their average age was 33.8 ( $\pm 27.3$ ) years.

Medical visits were scheduled every month up to 6 months, and every 3 months thereafter.

After filling in a confidential questionnaire, 77% reported sexual activity, while sexual promiscuity and/or sexually transmitted diseases (STDs) were observed only in nine patients (28%). Parenteral exposure was found in six patients (19%). Five of them reported dental treatment in the previous 6 months, and one admitted to IVDU. None of the patients had a history of blood transfusion or tattooing (Table 1).

Serum samples were collected on the occasion of each medical visit for biochemical determinations, and aliquots were stored at  $-70^{\circ}\text{C}$  for PCR assays.

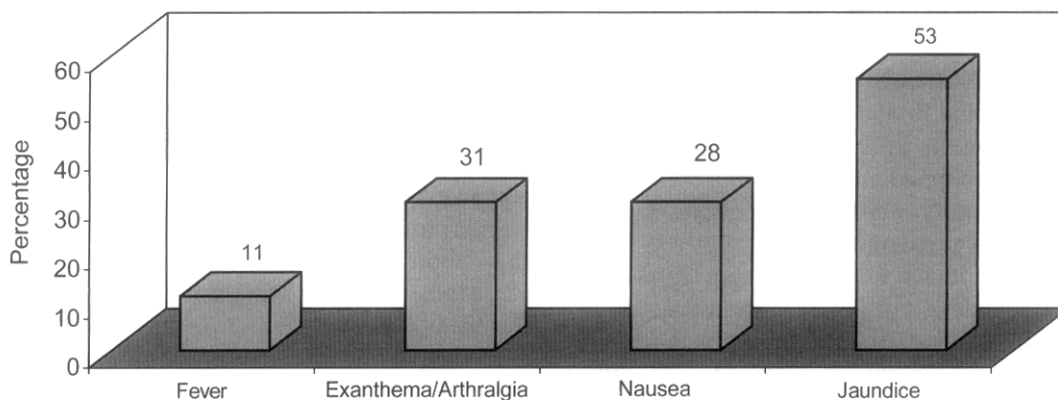
Different signs and symptoms of acute liver disease motivated the patients to seek medical care. A brief prodromic phase with arthralgia and exanthema was reported in 10 patients (31%). Seventeen patients (53%) became icteric, while nine (28%) showed 'nausea' and/or vomiting, leading to the diagnosis of acute hepatitis. Fever was uncommon, being observed in only 11% of the subjects (Figure 1).

All patients became asymptomatic within 3 months after the onset of the disease. Most of them recovered within a few weeks after disease onset.

During the acute phase (first 15 days), average ALT and bilirubin levels were 1267 ( $\pm 1048$ ) IU/L and 4.0 ( $\pm 5.2$ ) mg/dL, respectively. At this same time, serum ferritin reached an average level of 1393 ( $\pm 743$ ) IU/mL and fell rapidly after 30–90 days (Table 2). For the sake of comparison, we measured retrospectively in stored sera the serum ferritin levels of patients with acute hepatitis caused by known hepatotropic viruses (HAV,

**Table 1.** General characteristic of the cohort

| <i>Characteristics</i>               |                          |
|--------------------------------------|--------------------------|
| Age (mean, years)                    | 33.8 ( $\pm 27.3$ )      |
| Gender                               | 15 F (47%)<br>17 M (53%) |
| Parenteral risks                     |                          |
| Dental care                          | 5 (16%)                  |
| Blood transfusion                    | 0                        |
| IVDU                                 | 1 (3%)                   |
| Tattooing                            | 0                        |
| Household contact hepatitis patients | 5 (16%)                  |
| Sexual activity                      | 24 (77%)                 |
| Promiscuity and/or STD               | 9 (28%)                  |
| Alcohol abuse (<40 g/day)            | 11 (34%)                 |



**Figure 1.** Signs and symptoms during the acute phase in patients with non-A-E hepatitis.

**Table 2.** Biochemical tests during the acute and convalescence phases

| Test              | Acute phase<br>Mean/Range | Convalescence<br>Mean |
|-------------------|---------------------------|-----------------------|
| ALT (IU/L)        | 1267 / ±1048              | 64.7                  |
| Bilirubin (mg/dL) | 4.0 / ±5.2                | 0.93                  |
| Ferritin (IU/mL)  | 1393 / ±743               | 361.0                 |

HBV, HCV). Serum ferritin was present at levels of 522 (±270) IU/mL, 405 (±220) IU/mL, and 886 (±332) IU/mL, respectively. Serum ferritin was significantly higher in acute non-A-E cases than in cases of known etiology (Figure 2).

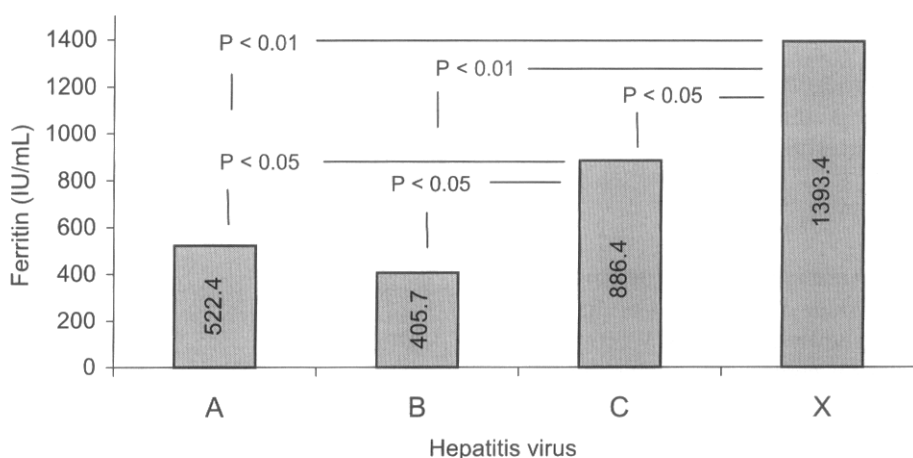
In order to establish a correlation between ferritin and ALT levels, we used the Spearman correlation coefficient. However, no statistical significance was observed (Figure 3).

Low titers of autoantibodies were found in 7/32 (22%) of the acute-phase cases, which subsequently returned to normal within 3 months after disease onset.

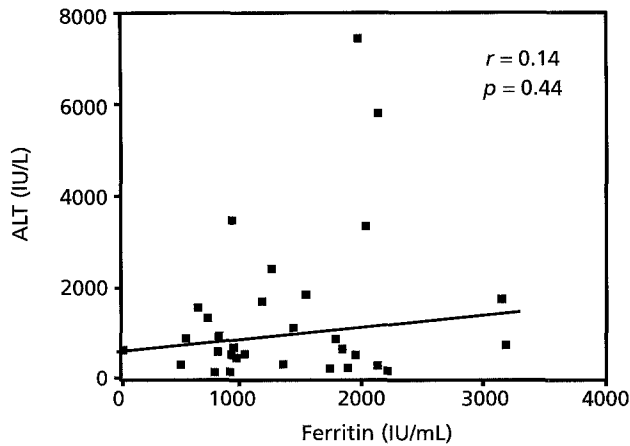
Six patients (19%) had GBV-C RNA in their serum, while 5/32 (16%) were found to be positive for TTV DNA. No clinical, histologic or biochemical peculiarities were found in GBV-C- or TTV-positive cases compared to patients with no GBV-C/TTV infection. In addition, only one patient who reported parenteral exposure (IVDU) was TTV -DNA- and GBV-C RNA-positive.

During the acute phase, 5 of the 32 patients gave consent for a liver biopsy. The histopathologic study always confirmed the pattern of acute hepatitis of a presumably viral nature. Extensive necrosis with portal-portal and portal-centrolobular vein bridges were observed in two patients, but both spontaneously recovered (Figures 4-6). Other features compatible with acute viral hepatitis were also observed, such as hepatocellular necrosis, infiltration of mononuclear inflammatory cells, and apoptotic bodies.

During follow-up, 7/32 (22%) patients exhibited elevated ALT levels 6 months after the acute disease. Whenever ALT levels fluctuated between two and six times above the upper normal limit, these patients were considered to be suffering from chronic non-A-E



**Figure 2.** Comparison of acute-phase ferritin levels between known viral hepatitis and non-A-E cases.



**Figure 3.** Correlation between ALT and ferritin during the acute phase of non-A–E hepatitis cases.

hepatitis. Comparison between chronic and resolved cases showed no difference regarding either the possible transmission route or ALT and bilirubin levels during the acute phase (Table 3).

Histopathology revealed a chronic hepatitis pattern of variable activity with variation of the degree of fibrosis in five of the above patients. Mild-to-moderate steatosis was present in four patients (Figures 7 and 8). Remarkably, Mallory bodies and steatosis were observed in one patient with no history of alcohol intake and no risk factors for non-alcoholic steato-hepatitis (NASH).

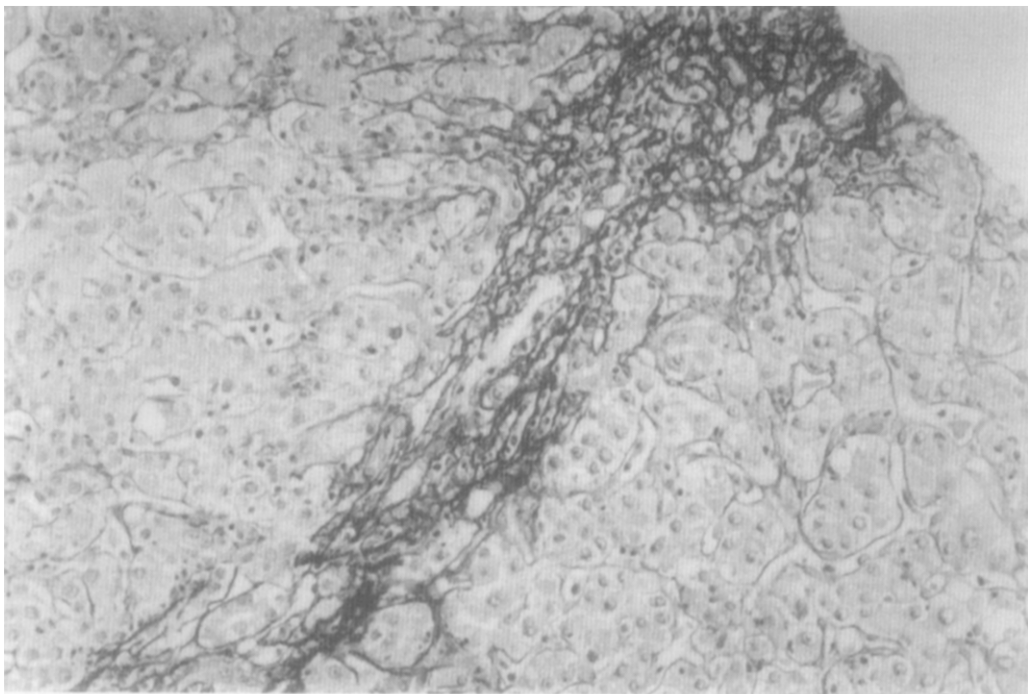
Conversely, one patient had minimal hepatic lesions 3 years after acute hepatitis, although he presented persistently elevated ALT levels (Figure 9).

These patients were treated with corticosteroids when chronic hepatitis was detected by liver biopsy or when clinical/biochemical deterioration was evident. Only one patient had a biochemical response after corticosteroid therapy.

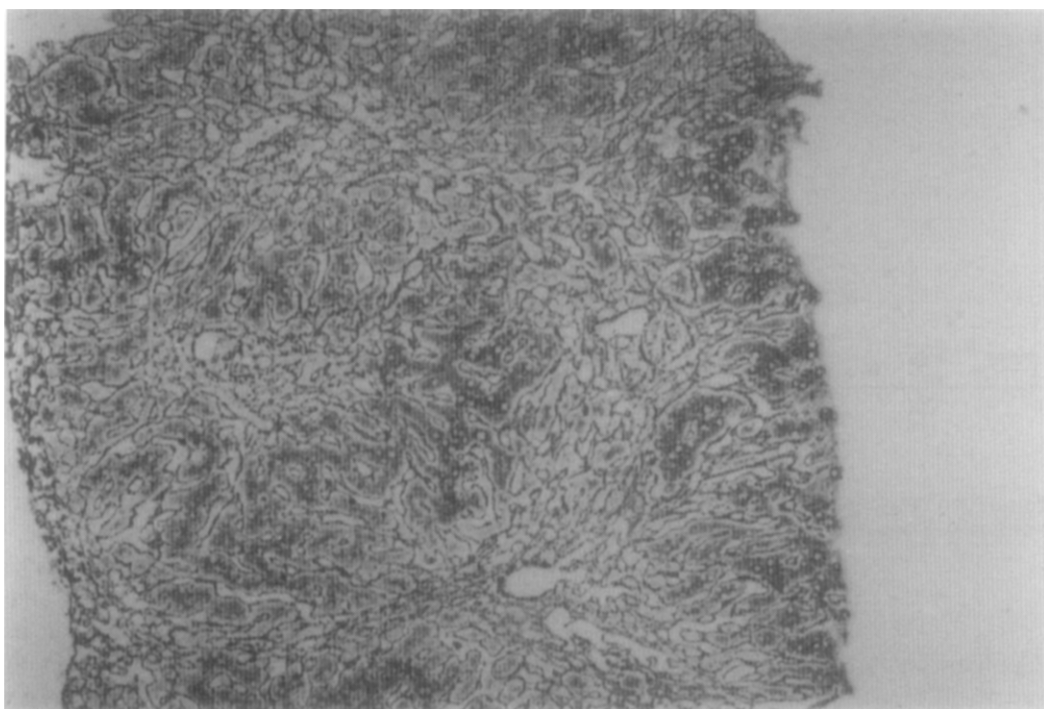
## DISCUSSION

The etiology of acute sporadic non-A–E hepatitis still remains completely unknown. Reports regarding clinical presentation and chronicity rate are conflicting, pointing to the necessity of further descriptive studies, mainly those with long-term follow-up after diagnosis was established during the acute phase.<sup>10</sup>

In the USA, a pivotal sentinel study found only 4% of acute non-A–E hepatitis cases, and 25% of these patients with non-A–E hepatitis had parenteral transmission risks.<sup>11</sup> On the other hand, non-A–E hepatitis seems to be more common in Greece, where many severe forms of the disease have been reported.<sup>12</sup> Our group has already demonstrated that sporadic acute non-A–E hepatitis is the most common entity among acute cases of non-A non-B hepatitis at referral liver units in north-eastern Brazil, suggesting that this disease is quite common in this region and could be of viral origin.<sup>13</sup> Another study from Argentina showed a broad spectrum of clinical presentation in 62 acute non-A–E hepatitis cases, and reported that two patients had traveled to Brazil before developing acute hepatitis.<sup>14</sup>



**Figure 4.** Extensive necrosis with portal–portal bridges, during the acute phase. H&E,  $\times 20$ .



**Figure 5.** Extensive necrosis with portal–portal and portal–centrilobular vein bridges, during the acute phase. H&E,  $\times 10$ .

**Table 3.** Biochemical parameters during the acute phase in patients with resolved and non-resolved acute non-A–E hepatitis.

| Characteristics   | Chronic<br>(mean/range)<br>(n = 07) | Resolved<br>(mean/range)<br>(n = 25) | P    |
|-------------------|-------------------------------------|--------------------------------------|------|
| ALT (IU/L)        | 1074.4 $\pm$ 988.1                  | 1464.0 $\pm$ 1812.6                  | 0.54 |
| Bilirubin (mg/dL) | 4.7 $\pm$ 4.4                       | 3.4 $\pm$ 3.0                        | 0.22 |

These data suggest that non-A–E hepatitis is a heterogeneous disease, probably common in South America, perhaps with regional peculiarities.

The lack of consensus about the diagnostic criteria used to define acute non-A–E hepatitis may account for the contrasting results reported in different studies, mainly in those from liver transplantation centers, where more severe cases prevail.<sup>15,16</sup>

Many viruses have been proposed as causative agents of acute non-A–E hepatitis, but definitive confirmation is still lacking. A togavirus-like particle was identified by electron microscopy, but no experimental reproduction of the disease has been reported.<sup>17</sup> A paramyxovirus has also been proposed as the etiologic agent of the giant cell non-A–E hepatitis, but this seems to be a rare disease, and there is no proof of a cause–effect relationship.<sup>18</sup> Recently, hantavirus infection was associated with some cases of non-A–E hepatitis in China,<sup>19</sup> and a hepatitis with fecal–oral transmission was described in India.<sup>20</sup>

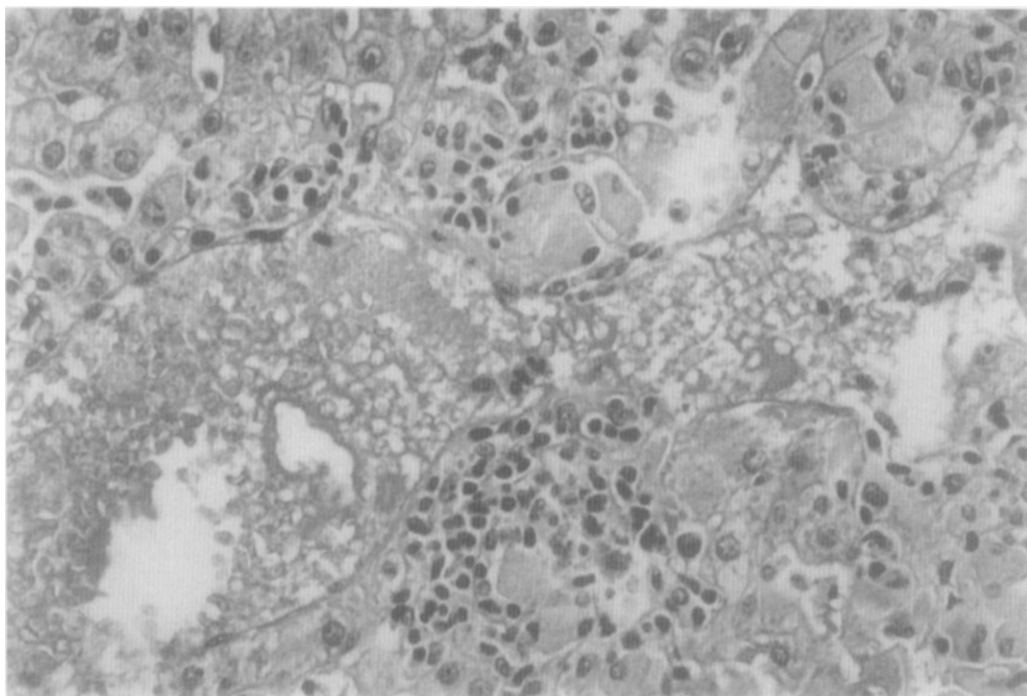
In our cases, no features compatible with hantavirus infection were seen. Also, we did not obtain epidemiologic

data that might suggest a disease transmitted by the fecal–oral route.

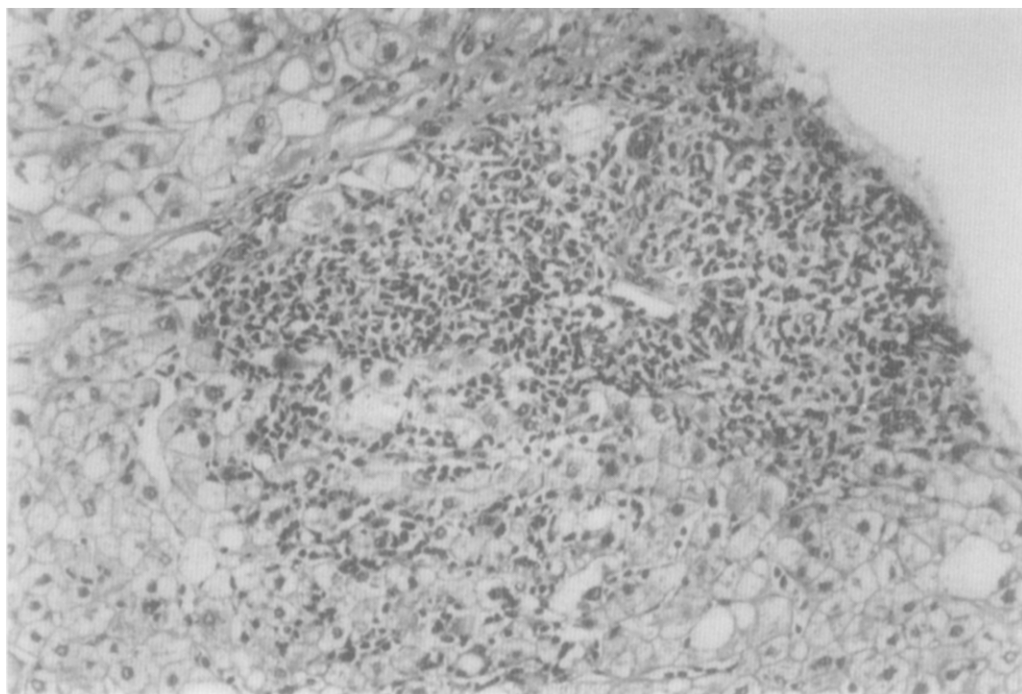
Recently, a new virus called GBV-C/HGV was thought to be implicated in some cases of non-A–E hepatitis, but data are conflicting. While some authors suggest that GBV-C can cause liver injury, many others have demonstrated that most GBV-C carriers have no liver injury.<sup>21</sup> Furthermore, GBV-C co-infection in patients who are carriers of HBV and HCV does not seem to influence the underlying liver disease.<sup>22</sup> Of our cases, only 19% were positive for GBV-C RNA, and there were no clinical, biochemical or epidemiologic peculiarities in GBV-C-positive patients.

More recently, a circovirus called TTV and other related viruses were proposed to cause non-A–E hepatitis. This putative hepatotropic virus may also be transmitted by the fecal–oral route.<sup>23</sup> Later epidemiologic studies have shown that this new agent is highly prevalent in Japanese and European populations, even in patients free from liver disease.<sup>24</sup> At present, TTV cannot be considered a causative agent of hepatitis, even though it can be abundant in liver tissue. In our cases, TTV DNA was found in only a few patients, in contrast to the results of the Japanese and European studies.<sup>25–28</sup>

This finding could be partially explained by previous exposure to this virus, which could generate a long-term immunologic response. As TTV seems to be also transmitted by the fecal–oral route, we may speculate that our population is massively exposed to this agent before adult life, and retains protective antibodies.<sup>5</sup> Alternatively, the detection method used in our laboratory for TTV diagnosis may not be sensitive enough, and is genotype-



**Figure 6.** Mononuclear cell infiltrate in a 32-year-old patient 6 months after acute hepatitis onset. H&E,  $\times 40$ .



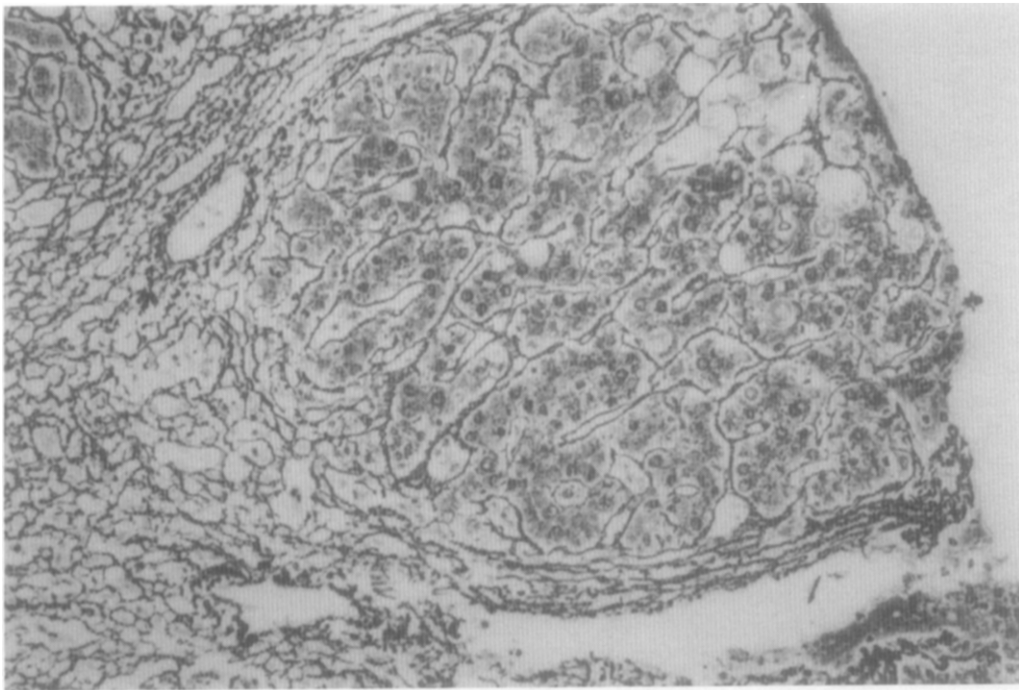
**Figure 7.** Portal tract inflammatory infiltrate with piecemeal necroses, 8 months after acute disease. H&E,  $\times 20$ .

dependent. This fact could explain the low prevalence of TTV DNA in our cases compared with the TTV prevalence described by other authors.

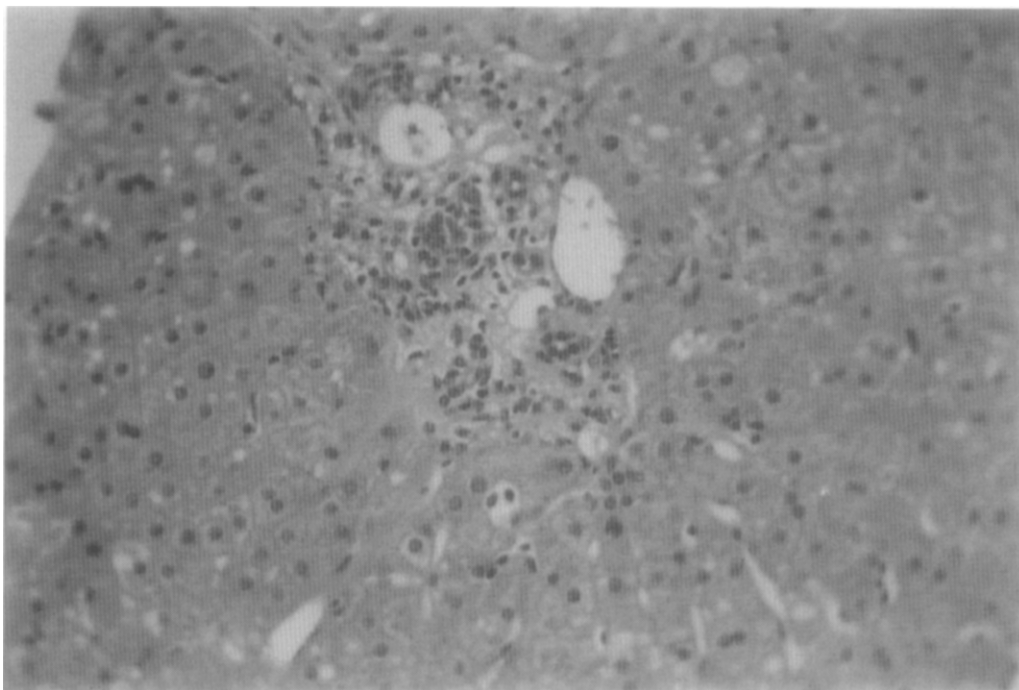
Recently, other new DNA viruses, called SEN virus, HTLM virus, and the circinovirus-related Sanban/Yanban virus, were described in some patients with acute and chronic hepatitis, but the results are pre-

liminary.<sup>29</sup> These viruses are closely related to TTV, and seem to belong to the same family, proposed to be called circinoviridae.<sup>30</sup>

On the other hand, the etiology of non-A–E hepatitis could be unrelated to a viral agent. Hepatotoxic drugs are always mentioned as a possible cause, but our protocol exhaustively excluded this possibility. In



**Figure 8.** Severe and progressing fibrosis 10 months after acute hepatitis (same patient as shown in Figure 5). H&E,  $\times 40$ .



**Figure 9.** Mild portal inflammatory infiltrate 3 years after acute hepatitis. H&E,  $\times 40$ .

addition, more than 50% of our patients presented a prodromal phase, suggesting a virus-related disease.

A seronegative variant form of autoimmune hepatitis is another potential diagnosis, mainly because atypical forms of this disease, lacking the classical autoantibodies (ANA, ASMA, and LKM-I), have been described.<sup>31</sup>

Many findings in our study strongly argue against this possibility. The ratio of male/female patients was about 1, contrasting with that expected for autoimmune hepatitis. Furthermore, during the acute phase, there were a few patients with low titers of autoantibodies, but these markers disappeared early during follow-up. This is completely unexpected in autoimmune liver disease.

In addition, most patients treated with corticosteroids did not present a biochemical response.

The spontaneous resolution of the disease observed in the majority of our patients strongly argues against autoimmune hepatitis, which is almost universally a chronic liver disease.

Above all, the liver biopsies obtained during the acute phase were much more suggestive of a virus-related hepatitis than hepatitis related to toxic or autoimmune hepatic injury. Finally, the clinical and biochemical presentations of the disease were similar to those of acute hepatitis due to known hepatotropic viruses.

Remarkably, ferritin levels were significantly higher in non-A–E hepatitis cases as compared to acute hepatitis caused by known hepatotropic viruses. The explanation of this finding is not clear, since neither hepatocyte release of ferritin after liver injury nor ferritin being released as an acute-phase inflammatory protein was indicated, with no correlation with ALT levels being detected.

Iron overload has been documented in some cases of chronic viral hepatitis, but the mechanism of iron accumulation is poorly understood.<sup>32</sup> There is a paucity of studies concerning acute hepatitis and iron overload. This finding warrants future studies in this field.

In conclusion, non-A–E hepatitis remains enigmatic and not fully understood. The clinical presentation of our cases, although quite variable, strongly suggested a viral disease with spontaneous resolution in most cases. At least 20% of the patients progress to chronic liver disease, with variable degrees of liver inflammation.

Non-A–E hepatitis seems to involve more than one disease, perhaps with regional peculiarities, and a variable prognosis. As suggested by some authors, it could be a virus-related disease, although other possibilities, as described for cryptogenic cirrhosis, should be ruled out.<sup>33,34</sup>

The improvement in sensitivity of PCR methods for HBV and HCV also warrants further studies, in order to define the pathogenic role of these viruses in some cases of cryptogenic hepatitis with an unusual serologic profile.<sup>35,36</sup>

## REFERENCES

- Buti M, Jardi R, Rodriguez-Frias F. Non-A, non-B, non-C, non-E acute hepatitis: does it really exist? In: Nishioka K, Suzuki H, Mishiro S, Oda T, eds. *Viral hepatitis and liver disease*. Tokyo: Springer-Verlag, 1994:77–79.
- Bruguera M, Sanchez-Tapias JM. What are cryptogenic hepatic diseases? *Med Clin (Barc)* 2000; 114(1):31–36.
- Charlton MR, Kondo M, Roberts SK, et al. Liver transplantation for cryptogenic cirrhosis. *Liver Transplant Surg* 1997; 3(4):359–364.
- Alter MJ, Gallagher M, Morris TT, et al. Acute non A–E hepatitis in the United States and the role of hepatitis G virus infection. *N Engl J Med* 1997; 336:741–746.
- Kato T, Mizokami M, Orito E, et al. High prevalence of TT virus infection in Japanese patients with liver diseases and in blood donors. *J Hepatol* 1999; 31:221–227.
- Brojer E, Grabarczyk P, Kryczka W, et al. Analysis of hepatitis G virus infection markers in blood donors and patients with hepatitis. *J Viral Hepatol* 1999; 6:471–475.
- Li JS, Tong SP, Vitvitski L, et al. Single-step nested polymerase chain reaction for detection of different genotypes of hepatitis C virus. *J Med Virol* 1995; 45:151–155.
- Jarvis LM, Davidson F, Hanley JP, et al. Infection with hepatitis G virus among recipients of plasma products. *Lancet* 1996; 348:1352–1355.
- Biagini P, Gallian P, Attoui H, et al. Determination and phylogenetic analysis of partial sequences from TT virus isolate. *J Gen Virol* 1999; 80:419–424.
- Greeve M, Ferrell L, Kim M, et al. Cirrhosis of undefined pathogenesis: absence of evidence for unknown viruses or autoimmune processes. *Hepatology* 1993; 17(4):593–598.
- Alter HJ, Bradley DW. Non-A, non-B hepatitis unrelated to the hepatitis C virus. *Semin Liver Dis* 1995; 15:110–120.
- Tassopoulos NC, Kuhns M, Hadziyannis S. Clinical and laboratory features of acute community acquired non-A, non-B, non-C hepatitis. In: Nishioka K, Suzuki H, Machiro S, Oda T, ed. *Viral hepatitis and liver diseases*. Tokyo: Springer-Verlag, 1994:80–84.
- Paraná R, Vitvitski L, Andrade Z, et al. Acute sporadic non-A, non-B hepatitis in northeastern Brazil: etiology and natural history. *Hepatology* 1999; 30(1):289–293.
- Frider B, Sookoian S, Castano G, et al. Detection of hepatitis G virus RNA in patients with acute non A–E hepatitis. *J Viral Hepatol* 1998; 5(3):161–164.
- Wright TL, Hsu H, Donegan E. Hepatitis C virus not found in fulminant non-A, non-B hepatitis. *Ann Intern Med* 1991; 115:111–112.
- Mason AL, Perrillo RP. The A to E and new hepatotropic viruses. *Liver Transplant Surg* 1996; 2:208–215.
- Fagan EA. Acute liver failure of unknown pathogenesis: the hidden agenda. *Hepatology* 1994; 19:1307–1312.
- Phillips MJ, Blendos LM, Purcell S. Syncytial giant-cell hepatitis. *N Engl J Med* 1991; 324:455–460.
- Meng G, Lan Y, Nakagawa M, et al. High prevalence of hantavirus infection in a group of Chinese patients with acute hepatitis of unknown aetiology. *J Viral Hepatol* 1997; 4(4):231–234.
- Arankalle VA, Chadha MS, Tsarev SA, et al. Seroepidemiology of water-borne hepatitis in India and evidence for a third enterically-transmitted hepatitis agent. *Proc Natl Acad Sci USA* 1994; 91:3428–3432.
- Mushahwar IK, Zuckerman JN. Clinical implications of GB virus C. *J Med Virol* 1998; 56:1–3.
- Thiers V, Pol S, Pertiso T, et al. Hepatitis G virus infection in hepatitis C virus positive patients co-infected or not with hepatitis B and/or human immunodeficiency virus. *J Viral Hepatol* 1998; 5:123–130.
- Jiang RL, Lu Q, Luo KX, et al. A prospective study of transfusion-transmitted virus transmission by blood transfusion. *J Viral Hepatol* 1999; 6:49–51.
- Tagger A, Donato F, Ribero ML, et al. A case-control study on a novel DNA virus (TT virus) infection and hepatocellular carcinoma. *Hepatology* 1999; 30(1):294–299.
- Nishizawa T, Okamoto H, Konishi K, et al. A novel DNA virus (TTV) associated with elevated transaminase levels



- in posttransfusional hepatitis of unknown etiology. *Biochem Biophys Res Commun* 1997; 241:92–97.
26. Okamoto H, Nishisawa T, Kato N, et al. Molecular cloning and characterization of a novel DNA virus (TTV) associated with posttransfusional hepatitis of unknown etiology. *Hepatology* 1998; 10:11–16.
  27. Takahashi K, Ohta Y, Yoshida N, et al. Very high prevalence of TTV infection in general population of Japan revealed by a new set of PCR primers. *Hepatology* 1998; 12:233–239.
  28. Naoumov NV, Ptrova EP, Thomas MG, et al. Presence of a newly described human DNA virus (TTV) in patients with liver disease. *Lancet* 1998; 352:195–197.
  29. Kato T, Mizokami M, Orito E, et al. High prevalence of TTV virus infection in Japanese patients with liver diseases and in blood donors. *J Hepatol* 1999; 31:221–227.
  30. Uemura T, Donahue P, Sottini A, et al. The incidence of SEN virus infection in transfusion-associated hepatitis. *Antiviral Therapy* 2000; 5(suppl 1): 11.
  31. Alter H. Beyond the C: new viruses and their relationship to hepatitis. In: Hoofnagle J, Schiff E, eds. Update on viral hepatitis/AASLD Postgraduate course, 2000:68–75.
  32. Czaja AJ, Carpenter HA, Manns MP. Antibodies to soluble liver antigen, P450IID6, and mitochondrial complexes in chronic hepatitis. *Gastroenterology* 1993; 105:1522–1528.
  33. Riggio O, Montagnese F, Fiore P, et al. Iron overload in patients with chronic viral hepatitis: how common is it? *Am J Gastroenterol* 1997; 92(8):1298–1301.
  34. Pessoa MG, Terrault NA, Ferrell LD, et al. Hepatitis after liver transplantation: the role of known and unknown viruses. *Liver Transplant Surg* 1988; 4(6):461–468.
  35. Ku NO, Wright TL, Terrault NA, et al. Mutation of human keratin 18 in association with cryptogenic cirrhosis. *J Clin Invest* 1997; 99(1):19–23.
  36. Cacciola I, Pollicino T, Squadrito G, et al. Occult hepatitis B virus infection in patients with chronic hepatitis C liver disease. *N Engl J Med* 1999; 341(1):22–26.
  37. Watanabe A, Aiba N, Harada R, et al. Etiology and prognosis of cryptogenic liver cirrhosis: possible contribution of hepatitis B virus. *J Med* 1997; 28(1–2):31–44.