

Clinical Neurofunctional Rehabilitation of a Cat with Spinal Cord Injury after Hemilaminectomy and Autologous Stem Cell Transplantation

Euler M. Penha^{1,2}, Paulo H. P. Aguiar¹, Stella Maria Barrouin-Melo¹, Ricardo S. de Lima^{2,3}, Ana Carolina C. da Silveira¹, Ana Rosa S. Oteló⁴, Claudia Maria B. Pinheiro⁴, Ricardo Ribeiro-dos-Santos^{2,5}, Milena B. P. Soares^{2,5}

¹Escola de Medicina Veterinária, Universidade Federal da Bahia, ²Centro de Pesquisas Gonçalo Moniz, Fundação Oswaldo Cruz, ³Universidade Federal do Vale do São Francisco, ⁴Faculdade Zacarias de Góes, ⁵Centro de Biotecnologia e Terapia Celular, Hospital São Rafael, Salvador, Brazil

Stem cell-based therapy has been investigated in a number of degenerative and traumatic diseases, including spinal cord injury. In the present study, we investigated the use of autologous mesenchymal stem cells in the functional rehabilitation of a domestic cat presenting a compressive L1-L5 fracture. Bone marrow cells collected by puncture of the iliac crest were cultured to obtain mesenchymal stem cells three weeks before surgery. Hemilaminectomy was performed, followed by injection of the mesenchymal stem cells in the injured area. Clinical evaluation of the animal prior to surgery showed absence of pain, muscular tonus, and panniculi reflexes. Seven days after surgery and cell transplantation the examination revealed a progressive recovery of the panniculus reflexes and of the responses to superficial and deep pain stimuli despite the low proprioceptive and hyperreflexic ataxic hind limbs. Physiotherapy protocols were applied for clinical rehabilitation after surgery. The cat's first steps, three-minute weight-bearing, and intestine and urinary bladder partial reestablishment were observed 75 days post-surgery. Our results indicate the therapeutic potential of mesenchymal stem cells in chronic spinal cord injuries.

Keywords: Domestic cat, Mesenchymal stem cells, Cellular therapy, Rehabilitation, Spinal cord injury

Introduction

The mammalian central nervous system presents a low capacity of axonal regeneration after being injured (1), possibly due to the inability of neural cells of self-rebuilding its functional structure in severe lesions (2). A considerable effort has been made to assess the therapeutic potential and biological principles of stem cell therapy for

degenerative and traumatic disorders. Stem cells have the ability of self-renewing and differentiating into specialized cells. Among the sources of stem cells, the bone marrow is the most extensively investigated. Bone marrow cells are easy to obtain and can differentiate into neurons in vitro (3) and in vivo (4).

Spinal cord injury in mammals, such as domestic cats, results in the loss of neurons and axonal degeneration at the lesion site. The process leads to severe functional impairment, paraplegia, or tetraplegia. Transplantation of different types of stem cells improved functional recovery after spinal cord injury in rodents and primates (5, 6). The beneficial effects appear to be mediated by several mechanisms, including replacement of lost cells and secretion of neurotrophic factors. Most importantly, the generation of

Accepted for publication August 9, 2012

Correspondence to **Milena Botelho Pereira Soares**

Centro de Pesquisas Gonçalo Moniz, Fundação Oswaldo Cruz, 121, Rua Waldemar Falcão, Candeal-Salvador-Bahia-Brazil, 40296-710.
Tel: +55-71-3176-2260, Fax: +55-71-3176-2272
E-mail: milena@bahia.fiocruz.br

oligodendrocytes that remyelinate spared axons in the vicinity of a lesion is believed to be the main mechanism of functional recovery (7).

The present report describes the use of autologous mesenchymal stem cells associated with surgery and physiotherapy in the clinical rehabilitation of a domestic cat with a chronic spinal cord injury. Apart from being an important achievement for Veterinary Medicine, stem cell transplantation developed for the treatment in spinal cord lesions in cats can also serve as a basis for studies of similar conditions in human patients.

Materials and Methods

Animal selection

Felis catus, 1.5 years old, male, hit by a car at the age of four months. An informed written consent was obtained from the cat's owner and the procedures were carried out observing the welfare guidelines of the Federal Council of Veterinary Medicine of Brazil.

Clinical evaluation and imaging

For the clinical examinations we used a haemostatic halsted tweezer to verify responses to deep and superficial pain and panniculi reflexes and an orthopedic rubber hammer to test the patellar and ischiatic nerve reflexes. Myelography was performed after trichotomy of the area from proximal occipital bone to distal 4th cervical vertebrae, surgical anti-sepsis, and intrathecal administration of contrast media (0.45 ml/kg; Ominipaque[®] 300, Sanofi, São Paulo, Brazil) between cervical 1st (C1) and cervical 2nd (C2) vertebrae with a 22 gauge needle. The images were obtained with a 100 mA X-ray machine (Brasmed, São Paulo, Brazil) in lateral and ventro-dorsal views 5, 15, 30, and 60 minutes after contrast infusion. Helical computed tomography (Prospect, GE, São Paulo, Brazil) was performed with the animal in anesthetic plane (induction with 6 ml/kg propofol IV and maintenance with isoflurane; Cristália, São Paulo, Brazil) monitored throughout the procedure with a vital multi parameters device (SurgiVet[®] Advisor[®] multi-parameter monitor, Waukesha, WI, USA). Two-mm slices from thoracic 11th to lumbar 5th vertebrae were obtained. Reconstructions were performed with DICOM Medical Imaging Software (DiCom Software Inc., Orlando, FL, USA).

Collection of bone marrow cells and mesenchymal stem cell culture

Two ml of bone marrow were aspirated through a puncture of the iliac crest. The mesenchymal stem cells were

separated by plastic adherence and cultivated in Dulbecco's Modified Eagle's Medium (DMEM; Life Technologies, GIBCO-BRL, Gaithersburg, MD, USA) containing 10% fetal bovine serum (Cultilab, Campinas, SP, Brazil) and incubated in a humidified atmosphere at 37° C and 5% CO₂. The media was changed every three days until 80% of confluence was achieved. Passages were done by incubation of cell cultures with 0.25% trypsin/1 mM EDTA (Sigma, St Louis, MO, USA) for in vitro expansion. Multipotency of mesenchymal stem cell cultures was confirmed by induction of adipogenic and osteogenic differentiation (data not shown).

Surgery and cell transplantation

After antiseptis and anesthesia procedures, left dorsal hemilaminectomy from L1 to L4 was performed. Prior to the application of the cells, the injured area was treated with 0.5 ml dimethylsulfoxide (Sigma) 10% in saline. The suspension of previously cultured autologous mesenchymal stem cells (7×10^8 cells) was mixed to a liquefied type I collagen solution at 37°C and maintained in water-bath at 37°C until being applied within and over the injured area of the spinal cord with a 25 gauge needle. The lesion was covered with paravertebral autologous fat tissue. The surgical synthesis was performed as standard procedure and a thoracic shelter bandage was applied.

Physiotherapy protocol

Physiotherapy of the cat was started after the normal hematological and biochemical parameters of renal and hepatic function were obtained. The protocol included fascias unstuck and connective tissue of dorsal pelvic release; lymphatic drainage; muscle stimulation in tail; work of muscle power; replacement of the animal in quadruped position with manual stimulation of the endplate; sequential kinesiotherapy of the joints of limb pelvic; performance of different groups of exercises, always trying to achieve active movement, initially reflective reflex, use of ball and a sequence of exercises targeting proprioception; reeducation of movement represented by the working muscle, and daily reexamination of all therapeutical procedures throughout the entire process, respecting the natural joint sequence, beginning proximally and ending distally, at final time, use of electric FES (Functional Electrical Stimulation) waves to improve muscle strength and the organization of responses already achieved. The physical care for two months has been intensive (2 hours long) and twice a day, followed by a reduced protocol (one hour daily during 3 months).

Results and Discussion

After being hit by a car, eight months before surgery, the animal was diagnosed as having a compressive spinal fracture from lumbar 1st (L1) to lumbar 4th (L4) vertebrae (Fig. 1). Neurological findings included absence of superficial and deep pain (Fig. 2A). Just remove the words: 'supplementary material', muscular tonus and panniculus reflexes from the lesion area to the nail edge of both pelvic limbs. Tenesmus in bladder and bowels was also observed, and massage to defecate and urinate was necessary. After vertebral ankylosis confirmation by simple radiographic exam, a myelographic exam was performed, showing a partial obstruction of spinal space, with multiple medullar gap areas one hour after contrast injection (Fig. 1).

No medullar reflexes were present before and during the next four post-operative days, including superficial and deep nociception reflexes. By the seventh day, however, a progressive recovery of the panniculus reflex (Fig. 2B~D) and superficial and deep pain were observed, although proprioceptive reflexes and hyperreflexic ataxic hind limb movement responses remained low. The first steps and a three minutes weight bearing were observed at 75 days post-surgery (Fig. 2E, F). The movement progression began slowly, albeit in a constant way, for three months, and the progression in weight bearing seemed to have stagnated after that period. These recovery findings occurred simultaneously with the partial re-establishment of intestine and urinary bladder functions.

The findings of motor hind limb recovery corroborate to the ones reported previously, showing hind limb movement partial recovery in a study using a mouse model of spinal cord injury (8). Hofstetter and colleagues (9) found similar clinical results in comparison with histologic findings of spinal cord injury regeneration. In fact, electrical and histological regeneration of neuronal tissue by stem cells has been described before (3). On the other hand, structural neuronal tissue renovation was already obtained

without functional improvement (10). A partial recovery of pelvic limbs has been obtained with physiotherapeutic protocols following spinal cord lesions in rats (11-13).

A previous report showed that, in animals submitted to traumatic spinal cord lesions, there was no neurological recovery when compression lasted six hours or more (14). This finding reinforces the idea that no gain of function should be expected with the cat of this report only with the surgical management, since the compression in this case lasted eight months.

Zurita and Vaquero (15) investigated the effects of bone marrow stromal cell transplantation in a model of spinal cord injury induced by a trauma in rats, and also found beneficial effects of bone marrow stromal cells in this model of chronic spinal cord injury, showing an improvement of motor activity using the Basso, Beattie, Bresnahan (BBB) scale. Akiyama et al. (16) have shown that neuronal remyelination was the major effect of bone marrow stromal cell therapy in the spinal cord of rats. Several cell types may play a role in the regeneration of the spinal cord. Some of these cells appear to give rise to a substantial proportion of scar-forming astrocytes, as well as to an increase in the number of myelinating oligodendrocytes after spinal cord injury, and could play a central role in its repair (17, 18). Although it has been reported that adult bone marrow stromal stem cells express germ-line, ectodermal, endodermal, and mesodermal genes prior to neurogenesis (19), it is likely that the main mechanism by which these cells exert a protective effect during brain or spinal cord injuries is by a paracrine effect (20).

A contrast-enhanced computed tomography was performed 90 days after surgery and showed a remaining compression area at L3 level (Fig. 3). Compression is cited in veterinary literature as the major cause of neurological deficit after traumatic injuries (1). Thus, one of the possible causes of the clinical benefits stagnation observed three months after administration of stem cells could be due to this remaining compressive lesion in the spinal

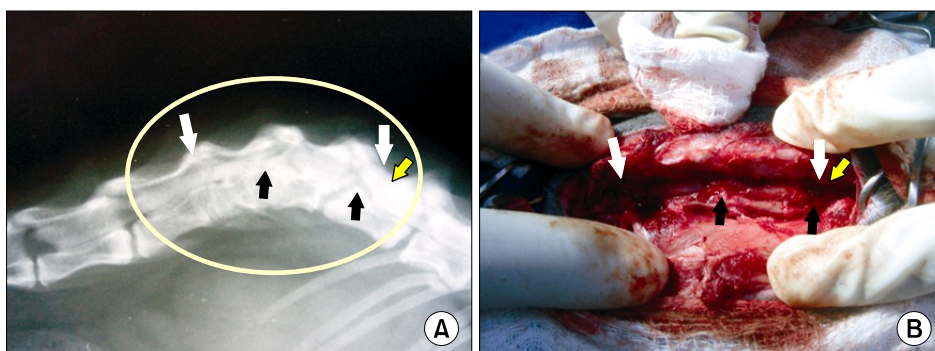


Fig. 1. Myelographic (A) and macroscopic surgical (B) images of damaged spine of a cat. A compressive lesion can be seen from lumbar 1st to lumbar 4th vertebrae (delimited area in A pointed out by the white arrows). A preserved area shows a macroscopic normal medullar aspect caudally to L1 vertebrae (red arrow). The two most severe compressed spine areas are indicated by the blue arrows.

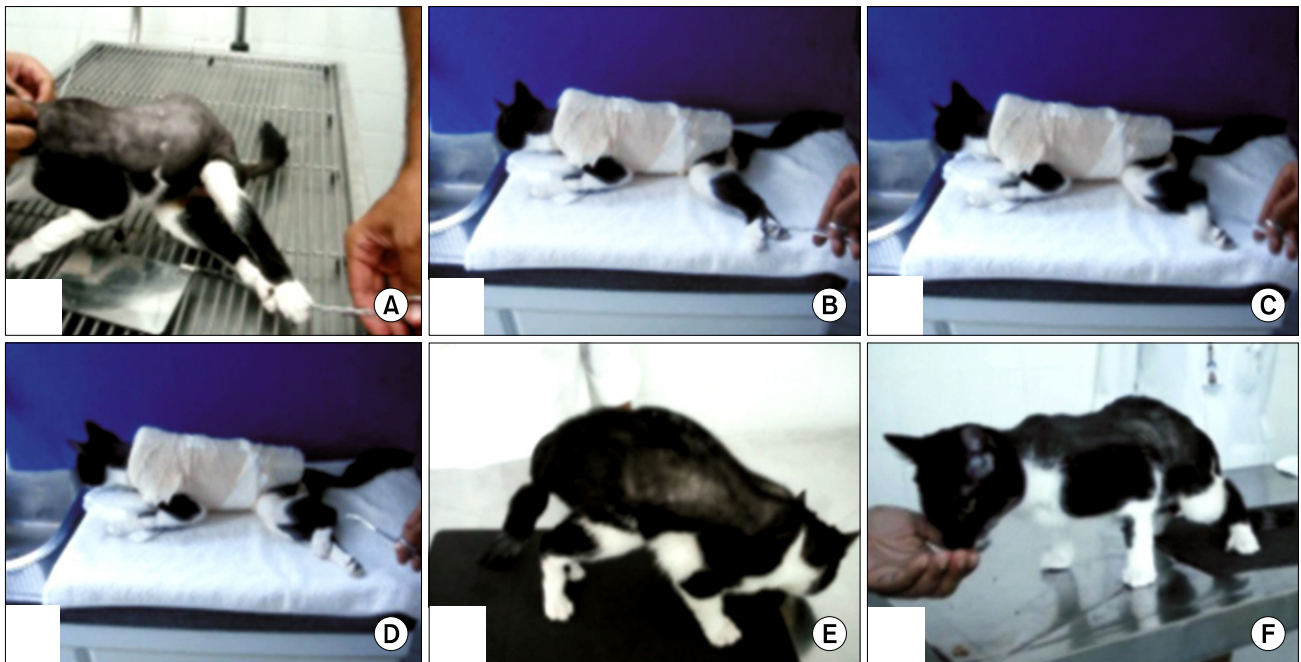


Fig. 2. Cat with areflexive pelvic limb during pre-surgical examination (A) and its clinical evolution 7 days post-surgery (B), with the same stimuli performed in A. Response of the cat with hind limb traction (C) and (D) 7 days after surgery and cell transplantation. Weight-bearing posture of the cat 70 days after surgery and cell transplantation (E) and (F). In images (B~D) the patient is wearing a protective bandage over the surgical incision.

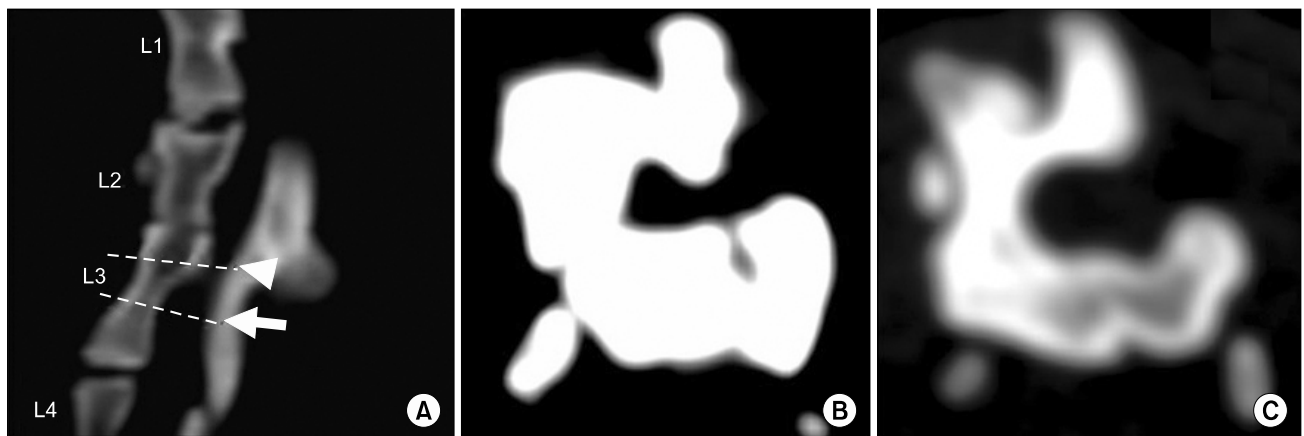


Fig. 3. Reconstructed computed tomography (A) and two axial images of a normal, not compressed spine area (B) and a still remaining compression area in lumbar 3rd vertebrae (C). The arrow and the arrowhead in (A) are the corresponding axial images in (B) and (C), with medullary areas of 0.4 cm² and 0.2 cm², respectively.

cord.

To our knowledge, this is the first study showing functional improvement in cats with chronic spinal cord injury which underwent stem cell transplantation. The pathways of gait improvement in this case study, such as the remodeling of anatomical structures with remyelination pattern induced by stem cells and the relearning of the nail movements and other muscles usage by physiotherapy techni-

ques, still need further investigation.

The clinical results of gradual functional response observed in the urinary bladder, smooth intestinal and striated hind limb skeletal musculature presented herein are believed to be a result of at least a partial substitution of damaged tissue by a functional one, even with a remaining spinal cord compression in the L3 area. Given the multifactorial aspects of the clinical improvement showed in

the present report, a long term study with more animals has been initiated using other neurodiagnostic tools, including the evaluation of evoked potential and nuclear magnetic resonance imaging before and after treatment.

As a clinical case report, we bring to discussion the progress obtained after the utilization of a conjunct of therapeutic methods, which included autologous stem cell transplantation, aiming to functionally recover the affected areas. Although no histopathologic study has been performed in this case, we hypothesize that without any structural earn, no functional gain is possible. In our short case study, we have shown a significant functional clinical improvement in a cat's spinal cord lesion treated with stem cell application followed by physiotherapy.

Acknowledgements

This work was supported by RENORBIO, CNPq, FINEP, and FAPESB.

Potential conflict of interest

The authors have no conflicting financial interest.

References

1. Bregman BS, Goldberger ME. Infant lesion effect: II. Sparing and recovery of function after spinal cord damage in newborn and adult cats. *Brain Res* 1983;285:119-135
2. Pluchino S, Zanotti L, Deleidi M, Martino G. Neural stem cells and their use as therapeutic tool in neurological disorders. *Brain Res Brain Res Rev* 2005;215:211-219
3. Woodbury D, Schwarz EJ, Prockop DJ, Black IB. Adult rat and human bone marrow stromal cells differentiate into neurons. *J Neurosci Res* 2000;61:364-370
4. Mezey E, Key S, Vogelsang G, Szalayova G, Lange D, Crain B. Transplanted bone marrow generates new neurons in human brains. *Proc Natl Acad Sci USA* 2003;100:1364-1369
5. Barnabé-Heider F, Frisé J. Stem cells for spinal cord repair. *Cell Stem Cell* 2008;3:16-24
6. Deng YB, Liu XG, Liu ZG, Liu XL, Liu Y, Zhou GQ. Implantation of BM mesenchymal stem cells into injured spinal cord elicits de novo neurogenesis and functional recovery: evidence from a study in rhesus monkeys. *Cytherapy* 2006;8:210-214
7. Enzmann GU, Benton RL, Talbott JF, Cao Q, Whittemore SR. Functional considerations of stem cell transplantation therapy for spinal cord repair. *J Neurotrauma* 2006;23:479-495
8. Okada S, Ishii K, Yamane J, Iwanami A, Ikegami T, Katoh H, Iwamoto Y, Nakamura M, Miyoshi H, Okano HJ, Contag CH, Toyama Y, Okano H. In vivo imaging of engrafted neural stem cells: its application in evaluating the optimal timing of transplantation for spinal cord injury. *FASEB J* 2005;19:1839-1841
9. Hofstetter CP, Schwarz EJ, Hess D, Widenfalk J, EL Manira A, Prockop DJ, Olson L. Marrow stromal cells form guiding strands in the injured spinal cord and promote recovery. *Proc Natl Acad Sci USA* 2002;99:2199-2204
10. Macias MY, Syring MB, Pizzi MA. Pain with no gain: Allodynia following neural stem cell transplantation in spinal cord injury. *Exp Neurol* 2006;201:335-348
11. Lankhorst AJ, ter Laak MP, van Laar TJ, van Meeteren NL, de Groot JC, Schrama LH, Harmers, FP, Gispen, WH. Effects of enriched housing on functional recovery after spinal cord contusive injury in the adult rat. *J Neurotrauma* 2001;18:203-215
12. Van Meeteren NL, Eggers R, Lankhorst AJ, Gispen WH, Hamers FP. Locomotor recovery after spinal cord contusion injury in rats is improved by spontaneous exercise. *J Neurotrauma* 2003;20:1029-1037
13. Hutchinson KJ, Gomez-Pinilla F, Crowe MJ, Ying Z, Basso DM. Three exercise paradigms differentially improve sensory recovery after spinal cord contusion in rats. *Brain* 2004;127:1403-1414
14. Delamarter RB, Sherman J, Carr JB. Pathophysiology of spinal cord injury. Recovery after immediate and delayed decompression. *J Bone Joint Surg Am* 1995;77:1042-1049
15. Zurita M, Vaquero J. Bone marrow stromal cells can achieve cure of chronic paraplegic rats: functional and morphological outcome one year after transplantation. *Neurosci Lett* 2006;402:51-56
16. Akiyama Y, Radtke C, Kocsis JD. Remyelination of the rat spinal cord by transplantation of identified bone marrow stromal cells. *J Neurosci* 2002;22:6623-6630
17. Meletis K, Barnabé-Heider F, Carlén M, Evergren E, Tomilin N, Shupliakov O, Frisé J. Spinal cord injury reveals multilineage differentiation of ependymal cells. *PLoS Biol* 2008;6:1494-1507
18. Hawryluk GW, Fehlings MG. The center of the spinal cord may be central to its repair. *Cell Stem Cell* 2008;3:230-232
19. Woodbury D, Reynolds K, Black IB. Adult bone marrow stromal stem cell express germline, ectodermal, endodermal, and mesodermal genes prior to neurogenesis. *J Neurosci Res* 2002;96:908-917
20. Uccelli A, Benvenuto F, Laroni A, Giunti D. Neuroprotective features of mesenchymal stem cells. *Best Pract Res Clin Haematol* 2011;24:59-64