

Original article

Assessment of the circumferential margins, extraprostatic extension and Gleason score in radical prostatectomy specimens: Comparison of a partial embedding method with supplemental total inclusion of peripheral tissues



Luiza Cavalcanti Fadul^a, Mariana Trindade da Silva^b,
Luiz Antonio Rodrigues de Freitas^{a,b,c,d}, Daniel Abensur Athanzio^{a,b,c,*}

^a Hospital Universitário Professor Edgard Santos, Rua Augusto Viana sn, Canela, Salvador 40110060, Brazil

^b Department of Pathology, Faculty of Medicine, Largo do Terreiro de Jesus s/n, Federal University of Bahia, 40025010 Salvador, Brazil

^c Gonçalo Moniz Research Center, Rua Waldemar Falcão, 121, Oswaldo Cruz Foundation, 40296710 Salvador, Brazil

^d Imagepat, Pathology Laboratory, Rua Altino Serbeto de Barros 41810570, 119 Salvador, Brazil

ARTICLE INFO

Article history:

Received 9 August 2015

Received in revised form

11 December 2015

Accepted 22 December 2015

Keywords:

Prostatic neoplasms

Pathology

Prostatectomy

ABSTRACT

Background: Recent data suggest that up to 21% of positive circumferential margins (PCM) and 47% of extraprostatic extension (EPE) samples may be missed when partial embedding methods are employed. Kim and colleagues (2009) suggested that total inclusion of the periphery (3 mm rim) of the prostate prevented the failure to detect PCM and EPE.

Design: Radical prostatectomy specimen ($n = 148$) slides were reviewed after adoption of a protocol that included a ~ 3 mm rim of peripheral tissues. We evaluated whether the analysis of supplemental slides of prostate periphery changed margin status, presence of EPE, Gleason score and extent of PCM and EPE. **Results:** Partial sampling resulted in missing 29% of PCM and 20% of EPE without using data from the supplemental slides of prostate periphery. Changes from focal to extensive disease were found in 11/21 (52%) cases of positive circumferential margins and in 5/13 (38%) cases of extraprostatic extension. Changes in the Gleason score were uncommon.

Conclusions: These results indicate the importance of including all the prostate peripheral tissue for microscopic analysis when partial embedding methods are adopted.

© 2015 Elsevier GmbH. All rights reserved.

1. Introduction

The widespread use of prostate cancer screening based on digital rectal examination and serum specific prostatic antigen concentration in the last three decades has increased the number of minimal volume prostate adenocarcinoma detected in needle biopsies and, as a consequence, small volume carcinomas in prostatectomy specimens. In the current practice, most radical prostatectomy specimens show small tumors that are not grossly visible [4,13].

Acinar adenocarcinoma of the prostate is a major public health problem, and radical prostatectomy specimens are common in most laboratories dedicated to surgical pathology worldwide. Surprisingly, there is still no consensus on how such specimens

should be handled even if some authorities are strong defenders of total embedding of prostatic tissues for all cases [4]. Based on the International Society of Urological Pathology (ISUP) consensus meeting, both total embedding and partial embedding are acceptable. It was consensual, however, to recommend that “if partial embedding is performed, a specific protocol should be followed, and the methodology should be documented in the pathology report [13]. Epstein and colleagues retrospectively studied 380 radical prostatectomy specimens from T1c (non-palpable, needle biopsy confirmed cancers) cases. The study population presumably contained small tumors that were likely to be grossly invisible. All specimens were processed in their entirety (mean of 34 slides). Adverse findings were defined as high Gleason score (≥ 7), positive margins and extraprostatic extension. Nine alternative partial sampling strategies were compared with the entire embedding to determine the feasibility of detecting these adverse findings. The approaches were based on extensive sampling of the posterior regions with several different methods for the midanterior areas. The finding of high Gleason scores oscillated from 83% to

* Corresponding author at: Universidade Federal da Bahia, Faculdade de Medicina da Bahia, Departamento de Patologia e Medicina Legal, Praça XV de novembro s/n, Largo do Terreiro de Jesus, 40025010 Salvador, BA, Brazil.

E-mail address: daa@ufba.br (D.A. Athanzio).

98% in the evaluated methods, while positive margins (71–100%) and extraprostatic extension (62–96%) had considerably broader ranges. The authors recommended two methods: embedding every posterior section plus one midanterior slice of each side (and all remaining anterior sections of one side if a sizable tumor was detected using microscopy) and a similar method that examined every posterior section that had been obtained only from the ipsilateral areas of previously positive needle biopsies. Using these two methods, high Gleason scores, positive margins and extraprostatic extensions were detected in 98, 100%, and 96% and 92%; 93% and 85% of cases for each method, respectively [14]. The asymmetric sampling of the prostate using these methods may possibly induce a potential bias in the calculation of either the tumor volume or the percentage of gland involvement [19]. It is an important issue because some assessment of the tumor extent is now part of the recommendations for the pathology reports of radical prostatectomy specimens [18]. The percentage of gland involvement and tumor volume are popular methods of estimation of the tumor size in radical prostatectomy specimens because they do not require whole mount sections as does the measurement of the linear extent of the index tumor [1].

Some reports disagree about the extent of relevant missed data by partial embedding methods. Vainer and colleagues reported that alternate slicing missed extraprostatic extension in two cases and positive margins in one case, from a case series of 238 prostatectomies [17]. Similar results were obtained by Llanos and colleagues in a smaller series of 48 specimens in which one case of extraprostatic extension and no case of positive circumferential margin were missed [10]. Recently, a large series of 618 specimens strongly discouraged partial sampling. Positive margins and extraprostatic extension were detected in 87% and 72% for the alternate slices, 79% and 53% for alternate posterior slices plus one midanterior section, and 95% and 93%, respectively, for the previously mentioned method recommended by Epstein and colleagues [8].

In a series of 148 specimens, Kim and colleagues evaluated five different methods. Positive margins and extraprostatic extension were detected in the following rates: 83% and 84% for the alternate slicing; 87% and 88% for the alternate slicing with the complete embedding of the biopsy-positive posterior quarters; 89% and 88% for every posterior half; 91% and 90% for every posterior half plus one midanterior section; and 100% and 100% for the alternate slicing with 3 mm of the peripheral rim of the remaining prostate, respectively. Importantly, the fourth method when used as the same protocol proposed by Epstein and colleagues (adding the remaining ipsilateral anterior section with the detection of a sizeable tumor) could also allow the detection of all cases of extraprostatic extension and positive margins; however, the number of blocks was similar to that of entire sampling [9].

Since the start of 2013, we have adopted the suggestion by Kim and colleagues of supplemental inclusion of 3 mm peripheral tissues of the prostate. Such change was implemented both at an academic and private laboratories in Salvador, Brazil. The aim of this study was to compare our standard method of partial embedding (representing two slides of each of 12 regions of the prostate) [1] with additional examination of supplemental sections of margins and extraprostatic tissues (SSMEPT). It may be useful for practicing pathologists to estimate how much relevant data are missed when using the currently adopted partial embedding methods and how much extra work is required to adopt the inclusion of SSMEPT.

2. Materials and methods

2.1. Patients and protocols

All consecutive radical prostatectomy specimens examined in the Laboratory of Pathology IMAGEPAT (Salvador, Brazil) between




Fig. 1. Partial sampling method of the gross specimen. Upper cassettes contain samples of twelve different regions of the prostate (separated into apical, intermediate and basal regions/right and left/posterior and anterior). Central cassettes contain samples from the apical and basal regions.

January 2013 (the date on which the proposed protocol was adopted) and December 2014 were included in the study. The project was approved by the Research Ethics Committee of Hospital Universitário Professor Edgard Santos (number 679163) located in Salvador, Brazil.

All radical prostatectomy specimens were examined using the same protocol as described in detail elsewhere [1]. Briefly, both the apical and basal margins were sectioned according to the cone method and sliced in the sagittal plane. The remnant prostate was transversally sectioned into three thirds of comparable thickness, representing an apical, an intermediary and a basal third sections. Each region was sectioned into quadrants (resulting in twelve zones). Each zone was further sliced, alternating one slice for the gross specimen archive and one slice to be processed. Two slices were processed for each region, skipping one slice (24 slices in the quadrant shape, including the circumferential margin). In most prostates, this approach was equivalent to embedding alternate slices. However, it could range from total embedding in cases of small specimens to large volumes sent to gross archive in cases of larger glands. Since January 2013, we have prospectively evaluated the results of this method with examination of SSMEPT, which were processed in independent blocks. A representative case is illustrated in Fig. 1.

In the academic institution (Hospital Universitário Professor Edgard Santos), the Pathology residents were trained, and performed the gross examination and handling of specimens. In the private laboratory (Imagepat), all procedures were performed by the same pathologist experienced in urologic pathology. A peripheral 3 mm rim of peripheral prostate tissue was processed in its entirety for all cases as suggested by Kim and colleagues [9]. When grossly visible adipose extraprostatic tissue was detected, all that material (even if thicker than 3 mm) was processed to ensure detection of the transition between prostate and extraprostatic tissue. Inked margins of the two distal thirds of the seminal vesicles and deferent ducts were not processed routinely. At the first institution, residents included all SSMEPT in additional cassettes without a standard pattern of distribution. At the second institution, all SSMEPT sections were processed in the pattern of six slices per cassette (Fig. 1). As a result, we used only the data from the latter to calculate how many additional blocks and slides were required to ensure examination of all SSMEPT.

Positive margins and the presence of extraprostatic extension were detected and reported as recommended [11]. For both the quantification of positive circumferential margins and extraprostatic extension, we used the criteria suggested by Wheeler and

colleagues for the classification of extraprostatic extension [21]: focal for involvements of less than one high-power field on ≤ 2 separate sections, and non-focal (extensive) for more extensive involvements. For analysis purposes, changes in Gleason grade were defined as modification of total Gleason score, change of primary pattern (e.g., 3+4 to 4+3) or detection of a tertiary Gleason 5 pattern.

3. Results

A total of 149 radical prostatectomy specimens were included in the study: 46 from Hospital Universitário Professor Edgard Santos (public hospital) and 143 from Imagepat (private laboratory). In only one case, prostate cancer was detected only in the supplemental slides. Thus, all further analysis was conducted with the remaining 148 specimens. In the private laboratory setting, a mean \pm SD of 11.4 ± 4.2 additional blocks and slides were required for all prostate peripheral tissue. The range was 4–27 additional slides.

In this series, the rate of positive circumferential margins was 39/148 (26%) before examination of SSMEPT, and rose to 55/148 (37%) after the study of supplemental slides. In other words, 16/55 (29%) cases of positive circumferential margins would have been missed without processing all prostate peripheral tissue (Tables 1 and 2). The rate of extraprostatic extension was 24/148 (16%) before examination of SSMEPT, and rose to 30/148 (20%) after the study of supplemental slides. In other words, 06/30 (20%) cases of extraprostatic extension would have been missed without processing all prostate peripheral tissue (Tables 1 and 2). Of note, eleven cases out of the 21 cases that would have been labeled as focal positive circumferential margins before examination of SSMEPT proved to have non-focal (extensive) margin involvement after evaluation all prostate periphery, i.e., 11/21 (52%) (Table 1). In addition, five cases out of the 13 cases that would have been labeled as focal extraprostatic extension before examination of SSMEPT proved to have non-focal (extensive) extraprostatic extension after evaluation all prostate periphery, i.e., 5/13 (38%) (Table 1).

Examination of supplemental sections changed the Gleason grading (score, primary pattern or detection of a tertiary pattern 5) in 8 out of 148 cases (5%).

We were also interested in how factors associated with prostate size, tumor size and morphologic features of tumor aggressiveness influenced the rate of missed relevant information when excluding data from SSMEPT. As shown in Table 2, positive circumferential margins were more likely to be missed in prostates with higher volumes (7/18: 39%), Gleason score ≤ 6 (5/10: 50%) and Gleason score > 7 (3/7: 43%) and were missed in both cases with positive apical margins (2/2: 100%). Extraprostatic extension was more likely to be missed in prostate glands with $\leq 10\%$ involvement by carcinoma (2/6: 33%), prostate carcinoma volume ≤ 3 ml (3/9: 33%) and Gleason score ≤ 6 (3/4: 75%).

Table 1

Frequency of positive circumferential margins, extraprostatic extension and Gleason score changes in radical prostatectomy specimens –comparison of a partial embedding method with supplemental total inclusion of peripheral tissues.

	Before supplemental sections	After supplemental sections	How many cases were interpreted as focal before supplemental sections?	How many focal lesions became non focal/extensive after supplemental sections?
	n/N (%)	n/N (%)	n	n/N (%)
Positive circumferential margins	39/148 (26)	55/148 (37)	21	11/21 (52)
Extraprostatic extension	24/148 (16)	30/148 (20)	13	5/13 (38)
Supplemental sections changed Gleason score or primary Gleason pattern		8/148 (5)		

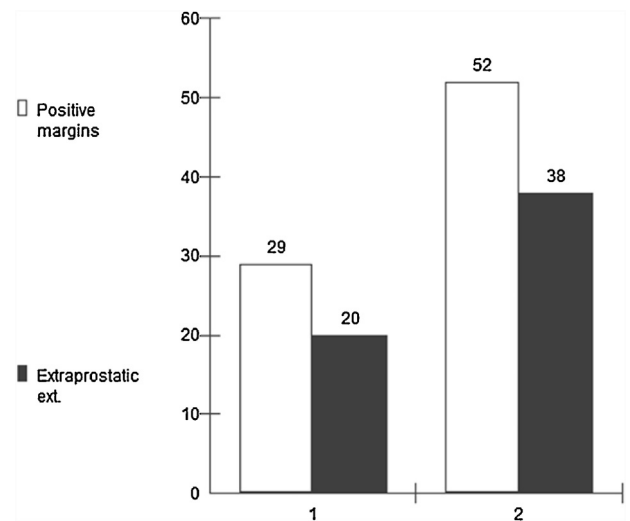


Fig. 2. Main changes in morphologic parameters of prostatectomy specimens after adoption of supplemental analysis of all prostate periphery. (1) Percentage of cases in which main findings would be missed if supplemental slides of prostate periphery were not processed. (2) Percentage of cases with findings initially labeled as focal that would have non-focal (extensive) involvement missed if supplemental slides of prostate periphery were not processed. Main findings shown are positive circumferential margins (white bars) and extraprostatic extension (solid bars).

4. Discussion

Partial sampling without evaluation of the whole prostate periphery missed 29% of positive circumferential margins and 20% of extraprostatic extension. Changes from focal to extensive involvement occurred in 11/21 (52%) cases with positive circumferential margins and in 5/13 (38%) cases with extraprostatic extension (Fig. 2).

In recent years, considerable attention has been focused on the role of the extent of positive margins and extraprostatic extension on outcome of patients with prostate cancer. From the consensus meeting of ISUP regarding surgical margins, it was agreed upon that pathologists should give a measure of the extent of positive margins while participants were divided between a subjective estimation (focal versus extensive) and measurement in mm of involved inked margins [16]. The importance of this information in pathology reports has highlighted differences in disease recurrence rates ranging from 0–13% in margin negative, 26–40% for focal and 65–69% for extensive positive margins [6,20]. In a series of 265 prostatectomies, recurrence rates were 14% for ≤ 3 mm positive margins and 53% for > 3 mm positive margins [2]. In contrast, other studies did not show that the linear extent of margin positivity is an independent predictor of recurrence when adjusted for Gleason score and preoperative factors [12]. After the consensus

Table 2
Frequency of missing cases of positive circumferential margins and extraprostatic extension without inclusion of supplemental sections of prostatic periphery and its association with prognostic factors reported in radical prostatectomy specimens.

	Positive circumferential margins 55/148 (37%) How many cases would have positive margins missed without supplemental sections? n/N (%)	Extraprostatic extension 30/148 (20%) How many cases would have extraprostatic extension missed without supplemental sections? n/N (%)
Total	16/55 (29)	06/30 (20)
HUPES (Public Hospital)	08/26 (31)	04/16 (25)
IMAGEPAT (Private laboratory)	08/29 (26)	02/14 (14)
Prostate volume >33 ml	07/18 (39)	01/09 (11)
Prostate volume ≤ 32 ml	09/37 (24)	05/21 (24)
>10 sections involved by carcinoma	07/23 (30)	03/18 (17)
≤10 sections involved by carcinoma	09/32 (28)	03/12 (25)
>10% of prostate gland involvement by carcinoma	07/29 (24)	04/24 (17)
≤10% of prostate gland involvement by carcinoma	09/26 (35)	02/06 (33)
Prostate carcinoma volume > 3 ml	08/25 (32)	02/17 (12)
Prostate carcinoma volume ≤ 3 ml	08/27 (30)	03/09 (33)
Primary Gleason 3	08/43 (19)	05/21 (24)
Primary Gleason 4 or 5	04/12 (33)	01/09 (11)
Gleason score ≤ 6	05/10 (50)	03/04 (75)
Gleason score 7	08/38 (21)	01/17 (06)
Gleason score > 7	03/07 (43)	01/08 (13)
>3% of prostate gland involved by high grade carcinoma	04/19 (21)	03/17 (18)
≤3% of prostate gland involved by high grade carcinoma	07/24 (29)	01/08 (13)
High grade prostate carcinoma >1 ml de volume	05/34 (15)	02/16 (13)
High grade prostate carcinoma ≤1 ml de volume	06/23 (26)	02/09 (22)
Apical margin – negative	14/53 (26)	06/29 (21)
Apical margin – positive	02/02 (100)	00/00 (00)
Basal margin – negative	10/52 (19)	06/29 (21)
Basal margin – positive	00/03 (00)	00/00 (00)
Seminal vesicles – free of disease	00/07 (00)	00/00 (00)
Seminal vesicles infiltrated by carcinoma	16/50 (32)	06/25 (24)

meeting, Billis and colleagues tested the influence of focal (defined as presence in up to two quadrants as focal) and extensive margins in a series of 360 prostatectomies, and biochemical recurrence was found in 38% of focal cases and 61% of cases with extensive margins. The extent of positive margins proved to be an independent risk factor for recurrence in that study [3].

A similar discussion has been taking place for extraprostatic extension. The majority of patients with extraprostatic extension will not progress over 10 years of follow-up after prostatectomy. At the ISUP consensus, a clear majority of pathologists confirmed that reporting extent of extraprostatic extension is required in pathology [11]. No consensus was reached, however, for the preferred method for quantification. A subjective estimation of focal (few glands outside the prostate) versus established (more than a few glands) involvement suggested by Epstein could separate the rates of disease progression of 18% and 35%, respectively, after an 8 year follow-up [5]. A more objective estimation as proposed by Wheeler (see Section 2) could separate the rates of disease progression of 27% and 52%, respectively, after a 5 year follow-up [21]. Sung and colleagues compared different methods of quantification of extraprostatic extension, including both mentioned above, and only the radial measurement of extraprostatic extension proved to be an independent predictor of disease progression when adjusted for preoperative PSA: 4-year PSA recurrence was 65% and 82% for patients with <0.75 mm and ≥0.75 mm extension, respectively [15]. After the consensus meeting, Billis and colleagues tested the influence of focal (defined as presence in up to one quadrant as focal) and extraprostatic extension in a series of 360 prostatectomies, and biochemical recurrence occurred in 26% of focal cases and 72% of cases with diffuse extraprostatic extension. Diffuse extraprostatic extension was not an independent predictor of disease progression when adjusted for other [3].

Our results mirror those from Kim and colleagues in the sense that the evaluation of all prostate peripheral avoided missing a substantial rate of positive margins and extraprostatic extension

when compared to alternate slides [9]. In the original series of 148 prostatectomies, five strategies were compared to entire specimen embedding. The rates of positive margins and extraprostatic extension were, respectively, 83% and 84% for alternate slices, 87% and 88% for alternate slices plus embedding of all quarters with positive needle biopsies, 89% and 88% for total embedding of posterior quarters, 91% and 90% for total embedding of posterior quarter plus one midanterior section of each side, and, finally, 100% and 100% for alternate slices plus total embedding of a ~3 mm rim of peripheral prostate tissue. Our protocol is slightly different from the above mentioned original strategy because we sample two quadrant-shaped slices for each of 12 regions (apical, intermediate and basal; further divided into anterior/posterior and right/left zones [1]). For Kim and colleagues' strict alternate slicing method, the mean number of blocks was 16 in contrast with 27 blocks for entire embedding. In our experience, sampling alternate slices of 12 regions of the prostate resulted in 12 blocks (24 sections) in all cases, with a variable number of additional slides (standard deviation of 11.4) for SSMEPT (Fig. 1). As an adaptation of the mentioned method, all the material (even if thicker than 3 mm) was processed to ensure detection of the transition between prostate and extraprostatic tissue when grossly visible amounts of adipose extraprostatic tissue were detected. This was important to insure that all extraprostatic tissue was available for histologic examination.

A limitation of our study is that we did not compare our sampling strategies with entire embedding. It is unlikely, however, that examination of all residual deep/central prostate could change the main diagnostic information that should be expressed in pathology reports of radical prostatectomies. By definition, positive margins and extraprostatic extension could be detected only in inked peripheral tissue of SSMEPT (see discussion above on the inclusion of all grossly visible adipose tissue). Previous works have shown that the Gleason score or measurements of tumor extent are usually comparable in entire and partial sampling methods and are not

the main concern when partial embedding strategies are adopted. Many authors will not agree on the rationale for total embedding of the prostate because the bulk of the gland will remain unexamined in paraffin blocks – with the actual histologic examination of the whole gland being approximately 0.17% of processed tissues [7,10].

Based on the present results, the authors suggest that inclusion of SSMEPT sampling should be part of all protocols of radical prostatectomy examination. It can be readily adopted by any academic or community pathology laboratory that currently uses partial sampling methods. Table 2 shows that some factors influenced the rate of missing positive circumferential or extraprostatic extension. These differences were not, in our view, indicative that inclusion of SSMEPT could be advocated for only a subset of specimens. Positive circumferential margins were more likely to be missed in prostates with higher volumes (7/18: 39%), which is intuitive because larger areas of inked margins will not be evaluated by partial sampling. Gleason score ≤ 6 (5/10: 50%) had a high rate of missing positive margins that may be explained by a stronger trend for this involvement to be focal in such cases. Aggressive tumors with Gleason score > 7 (3/7: 43%) also had a higher rate of missing positive margins. Both cases with positive apical margins also had apical margins missed by partial sampling (2/2: 100%), which may be explained by the fact that positive margins are more frequent in apical [16], and apical margins are surely an indication of a higher risk of positive margins in the apical third of the gland.

Extraprostatic extension has been more likely to be missed in prostate glands with $\leq 10\%$ involvement by carcinoma (2/6: 33%), prostate carcinoma volume ≤ 3 ml (3/9: 33%) and Gleason score ≤ 6 (3/4: 75%). All these characteristics would be indicative of smaller and more indolent tumors, which may be associated, when present, with focal extraprostatic extension. Therefore, examination of all SSMEPT would be required to detect these small foci.

5. Conclusion

In conclusion, partial sampling resulted in missing 29% of positive circumferential margins and 20% of extraprostatic extension. Changes from focal to extensive occurred in 11/21 (52%) cases of positive circumferential margins and in 5/13 (38%) cases of extraprostatic extension. Changes in Gleason score were uncommon. These results indicate the importance of inclusion of all prostate peripheral tissue for microscopic analysis when partial embedding methods are adopted.

Conflict of interest

The authors declare that they have no competing interests.

Acknowledgments

This work was supported by a grant (474596/2012-5) from CNPq (National Council for Scientific and Technological Development).

References

- [1] P.R. Athanazio, A.C. dos Santos, L.A. de Freitas, D.A. Athanazio, A modified point count method as a practical approach to assess the tumor volume and the percent gland involvement by prostate carcinoma, *Pathol. Res. Pract.* 210 (2014) 312–317.
- [2] R.J. Babaian, P. Troncoso, V.A. Bhadkamkar, D.A. Johnston, Analysis of clinicopathologic factors predicting outcome after radical prostatectomy, *Cancer* 91 (2001) 1414–1422.
- [3] A. Billis, L.L. Meirelles, L.L. Freitas, L.A. Magna, L.O. Reis, U. Ferreira, Influence of focal and diffuse extraprostatic extension and positive surgical margins on biochemical progression following radical prostatectomy, *Int. Braz. J. Urol.: Off. J. Braz. Soc. Urol.* 38 (2012) 175–184.
- [4] L. Egevad, Handling of radical prostatectomy specimens: total or partial embedding? *Histopathology* 59 (2011) 1011–1012, author reply 1012–1013.
- [5] J.I. Epstein, M.J. Carmichael, G. Pizov, P.C. Walsh, Influence of capsular penetration on progression following radical prostatectomy: a study of 196 cases with long-term followup, *J. Urol.* 150 (1993) 135–141.
- [6] J.I. Epstein, A.W. Partin, J. Sauvageot, P.C. Walsh, Prediction of progression following radical prostatectomy. A multivariate analysis of 721 men with long-term follow-up, *Am. J. Surg. Pathol.* 20 (1996) 286–292.
- [7] P.A. Humphrey, Complete histologic serial sectioning of a prostate gland with adenocarcinoma, *Am. J. Surg. Pathol.* 17 (1993) 468–472.
- [8] V. Iremashvili, S.D. Lokeshwar, M.S. Soloway, L. Pelaez, S.A. Umar, M. Manoharan, M. Jorda, Partial sampling of radical prostatectomy specimens: detection of positive margins and extraprostatic extension, *Am. J. Surg. Pathol.* 37 (2013) 219–225.
- [9] K. Kim, P.J. Pak, J.Y. Ro, D. Shin, S.J. Huh, Y.M. Cho, Limited sampling of radical prostatectomy specimens with excellent preservation of prognostic parameters of prostate cancer, *Arch. Pathol. Lab. Med.* 133 (2009) 1278–1284.
- [10] C.A. Llanos, C. Blieden, S.E. Vernon, Processing radical prostatectomies: an alternate-slice method is comparable with total embedding, *Ann. Diagn. Pathol.* 16 (2012) 284–287.
- [11] C. Magi-Galluzzi, A.J. Evans, B. Delahunt, J.I. Epstein, D.F. Griffiths, T.H. van der Kwast, R. Montironi, T.M. Wheeler, J.R. Srigley, L.L. Egevad, P.A. Humphrey, I.P.C. Group, International Society of Urological Pathology (ISUP) Consensus Conference on Handling and Staging of Radical Prostatectomy Specimens. Working group 3: extraprostatic extension, lymphovascular invasion and locally advanced disease, *Mod. Pathol.* 24 (2011) 26–38.
- [12] R.A. Marks, M.O. Koch, A. Lopez-Beltran, R. Montironi, B.E. Juliar, L. Cheng, The relationship between the extent of surgical margin positivity and prostate specific antigen recurrence in radical prostatectomy specimens, *Hum. Pathol.* 38 (2007) 1207–1211.
- [13] H. Samaratunga, R. Montironi, L. True, J.I. Epstein, D.F. Griffiths, P.A. Humphrey, T. van der Kwast, T.M. Wheeler, J.R. Srigley, B. Delahunt, L. Egevad, I.P.C. Group, International Society of Urological Pathology (ISUP) Consensus Conference on Handling and Staging of Radical Prostatectomy Specimens. Working group 1: specimen handling, *Mod. Pathol.* 24 (2011) 6–15.
- [14] A.E. Sehdev, C.C. Pan, J.I. Epstein, Comparative analysis of sampling methods for grossing radical prostatectomy specimens performed for nonpalpable (stage T1c) prostatic adenocarcinoma, *Hum. Pathol.* 32 (2001) 494–499.
- [15] M.T. Sung, H. Lin, M.O. Koch, D.D. Davidson, L. Cheng, Radial distance of extraprostatic extension measured by ocular micrometer is an independent predictor of prostate-specific antigen recurrence: a new proposal for the substaging of pT3a prostate cancer, *Am. J. Surg. Pathol.* 31 (2007) 311–318.
- [16] P.H. Tan, L. Cheng, J.R. Srigley, D. Griffiths, P.A. Humphrey, T.H. van der Kwast, R. Montironi, T.M. Wheeler, B. Delahunt, L. Egevad, J.I. Epstein, I.P.C. Group, International Society of Urological Pathology (ISUP) Consensus Conference on Handling and Staging of Radical Prostatectomy Specimens. Working group 5: surgical margins, *Mod. Pathol.* 24 (2011) 48–57.
- [17] B. Vainer, B.G. Toft, K.E. Olsen, G.K. Jacobsen, N. Marcussen, Handling of radical prostatectomy specimens: total or partial embedding? *Histopathology* 58 (2011) 211–216.
- [18] T.H. van der Kwast, M.B. Amin, A. Billis, J.I. Epstein, D. Griffiths, P.A. Humphrey, R. Montironi, T.M. Wheeler, J.R. Srigley, L. Egevad, B. Delahunt, I.P.C. Group, International Society of Urological Pathology (ISUP) Consensus Conference on Handling and Staging of Radical Prostatectomy Specimens. Working group 2: T2 substaging and prostate cancer volume, *Mod. Pathol.* 24 (2011) 16–25.
- [19] R.T. Vollmer, Percentage of tumor and tumor length in prostate biopsy specimens: a study of American veterans, *Am. J. Clin. Pathol.* 130 (2008) 940–943.
- [20] V.E. Weldon, F.R. Tavel, H. Neuwirth, R. Cohen, Patterns of positive specimen margins and detectable prostate specific antigen after radical perineal prostatectomy, *J. Urol.* 153 (1995) 1565–1569.
- [21] T.M. Wheeler, O. Dillioglulil, M.W. Kattan, A. Arakawa, S. Soh, K. Suyama, M. Otori, P.T. Scardino, Clinical and pathological significance of the level and extent of capsular invasion in clinical stage T1–2 prostate cancer, *Hum. Pathol.* 29 (1998) 856–862.