

# Central Nervous System Effects of Intrauterine Zika Virus Infection: A Pictorial Review<sup>1</sup>

Bianca Guedes Ribeiro, MD  
 Heron Werner, MD, PhD  
 Flávia P.P.L. Lopes, MD, PhD  
 L. Celso Hygino da Cruz, Jr, MD, PhD  
 Tatiana M. Fazecas, MD, MS  
 Pedro A. N. Dalto, MD, PhD  
 Renata A. Nogueira, MD, MS

**Abbreviations:** CMV = cytomegalovirus, IgM = immunoglobulin M, 3D = three-dimensional

**RadioGraphics** 2017; 37:1840–1850

<https://doi.org/10.1148/rgr.2017170023>

**Content Codes:** **CT** **HN** **MR** **NR** **OB** **PD**  
**US**

<sup>1</sup>From the Department of Radiology, Centro Médico Barrashopping, Clínica de Diagnóstico por Imagem (CDPI/DASA), Av das Américas 4666, Sala 325, 3º Piso, Barra da Tijuca, Rio de Janeiro 22640-902, Brazil (B.G.R., H.W., F.P.P.L.L., L.C.H.d.C., T.M.F., P.A.N.D., R.A.N.); Hospital Municipal Jesus, Rio de Janeiro, Brazil (B.G.R., T.M.F.); Americas Medical City, Rio de Janeiro, Brazil (B.G.R., L.C.H.d.C., R.A.N.); Instituto Fernandes Figueira—FIOCRUZ, Rio de Janeiro, Brazil (P.A.N.D.); and Department of Radiology, Universidade Federal do Rio Janeiro—UFRJ, Rio de Janeiro, Brazil (F.P.P.L.L.). Recipient of a Magna Cum Laude award for an education exhibit at the 2016 RSNA Annual Meeting. Received February 21, 2017; revision requested May 9 and received June 6; accepted June 21. For this journal-based SA-CME activity, the authors, editor, and reviewers have disclosed no relevant relationships. **Address correspondence** to B.G.R. (e-mail: [drbiancaribeiro@gmail.com](mailto:drbiancaribeiro@gmail.com)).

See discussion on this article by Levine (pp 1850–1853).

©RSNA, 2017

## SA-CME LEARNING OBJECTIVES

After completing this journal-based SA-CME activity, participants will be able to:

- Describe the most frequent prenatal imaging manifestations of Zika virus infection.
- Recognize postnatal neuroimaging features of Zika virus congenital infection.
- Explain how to differentiate the radiologic findings of Zika virus infection from those of other common congenital infections.

See [www.rsna.org/education/search/RG](http://www.rsna.org/education/search/RG).

Relatively few agents have been associated with congenital infections involving the brain. One such agent is the Zika virus, which has caused several outbreaks worldwide and has spread in the Americas since 2015. The Zika virus is an arbovirus transmitted by infected female mosquito vectors, such as the *Aedes aegypti* mosquito. This virus has been commonly associated with congenital infections of the central nervous system and has greatly increased the rates of microcephaly. Ultrasonography (US) remains the method of choice for fetal evaluation of congenital Zika virus infection. For improved assessment of the extent of the lesions, US should be complemented by magnetic resonance (MR) imaging. Postnatal computed tomography and MR imaging can also unveil additional findings of central nervous system involvement, such as microcephaly with malformation of cortical development, ventriculomegaly, and multifocal calcifications in the cortical-subcortical junction, along with associated cortical atrophy. The calcifications may be punctate, dystrophic, linear, or coarse and may follow a predominantly bandlike distribution. A small anterior fontanelle with prematurely closed sutures is also observed with Zika virus infection. In this review, the prenatal and postnatal neurologic imaging findings of congenital Zika virus infection are covered. Radiologists must be aware of this challenging entity and have knowledge of the various patterns that may be depicted with each imaging modality and the main differential diagnosis of the disease. As in other neurologic infections, serial imaging is able to help demonstrate the progression of the findings.

©RSNA, 2017 • [radiographics.rsna.org](http://radiographics.rsna.org)

## Introduction

The Zika virus is a single-stranded RNA arbovirus (arthropod-borne virus) of the family Flaviviridae (genus *Flavivirus*), which is the same family that includes the dengue virus and the chikungunya virus (1). The Zika virus is transmitted to humans and nonhuman primates by arthropod vectors, particularly by *Aedes* spp mosquitoes.

The virus was first identified in monkeys in Uganda in 1947. On that occasion, a rhesus monkey had contracted an infection with a virus that was later isolated and identified as the Zika virus. Five years later, the first human infection with the Zika virus was described in Nigeria (2–4). However, almost 50 years passed before the number of cases of Zika virus infection increased, with the first outbreak reported in 2007 on Yap Island (Micronesia) (5). An epidemic spread of the disease was later observed in French Polynesia in 2013, and another outbreak was reported in New Caledonia in 2014 (2,5–9).

During the outbreak in French Polynesia, some neurologic complications associated with Zika virus infection were reported. However, it was only recently in the findings from a retrospective study that investigators attributed the increased number of cases of neonatal

## TEACHING POINTS

- US remains the imaging modality of choice for evaluating fetuses with congenital Zika virus infection. For a better evaluation of the extent of the lesions, US should be complemented by magnetic resonance (MR) imaging.
- Postnatal CT and MR imaging can also unveil additional findings with regard to involvement of the central nervous system, including the occurrence of microcephaly with malformation of cortical development, ventriculomegaly, and multifocal dystrophic calcifications in the cortex and subcortical white matter, along with associated cortical atrophy.
- A small anterior fontanelle with prematurely closed sutures may also be seen in neonates with Zika virus infection.
- Although skull deformities are better evaluated with CT, MR imaging can also be used to analyze them. These abnormalities seem to be secondary to a loss of brain parenchymal volume caused by extensive brain damage, which results in a collapse of the frontal and parietal bones, rendering a flattened appearance associated with scalp protrusion and redundant skin in the occipital region.
- The calcifications in congenital Zika virus infection have a cortical or mainly subcortical distribution and have been a recurring finding in all of our cases of microcephaly associated with prenatal Zika virus infection.

microcephaly observed during that period to congenital Zika virus infection (7,10).

The link between Zika virus infection and microcephaly in Brazil was first reported in October and November 2015, when an increased number of cases of microcephaly were observed in the northeastern region of the country. The greatest challenge emerged in November 2015, when the Brazilian Ministry of Health attributed the observation of a 20-fold increase in the number of cases of neonatal microcephaly in the northeastern region of the country to the occurrence of congenital Zika virus infection, particularly in the state of Pernambuco. After that observation, the epidemic spread rapidly to more than 30 nations, affecting more than 2 million individuals in South America and the Caribbean (2,3,11–13). This issue led the World Health Organization to declare in 2016 that the Zika virus infection was a “global public health emergency” of international concern (14). In addition to neurologic complications, some reports have shown a possible association between acquired Zika virus infection and autoimmune complications in adults, including Guillain-Barré syndrome, transverse myelitis, and acute meningoencephalitis.

Zika virus infection has a self-limited course, and only 20% of the infected patients manifest symptoms, which are usually mild in nature and include fever, small joint pain, myalgia, maculopapular rash, retro-orbital headache, and conjunctivitis (2,3).

The laboratory diagnosis of Zika virus infection is based on demonstration of the virus in the blood (acute phase) and urine (after the first week of symptoms) by using real-time reverse transcription–polymerase chain reaction (RT-PCR) analysis to detect the viral RNA. The diagnosis may also be established with (a) analysis for immunoglobulin M (IgM) against the virus, which is measured with the enzyme-linked immunosorbent assay (ELISA), and (b) the plaque reduction neutralization test for antibodies against the Zika virus. This test determines the occurrence of virus-specific neutralizing antibodies and identifies the occurrence of an eventual cross-reaction with other correlated infections, such as infections with the dengue virus and the chikungunya virus (2). A major disadvantage is that the plaque reduction neutralization test is a costly and labor-intensive test.

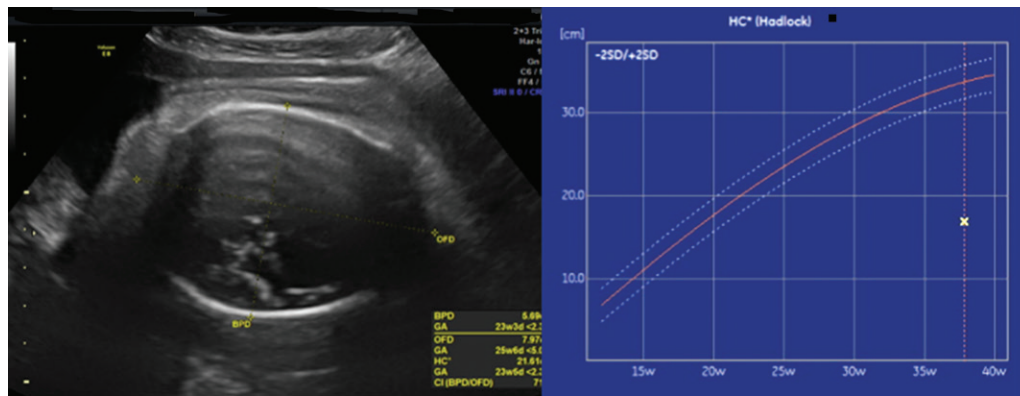
In some cases of maternal Zika virus infection, the diagnosis is established retrospectively and confirmed with serologic assays after a report by the patient of a maculopapular rash during pregnancy. According to public authorities in Brazil, the country experienced during the past 2 years a progressive increase in the number of infants with microcephaly, with a total of 4783 suspected cases and 404 confirmed cases. Additional neurologic disorders have also been described recently. Because many patients are entirely asymptomatic during the infection, the extent of the monitoring required for pregnant women during a Zika virus epidemic has not yet been established (10,12).

A detailed ultrasonographic (US) evaluation is essential to estimate the patient’s gestational age and allow accurate fetal measurements. A baseline US examination should be performed immediately upon suspicion of Zika virus infection or during the evaluation of pregnant women in high-risk (epidemic) areas. The ideal interval for subsequent US evaluations is still unclear, but a consensus panel of the International Society of Ultrasound in Obstetrics and Gynecology and a surveillance protocol by the Brazilian Ministry of Health recommend subsequent US evaluations every 6 weeks. If any abnormality is found, US evaluations should be performed every 2–3 weeks, according to these recommendations (15,16).

Microcephaly is not the only malformation observed in these infants and may represent only the tip of the iceberg in this scenario, because in the results of several studies, investigators have now shown that Zika virus infection may cause direct damage to the human nervous system (2).

The main challenge for radiologists working in endemic regions is to become familiar with the perinatal imaging findings of congenital Zika

**Figure 1.** Microcephaly in a 37-week fetus with congenital Zika virus infection acquired in the first trimester of gestation of a 27-year-old mother. **(a)** Left: Axial transabdominal US image shows microcephaly of the fetal head (calipers) at 37 weeks of gestation. Right: Graph of the head circumference in centimeters (y-axis) versus the gestational age in weeks (x-axis) shows that the head circumference at 37 weeks of gestation ( $x$ ) is less than the 5th percentile. Red curve represents the mean (light blue curves represent  $\pm$  standard deviations). **(b)** Three-dimensional (3D) facial reconstruction US image shows a reduced frontonasal surface and craniofacial disproportion.

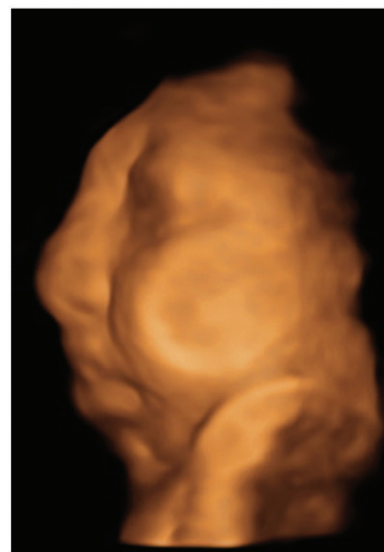

**a.**

virus infection. This familiarity is particularly important with regard to prenatal screening of pregnant women in such regions. Little is still known about the exact mechanisms by which the presence of the Zika virus leads to teratogenic effects. Infection with the Zika virus has been recently linked to possible dysregulation of several signaling pathways, including downregulation of genes affecting the cell cycle and upregulation of apoptosis genes potentially affecting the fetus during the entire pregnancy. Therefore, the identification during gestation of the critical moments in which the Zika virus begins to exert neurotropic effects is probably key in the development of strategies to minimize the effect of the disease. Some indirect findings suggest that the germinal matrix is the principal target for the Zika virus (2), which may explain in part the imaging findings in children infected with the virus.

Advances in imaging technology have led to vast improvements in perinatal evaluation. US remains the imaging modality of choice for evaluating fetuses with congenital Zika virus infection. For a better evaluation of the extent of the lesions, US should be complemented by magnetic resonance (MR) imaging. After birth, the imaging modalities of choice are transfontanellar US, computed tomography (CT), and MR imaging. US is currently the primary modality for fetal assessment during pregnancy and after birth; this modality is considered safe and is a cost-effective, patient-friendly, and radiation-free modality. When satisfactory results cannot be obtained with US evaluation, MR imaging may be performed to improve the diagnostic accuracy, especially in cases of fetal brain abnormalities (17).

The surveillance protocol recommended by the Brazilian Ministry of Health in the follow-up of infants at high risk of Zika virus infection or with

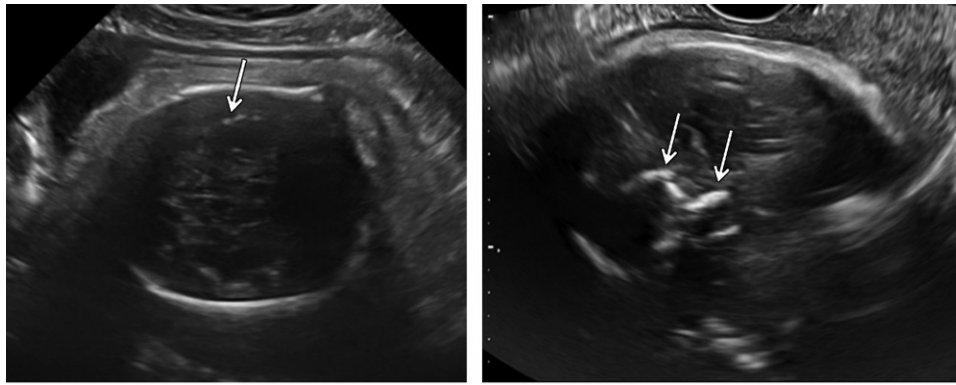


**b.**

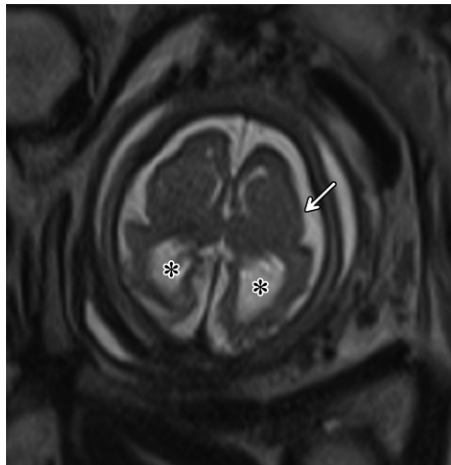
confirmed Zika virus infection recommends the use of CT in the investigation of cases of microcephaly (16). With regard to postnatal imaging, CT has a high sensitivity for the identification of brain calcification when such a finding is not observed at US evaluation. CT is also able to be used to evaluate the shape of the skull, as well as the fontanelles and sutures, to improve the detection of microcephaly.

Because Zika virus infection is a new entity, the application of different imaging modalities, such as CT and MR imaging, to evaluate and follow up infected patients may uncover previously unknown information about the disease and its consequences. Postnatal CT and MR imaging can also unveil additional findings with regard to involvement of the central nervous system, including the occurrence of microcephaly with malformation of cortical development, ventriculomegaly, and multifocal dystrophic calcifications in the cortex





**a.** **b.**  
**Figure 2.** Brain calcifications in a 37-week fetus with congenital Zika virus infection acquired during the 12th week of gestation. (a) Transabdominal US image shows calcifications (arrow) on the surface of the brain. (b) In this case, an endovaginal US image better depicts the calcifications (arrows) because of the cephalic fetal presentation.



**Figure 3.** Microcephaly with cortical atrophy and ventriculomegaly in a 36-week fetus with congenital Zika virus infection acquired in the first trimester of gestation. Axial T2-weighted fetal MR image shows microcephaly with diffuse cortical atrophy, which is more evident in the occipital lobes, along with associated ventriculomegaly (\*). A simplified pattern of cortical sulci and gyri (arrow) is also depicted.

and subcortical white matter, along with associated cortical atrophy.

On the basis of these considerations, the aim of this review is to discuss the prenatal and postnatal neurologic imaging findings of congenital Zika virus infection.

### Prenatal US

Brain abnormalities related to Zika virus infection may be primarily observed with prenatal US, especially in the third trimester of pregnancy, and US may be complemented by other imaging modalities as necessary. Measurement of the head circumference is a crucial evaluation and one of the main tools to detect microcephaly (Fig 1).

Congenital microcephaly is a neurologic abnormality present at birth and defined by a head circumference measurement that is 2 standard deviations less than either the mean value or the 2nd percentile for age and sex (18). This abnormality is associated with a reduction in brain volume and frequent intellectual and/or motor disabilities, including speech impairment, poor neurocognitive

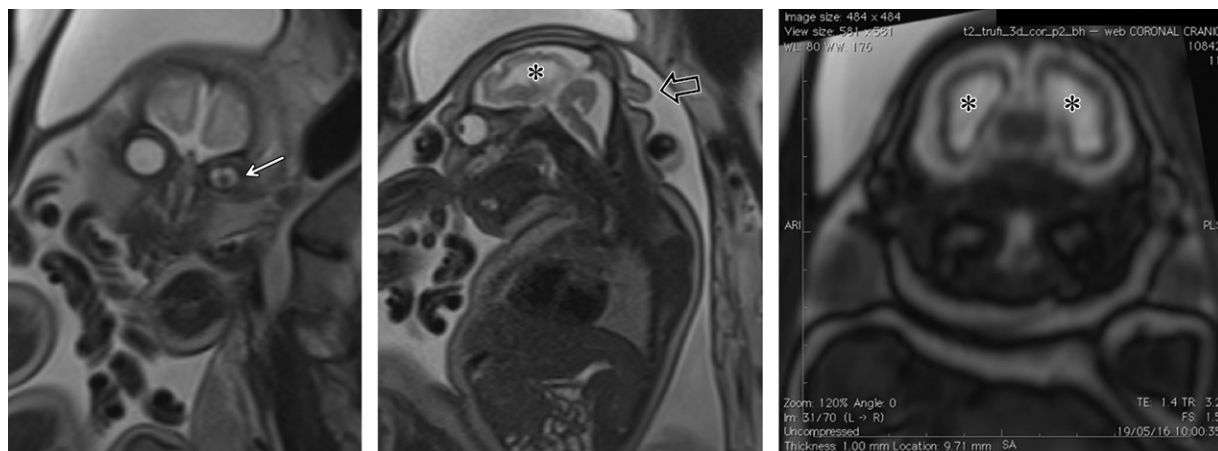
outcomes, and behavioral issues. Microcephaly may occur alone or in combination with other abnormalities. Causes of congenital microcephaly include prenatal viral infections, such as those caused by cytomegalovirus (CMV) and rubella virus, maternal alcohol use, hypertensive disorders, and genetic and environmental factors during pregnancy.

In cases of Zika virus infection, microcephaly is probably only the tip of the iceberg at prenatal imaging, because other unexplained fetal findings are becoming more common. Zika virus infection has been associated with several central nervous system malformations in the fetus, including cortical and/or periventricular calcifications, cerebral atrophy, ventriculomegaly, corpus callosum abnormalities, brainstem hypoplasia, and enlarged cisterna magna. Craniofacial disproportion and redundant scalp skin in the occipital region are typical and easily identifiable findings (19–21).

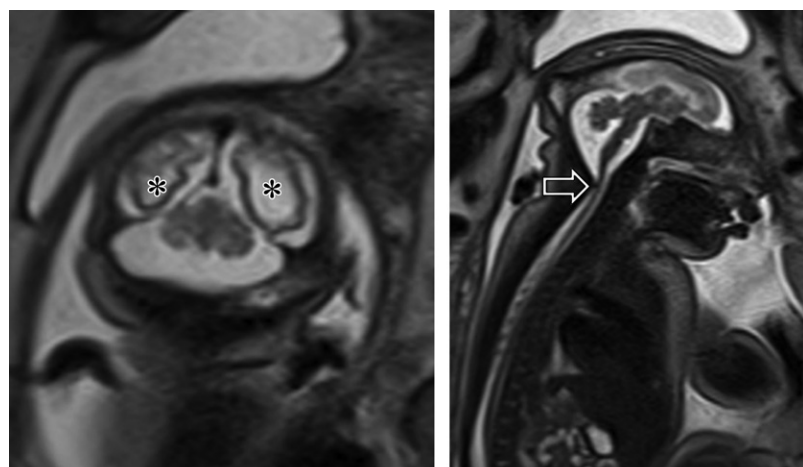
US is able to easily demonstrate some of these abnormalities, including brain calcifications (Fig 2), cerebral atrophy, posterior fossa and corpus callosum abnormalities, and ventriculomegaly, and to depict craniofacial disproportion (Fig 1b) and microphthalmia. Prenatal US and Doppler US have also demonstrated placental insufficiency and/or fetal brain abnormalities (19–21).

### Prenatal MR Imaging

Fetal MR imaging improves the identification of brain malformations such as cerebral atrophy, ventriculomegaly (Fig 3), and microphthalmia (Fig 4)



**Figure 4.** Unilateral microphthalmia in a 33-week fetus with severe microcephaly caused by Zika virus infection acquired in the first trimester of gestation. (a) Coronal T2-weighted MR image shows unilateral microphthalmia (arrow). (b) Sagittal T2-weighted MR image shows microcephaly with cortical atrophy of the occipital lobes and smoothness of the brain surface associated with ventricular enlargement (\*). Inferior cerebellar hypoplasia with a prominent cisterna magna is also depicted, along with redundant scalp skin in the occipital region (arrow). (c) Coronal T2-weighted MR image shows microcephaly with cortical atrophy of the occipital lobes and smoothness of the brain surface associated with ventricular enlargement (\*).



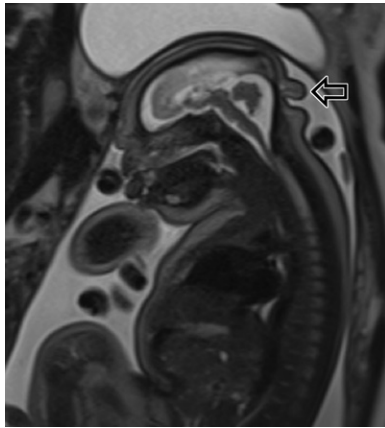
**Figure 5.** Posterior fossa abnormalities and microcephaly in a 37-week fetus with Zika virus infection acquired in the first trimester of gestation of a 33-year-old mother. (a) Coronal T2-weighted MR image shows microcephaly and cortical atrophy, as well as smoothness of the brain surface and ventriculomegaly (\*). (b) Sagittal midline T2-weighted MR image shows a hypoplastic cerebellum and thin brainstem (arrow).

and may be performed when abnormalities such as microcephaly and calcifications are depicted at fetal US, which seems to be more sensitive than MR imaging in the depiction of intraparenchymal calcifications. Fetal MR imaging is better in the evaluation of cortical gyral abnormalities (Fig 3), compared with fetal US. MR imaging is also useful for the demonstration of brainstem and cerebellar hypoplasia, which may also occur (Fig 5). MR imaging may depict malformations of cortical development such as polymicrogyria, agyria (lissencephaly), and pachygyria. A frequent and typical finding at fetal MR imaging is redundant scalp skin in the occipital region (Fig 6), which may also be seen at postnatal imaging or even during physical examination of the newborn. Some of these changes are incompatible with postnatal life, especially in cases of arthrogyrposis (Fig 7).

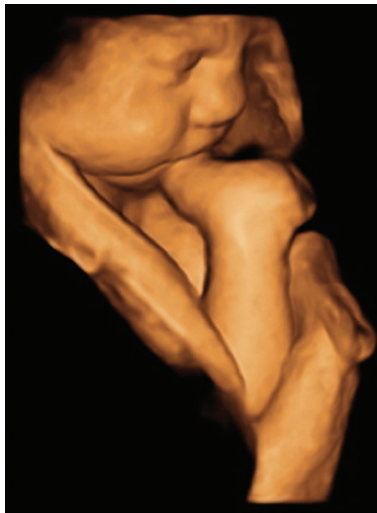### Postnatal Transfontanellar US

Transfontanellar US imaging is a major challenge in postnatal imaging of patients with Zika virus infection who have microcephaly. As shown by de Fatima Vasco Aragao et al (21), the anterior fontanelle is closed in 87% of these infants at the first clinical examination. The extensive brain destruction manifested by these patients may lead to a collapse of the upper cranial bones over the occipital area, pushing this area backward and causing the sutures to overlap and the fontanelles to close (22). A small anterior fontanelle with prematurely closed sutures may also be seen in neonates with Zika virus infection. In this circumstance, neonatal US may still be attempted over a small fontanelle.

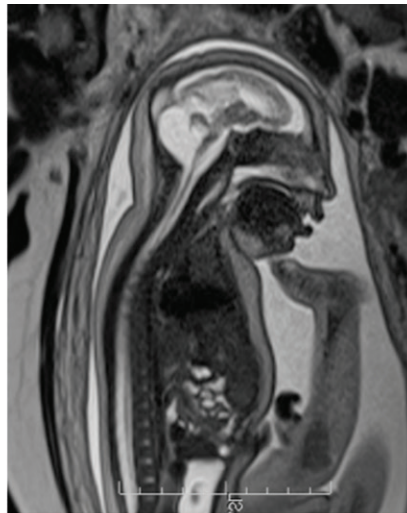
Despite these considerations, transfontanellar US remains, in our opinion, the best first screen-



**Figure 6.** Dysgenesis of the corpus callosum in the same fetus shown in Figure 5 at 37 weeks of gestation. Sagittal T2-weighted midline fetal MR image shows dysgenesis of the corpus callosum. Redundant scalp skin in the occipital region is also depicted (arrow).



**a.**



**b.**

**Figure 7.** Arthrogryposis and microcephaly in a 37-week fetus with congenital Zika virus infection acquired in the first trimester of gestation of a 21-year-old mother. **(a)** Three-dimensional fetal reconstruction MR image shows joint contractures. **(b)** Sagittal T2-weighted MR image shows microcephaly with cortical atrophy, posterior fossa abnormalities with cerebellar hypoplasia, and absence of the vermis. A thin brainstem is also depicted.

ing method to evaluate newborns exposed to the Zika virus, considering that transfontanellar US provides images in real time, is portable, and may be performed at the bedside. This method also has a low cost and does not involve ionizing radiation. The main US findings include *(a)* thinning of the frontoparietal parenchyma with punctiform hyperechoic findings consistent with calcifications and mainly observed on the frontal brain surfaces (Fig 8), and *(b)* dysgenesis of the corpus callosum. Linear or even coarse calcifications may also be observed (17).

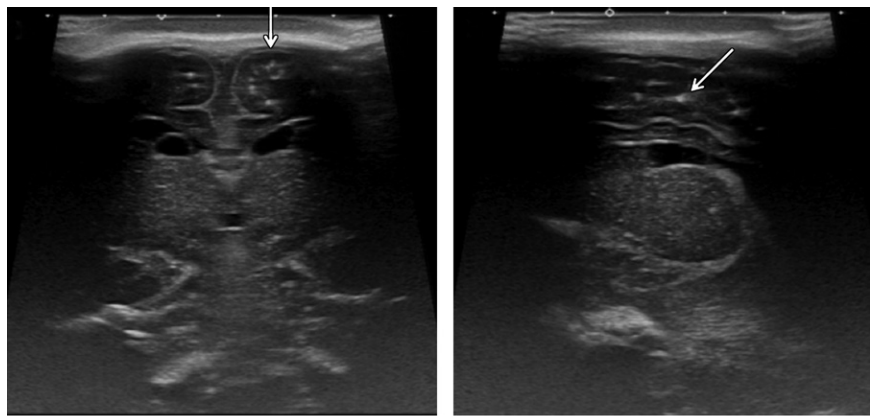
### Postnatal CT

After birth, CT may also be performed to improve the evaluation of microcalcifications. The main imaging findings at postnatal CT are microcephaly, exuberant external occipital protuberance (caused by collapsed bone and constrained intracranial contents), reduced frontonasal angle, and redundant scalp skin. Three-dimensional skull reconstruction allows a better evaluation of these findings and others, such as a small anterior fontanelle with premature closure of cranial sutures, and im-

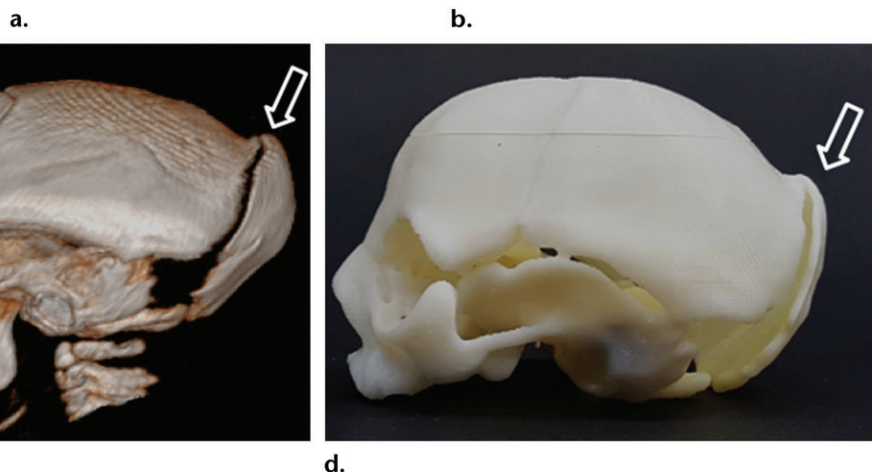
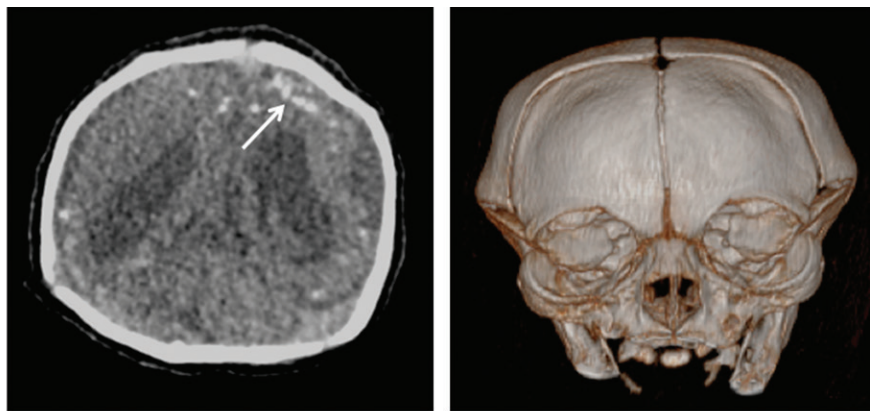
proves the parents' understanding of the disease. Data from the CT examination may also be used to produce a virtual 3D physical model that can be printed, for example, by using thermoplastic acrylonitrile butadiene styrene (Stratasys uPrint; Stratasys, Eden Prairie, Minn) (Fig 9) (17,23).

Brain calcifications have been described in children with congenital Zika virus infection, specifically in the junction between the cortex and the subcortical white matter (Figs 10, 11), although calcifications in the basal ganglia and thalamus may also be identified (21,24). Brain calcifications may demonstrate punctiform, linear, or coarse patterns. Decreased brain volume and diffuse cortical atrophy may also be observed and are characterized by diffuse cortical thinning, enlarged supratentorial subarachnoid space, widely open sylvian fissures, and ventriculomegaly. Although MR imaging is more sensitive than CT in depicting cortical abnormalities occurring in the late stages of cortical development, such as those of neural migration and organization, CT may also be helpful in this regard. A simplified gyral pattern at CT may be suggestive of these





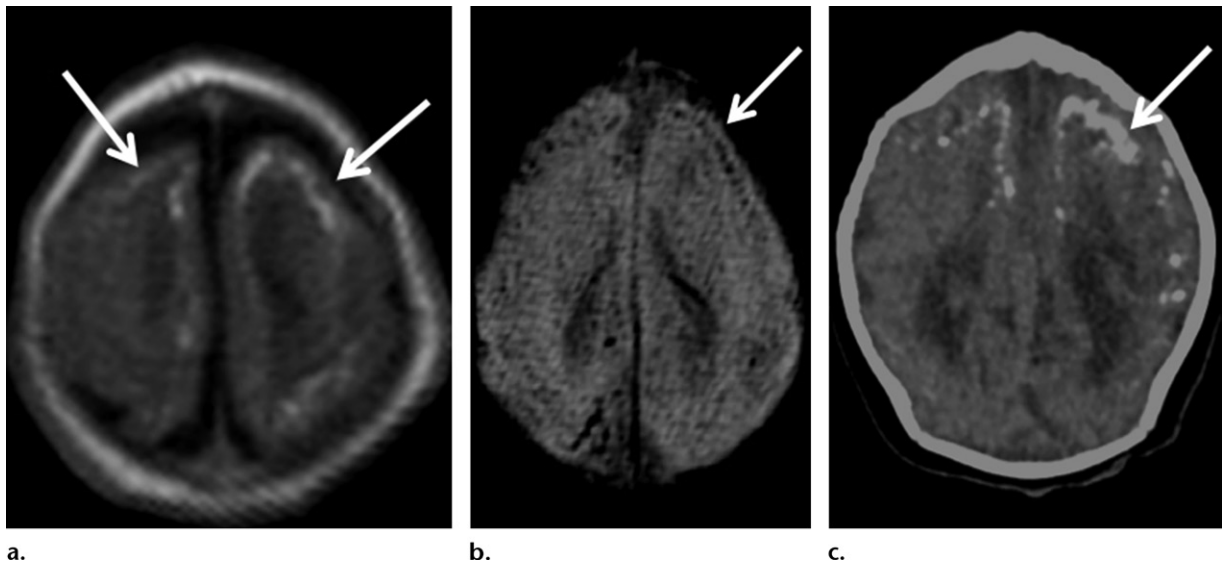
**Figure 8.** Calcifications in a 1-month-old male infant born to a mother infected with the Zika virus during pregnancy. (a) Coronal transfontanelar US image obtained with a high-frequency linear probe shows subcortical punctiform calcifications (arrow). (b) Parasagittal transfontanelar US image shows subcortical and periventricular calcifications (arrow).



**Figure 9.** Microcephaly in a 10-day-old female newborn with congenital Zika virus infection and skull abnormalities. (a) Axial CT image shows subcortical calcifications (arrow) and ventriculomegaly, mainly on the posterior horn of the lateral ventricles. (b) Three-dimensional CT reconstruction image shows microcephaly, along with a small fontanelle and overlapping coronal sutures, which are almost closed. (c, d) Images of virtual (c) and printed (d) 3D CT models show the occipital bone protuberance (arrow), a consequence of the constrained intracranial contents, leading to a collapse of the parietal bones and, consequently, occipital bone protuberance.

abnormalities, which we have observed to occur more frequently in the frontal lobes. However, prospective studies are still needed to establish this concept. The spectrum of abnormalities of

the corpus callosum varies from thinning and dysgenesis or hypoplasia to agenesis. Other findings include an enlarged cisterna magna and hypoplasia of the cerebellum (one or both hemi-



**Figure 10.** Calcifications in a 25-day-old male newborn whose mother was infected with the Zika virus at the 15th week of gestation. (a) Axial T1-weighted MR image shows multiple hyperintense foci (arrows) in the cortical-subcortical junction of the frontoparietal lobes. (b) Axial susceptibility-weighted MR image shows markedly hypointense foci (arrow) in the cortical-subcortical junction of the frontoparietal lobes. (c) Axial CT image shows numerous calcifications (arrow) in the cortical-subcortical junction of the frontoparietal lobes, corresponding to the foci depicted on a and b. Note that in our center, the MR imaging examinations are performed when the infants are sleeping after feeding, and with the use of MR pulse sequences that reduce motion artifacts.

spheres) and brainstem. Thinning of the pons and spinal cord is often observed (21,24,25).

### Postnatal MR Imaging

MR imaging is a well-established modality to identify neurologic disorders in infants born to women infected with the Zika virus. This modality allows a better analysis of the brain parenchyma and identification of congenital malformations and abnormalities.

Although MR imaging has major advantages, this modality is also associated with some drawbacks. For example, MR imaging of infants born to women infected with the Zika virus is challenging. The total imaging time and the fact that the child must remain still for the duration of the examination are also limiting factors. Modern models of MR imaging equipment are currently available with advanced software programs and MR pulse sequences that have dramatically reduced sensitivity to movement during imaging. Pulse sequences used with these models demonstrate fewer motion artifacts and improve the MR imaging evaluation of noncooperative patients, minimizing the need for sedation. Because of the severe neurologic deficits in this particular patient population, we advise against general anesthesia. In our center, the MR imaging examinations are performed when the infants are sleeping after feeding, and with the use of MR pulse sequences that reduce motion artifacts.

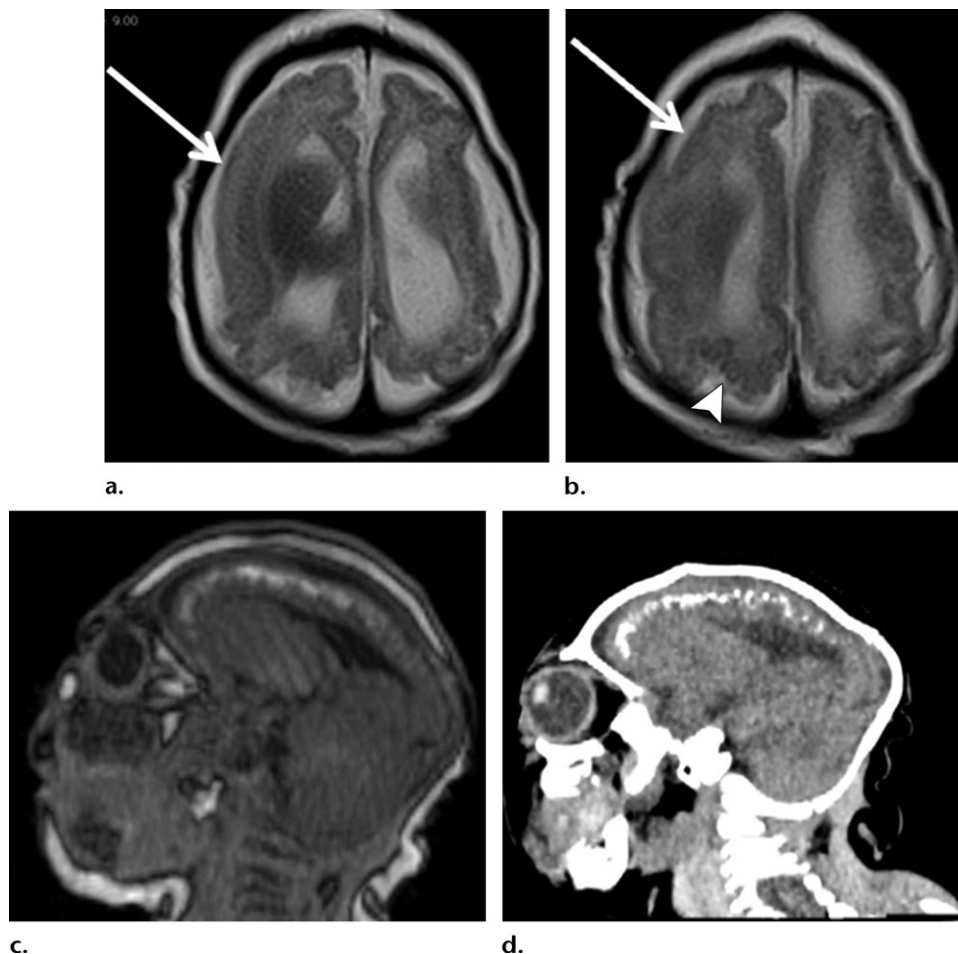
Other disadvantages of MR imaging evaluation are the high cost of the method and the unavail-

ability of the equipment in most public hospitals in Brazil, factors that restrict the access to this modality for most of the population, especially in poor areas. When MR imaging is performed, a detailed knowledge of neuroimaging findings related to congenital Zika virus infection may be crucial to guide neuroradiologists in accurately establishing the diagnosis of this condition. Investigators have described several imaging findings of brain anomalies in addition to microcephaly, which suggests that these findings may follow a pattern of abnormalities that could be suggestive of Zika virus infection.

Distinct imaging modalities may be used to better evaluate the different brain abnormalities associated with congenital Zika virus infection. Although skull deformities are better evaluated with CT, MR imaging can also be used to analyze them. These abnormalities seem to be secondary to a loss of brain parenchymal volume caused by extensive brain damage, which results in a collapse of the frontal and parietal bones, rendering a flattened appearance associated with scalp protrusion and redundant skin in the occipital region, as previously described (26).

As extensively described, calcification is a common finding in congenital Zika virus infection and is easily identified with MR imaging. These calcifications are hypointense with susceptibility-weighted MR imaging sequences and are frequently hyperintense at T1-weighted MR imaging (21,25,26) (Figs 10, 11). The cortical-subcortical junction location of the calcifications





**Figure 11.** Imaging findings in a 1-month-old female infant with congenital Zika virus infection acquired in the first trimester of gestation. (a) Axial T2-weighted MR image shows an area of pachygyria in the frontoparietal right lobes (arrow). (b) Axial T2-weighted MR image shows an area of pachygyria in the right frontoparietal lobes (arrow). Polymicrogyria is also noted in the right posterior parieto-occipital lobes (arrowhead). (c) Sagittal T1-weighted MR image shows thinning of the cerebral parenchyma, with a decreased number of sulci and gyri in the frontoparietal region and multiple subcortical hyperintense foci. (d) Sagittal CT image shows numerous calcifications in the same subcortical areas as the subcortical hyperintense foci on c. Note that in our center, the MR imaging examinations are performed when the infants are sleeping after feeding, and with the use of MR pulse sequences that reduce motion artifacts.

in congenital Zika virus infection may be useful in differentiating them from the periventricular calcifications seen in CMV infection. The calcifications in congenital Zika virus infection have a cortical or mainly subcortical distribution and have been a recurring finding in all of our cases of microcephaly associated with prenatal Zika virus infection. However, some investigators have demonstrated that Zika virus–infected infants may also manifest calcifications in the periventricular regions (27) and brainstem (26). The Table summarizes the differential diagnosis of brain abnormalities that can occur in congenital infections: CMV, Zika virus, and toxoplasmosis.

Malformations of cortical development and sulcation are common imaging findings in Zika virus–infected children and may be better assessed with MR imaging (24). Some investigators have described a simplified pattern of cortical

sulci and gyri and normal cortical thickness, associated with areas of polymicrogyria and/or pachygyria (Fig 11) with a thick cortex (24,25). Although these findings are predominantly observed in the frontal lobes (21), they may also be seen in other lobes.

Delayed myelination and dysmyelination are observed in some cases, associated with secondary thinning of the corpus callosum, which may be depicted with MR imaging (21,26).

The radiologist must be aware that in addition to congenital infections, there are also some heritable disorders, including cystic leukoencephalopathy without megacephaly, Aicardi-Goutières syndrome, type 1 interferonopathies, *RNASET2*-related leukodystrophy, and pseudo-TORCH syndrome (Baraitser-Reardon syndrome), that may manifest with findings similar to those of congenital Zika virus infection.

### Differential Diagnosis of Brain Abnormalities Observed in Congenital Infections: CMV, Zika Virus, and Toxoplasmosis

Type of Abnormality	CMV	Zika Virus	Toxoplasmosis
Calcification	Periventricular or cortical distribution Punctate or thick pattern	Cortical-subcortical junction, bandlike distribution Punctate, dystrophic, linear, or coarse pattern	Cortical distribution Nodular pattern
Microcephaly	May be seen	May be seen; exuberant external occipital protuberance and redundant scalp skin in the occipital region	Less common
Neuronal migration disorder	May be seen	May be seen	Not seen
Ventriculomegaly	Mild to moderate	Mild to moderate	Moderate to severe
Cerebellum	Hypoplasia may be present	Not affected in most cases; hypoplasia may be present	Hypoplasia may be present
Face	Normal	Reduced frontonasal angle	Normal

Microcephaly, brain calcifications, and agyria (lissencephaly), including a thin cerebral cortex, extremely diminished volume of white matter, delayed myelination, small cerebellum, and enlarged lateral ventricles, have been described in these syndromes (21,28).

### Conclusion

In intrauterine Zika virus infection with central nervous system involvement, the main findings include microcephaly, ventriculomegaly, and multifocal calcifications in the cortex and subcortical white matter, as well as cortical atrophy associated with a reduced frontonasal angle, occipital protuberance, and redundant scalp skin in the occipital region. Perinatal MR imaging and CT enable the diagnosis of pachygyria, corpus callosum dysgenesis, and a small anterior fontanelle with premature closure of cranial sutures. Radiologists must recognize these findings to identify suspected cases of Zika virus infection.

### References

- Enfissi A, Codrington J, Roosblad J, Kazanji M, Rousset D. Zika virus genome from the Americas. *Lancet* 2016;387(10015):227–228.
- Ming GL, Tang H, Song H. Advances in Zika virus research: stem cell models, challenges, and opportunities. *Cell Stem Cell* 2016;19(6):690–702.
- Abushouk AI, Negida A, Ahmed H. An updated review of Zika virus. *J Clin Virol* 2016;84:53–58.
- Dick GW, Kitchen SF, Haddow AJ. Zika virus. I. Isolations and serological specificity. *Trans R Soc Trop Med Hyg* 1952;46(5):509–520.
- Duffy MR, Chen TH, Hancock WT, et al. Zika virus outbreak on Yap Island, Federated States of Micronesia. *N Engl J Med* 2009;360(24):2536–2543.
- Cao-Lormeau VM, Blake A, Mons S, et al. Guillain-Barré syndrome outbreak associated with Zika virus infection in French Polynesia: a case-control study. *Lancet* 2016;387(10027):1531–1539.
- Cao-Lormeau VM, Roche C, Teissier A, et al. Zika virus, French Polynesia, South Pacific, 2013 [letter]. *Emerg Infect Dis* 2014;20(6):1085–1086.
- Ioos S, Mallet HP, Leparç Goffart I, Gauthier V, Cardoso T, Herida M. Current Zika virus epidemiology and recent epidemics. *Med Mal Infect* 2014;44(7):302–307.
- Dupont-Rouzeyrol M, O'Connor O, Calvez E, et al. Coinfection with Zika and dengue viruses in 2 patients, New Caledonia, 2014. *Emerg Infect Dis* 2015;21(2):381–382.
- Cauchemez S, Besnard M, Bompard P, et al. Association between Zika virus and microcephaly in French Polynesia, 2013–15: a retrospective study. *Lancet* 2016;387(10033):2125–2132.
- Anderson KB, Thomas SJ, Endy TP. The emergence of Zika virus: a narrative review. *Ann Intern Med* 2016;165(3):175–183.
- De Carvalho NS, De Carvalho BF, Fugaça CA, Dóris B, Biscaia ES. Zika virus infection during pregnancy and microcephaly occurrence: a review of literature and Brazilian data. *Braz J Infect Dis* 2016;20(3):282–289.
- Schuler-Faccini L, Ribeiro EM, Feitosa IM, et al. Possible association between Zika virus infection and microcephaly: Brazil, 2015. *MMWR Morb Mortal Wkly Rep* 2016;65(3):59–62.
- Gulland A. Zika virus is a global public health emergency, declares WHO [news]. *BMJ* 2016;352:i657. doi:10.1136/bmj.i657. Published online February 2, 2016.
- Papageorgiou AT, Thilaganathan B, Bilardo CM, et al. ISUOG interim guidance on ultrasound for Zika virus infection in pregnancy: information for healthcare professionals. *Ultrasound Obstet Gynecol* 2016;47(4):530–532.
- Ministério da Saúde (Brazil). Protocolo de vigilância e resposta à ocorrência de microcefalia e/ou alterações do sistema nervoso central (SNC). <http://combateaes.saude.gov.br/images/sala-de-situacao/Microcefalia-Protocolo-de-vigilancia-e-resposta-10mar2016-18h.pdf>. Published January 22, 2016. Accessed August 12, 2017.
- Werner H, Sodré D, Hygino C, et al. First-trimester intrauterine Zika virus infection and brain pathology: prenatal and postnatal neuroimaging findings. *Prenat Diagn* 2016;36(8):785–789.
- Araujo Júnior E, Martins Santana EF, Martins WP, et al. Reference charts of fetal biometric parameters in 31,476 Brazilian singleton pregnancies. *J Ultrasound Med* 2014;33(7):1185–1191.
- Adibi JJ, Marques ET Jr, Cartus A, Beigi RH. Teratogenic effects of the Zika virus and the role of the placenta. *Lancet* 2016;387(10027):1587–1590.
- Oliveira Melo AS, Malinger G, Ximenes R, Szejnfeld PO, Alves Sampaio S, Bispo de Filippis AM. Zika virus intrauterine infection causes fetal brain abnormality and microcephaly: tip of the iceberg? *Ultrasound Obstet Gynecol* 2016;47(1):6–7.

21. de Fatima Vasco Aragao M, van der Linden V, Brainer-Lima AM, et al. Clinical features and neuroimaging (CT and MRI) findings in presumed Zika virus related congenital infection and microcephaly: retrospective case series study. *BMJ* 2016;353:i1901. <https://www.bmj.com/content/bmj/353/bmj.i1901.full.pdf>. Published online April 13, 2016.
22. Dain Gandelman Horovitz D, da Silva Pone MV, Moura Pone S, Dias Saad Salles TR, Bastos Boechat MC. Cranial bone collapse in microcephalic infants prenatally exposed to Zika virus infection. *Neurology* 2016;87(1):118–119.
23. Werner H, Fazecas T, Guedes B, et al. Intrauterine Zika virus infection and microcephaly: correlation of perinatal imaging and three-dimensional virtual physical models. *Ultrasound Obstet Gynecol* 2016;47(5):657–660.
24. Hazin AN, Poretti A, Turchi Martelli CM, et al. Computed tomographic findings in microcephaly associated with Zika virus [letter]. *N Engl J Med* 2016;374(22):2193–2195.
25. Soares de Oliveira-Szejnfeld P, Levine D, Melo AS, et al. Congenital brain abnormalities and Zika virus: what the radiologist can expect to see prenatally and postnatally. *Radiology* 2016;281(1):203–218.
26. Moore CA, Staples JE, Dobyns WB, et al. Characterizing the pattern of anomalies in congenital Zika syndrome for pediatric clinicians. *JAMA Pediatr* 2017;171(3):288–295.
27. Cavalheiro S, Lopez A, Serra S, et al. Microcephaly and Zika virus: neonatal neuroradiological aspects. *Childs Nerv Syst* 2016;32(6):1057–1060.
28. Vivarelli R, Grosso S, Cioni M, et al. Pseudo-TORCH syndrome or Baraitser-Reardon syndrome: diagnostic criteria. *Brain Dev* 2001;23(1):18–23.

This journal-based SA-CME activity has been approved for **AMA PRA Category 1 Credit™**. See [www.rsna.org/education/search/RG](http://www.rsna.org/education/search/RG).

## Invited Commentary on “Central Nervous System Effects of Intrauterine Zika Virus Infection”

### From:

Deborah Levine, MD

Department of Radiology, Beth Israel Deaconess Medical Center

Boston, Massachusetts

In this issue of *RadioGraphics*, Ribeiro et al (1) present a spectrum of imaging findings in congenital Zika virus infection, as seen in the third trimester with two-dimensional (2D) and 3D US and fetal MR imaging and in the postnatal period to the age of 1 month with head US, CT (with 3D reconstruction), and MR imaging. This topic is timely, because the sequelae of congenital Zika virus infection, including the associated imaging findings, are important for the imaging community (ie, radiology, obstetrics/gynecology, and neurology) to recognize. Although this topic is clearly important in areas where the Zika virus is endemic—as Ribeiro et al mention (1), such as their country of Brazil—the topic is also important in regions in which the mosquitoes carrying the virus are not endemic, because travelers can bring the infection to other countries around the world.

Although the comments in the article by Ribeiro et al (1) that mention the increasing number of fetuses with microcephaly are true in absolute numbers, it should be understood that in most parts of Brazil, the actual infection rates in 2017 are much less than those seen in the period of 2015–2016. It is reassuring that the large surge of congenital infections that could have potentially occurred in 2017 as Zika continues to spread has not been found. As of August 9, 2017, in the United States, there have been 5413 symptomatic Zika disease cases reported—5140

in travelers returning from affected areas, 224 through presumed local mosquito-borne transmission, 47 through sexual transmission, one from laboratory transmission, and one from an unknown route—but of the 136 cases from 2017, none of the cases were from local mosquito transmission (2). The World Health Organization website update from March 2017 states, “ZIKV continues to spread geographically to areas where competent vectors are present. Although a decline in cases of Zika virus infection has been reported in some countries, or in some parts of countries, vigilance needs to remain high” (3).

The reasons behind this relative lack of spread are likely linked to those that caused the epidemic. Although initially the population had not been exposed to Zika virus infection, now in regions in which the *Aedes* mosquito and Zika virus infection are endemic, there is likely a herd immunity. It is likely that secondary infection with the Zika virus does not carry the same grim prognosis as primary infection; however, prior infection with other flaviviruses (such as the dengue virus or the chikungunya virus) may augment Zika virus infection in those without primary immunity to the Zika virus (4). Thus, at least one aspect of the high congenital malformation rate seen in the Paraíba region of Brazil in 2015–2016 may be the relatively “Zika-naïve” population, such that all woman who contracted



the disease likely had a primary Zika virus infection, in the setting of the relatively high rates of prior infection with the dengue virus and/or the chikungunya virus, which could augment the response to Zika virus infection. These differences in the severity of Zika virus infection noted in the United States, compared with Brazil, may be due to many factors, including lower rates of prior *Flavivirus* infection, higher socioeconomic status, different nutritional status, and decreased viral load, among others.

The article by Ribeiro et al (1) effectively covers many aspects of Zika virus infection. Ribeiro et al (1) start with some history of the virus, including the spread from Uganda to Yap Island, to Brazil, and then rapidly to more than 30 countries. Ribeiro et al (1) also mention many of the difficulties in establishing the diagnosis of Zika virus infection by using IgM, pointing out that IgM antibodies against the dengue virus and the chikungunya virus can cross-react with those of the Zika virus, leading to a false-positive diagnosis. In addition, false-negative diagnoses may occur if by the time when a pregnant woman presents for diagnosis or after her baby is born, the window for detection of IgM has passed. Currently, diagnosis in the United States is confirmed with the plaque reduction neutralization test, which measures virus-specific neutralizing antibodies to the Zika virus. Because of cross-reactivity with other flaviviruses, such as the dengue virus, the plaque reduction neutralization test is not used in Puerto Rico. The type of testing and the fluid or tissue used depend on the interval between the presumed exposure (rash) and testing (5).

Timing is of utmost importance in assessing the Zika virus-infected pregnancy, not just for the aforementioned serologic tests but also for the time of exposure of the pregnancy and the time to the imaging examination(s). First trimester infection proffers the worst prognosis for the fetus because of the affinity of the Zika virus for neural progenitor cells. Thus, with first trimester infection, fetal death may occur, and severe congenital brain (including ocular) abnormalities may be seen. Although initial reports emphasized microcephaly, a large spectrum of abnormalities can be seen in Zika virus infection (6–8). However, it can take 9–10 weeks after a first trimester infection for abnormalities to be depicted sonographically (9). Although the most appropriate algorithm for screening potentially infected pregnancies is still not established, the Centers for Disease Control and Prevention recommend serial US evaluations every 3–4 weeks for detection of microcephaly and intracranial calcifications (10).

Ribeiro et al (1) state that the calcifications “have a cortical or mainly subcortical distribution.” I would like to highlight this distinction. In most congenital infections that are seen in utero (eg, CMV), the calcifications, if present, are punctate and are seen in the periventricular and cortical regions. At times, more linear lenticulostriate calcifications (lenticulostriate vasculopathy) are depicted. In Zika virus infection, the calcifications have a different appearance, one not classic for other infections. The calcifications, rather than being cortical, are predominantly subcortical. Rather than being punctate, the calcifications are coarse. The heavy calcifications frequently depicted in the fetuses with microcephaly are an indication of the profound amount of cell death that occurs in migrating neurons. The previously described lenticulostriate vasculopathy can also be present.

The microcephaly seen with the Zika virus is also different from the microcephaly seen in association with other congenital infections. Of utmost importance is the relatively high frequency of microcephaly that has been described in association with first trimester infection (although studies are hampered by reporting bias that emphasizes abnormal outcomes). Second, microcephaly is not just the small head size, but a classic deformity of the skull. Although a sloping forehead can be seen in many brain malformations associated with frontal lobe hypoplasia, the skull in many instances of Zika virus infection has a collapsed appearance, with overriding sutures and prominence of the occipital bone. It has been hypothesized that the skull collapses after ventriculomegaly decompresses and/or that the bones keep growing while the brain does not. The redundant skin folds associated with congenital Zika virus infection are not typically seen with other causes of microcephaly, and these skin folds are believed to be due to continued growth of the skin after collapse of the skull. Despite the small head size, the extra-axial cerebrospinal fluid spaces can also be enlarged, thus leaving the brain parenchymal volume even less than what would be expected for the head size. Not depicted in the series of cases illustrated by Ribeiro et al (1) are the less common Zika virus infections with hydrocephalus, in which the head size may be normal if the skull has not collapsed (7). This combination of findings can be due to aqueductal stenosis in association with early Zika virus infection (11).

As with most brain abnormalities, if the fetus is in cephalic presentation, endovaginal US rather than transabdominal US can better depict intracranial anatomy. As mentioned previously, findings that are commonly seen sonographically

include microcephaly, ventriculomegaly, micrencephaly (small brain size) with accentuation of the extra-axial cerebrospinal fluid spaces despite small head size, and cerebral calcifications, particularly at the junction of the gray matter and white matter. Many other cerebral abnormalities can occur, as illustrated in the article by Ribeiro et al (1), including dysgenesis of the corpus callosum, cortical migration abnormalities, a collapsed appearance of the skull with skin folds caused by the small head size relative to the skin covering, and posterior fossa abnormalities. However, at times, the overlapping sutures in fetuses with Zika virus infection make elucidation of brain structure difficult with either transabdominal or endovaginal US. It also is important to assess the fetal limbs sonographically, because abnormal fetal posturing (arthrogryposis) may be present because of motor neuron damage.

In those studies in which US imaging shows microcephaly and calcifications, fetal MR imaging provides additional information beyond that of US. Findings better depicted with MR imaging include corpus callosum abnormalities, brainstem findings, cortical gyral abnormalities, and delays in myelination. The small brainstem and spinal cord sometimes seen in association with Zika virus infection have been shown to be due in part to motor neuron loss (11). However, it should be realized that the fetal images in the review article by Ribeiro et al (1) are all from the third trimester, long after the initial damage to the developing brain has occurred. Although the images in this review article, and in so many others, with regard to congenital Zika virus infection are striking, we need to consider the incremental value of the additional fetal imaging.

The use of MR imaging in pregnancy continues to be a hotly debated topic. Should MR imaging be performed in all fetuses in whom microcephaly has been diagnosed? If severe abnormalities are documented at US, is there an incremental benefit to acquiring additional findings with fetal MR imaging? If Zika virus infection is already known, will demonstration of these additional findings change patient management? A cost-benefit analysis is difficult to perform for pregnant patients exposed to Zika virus infection, because the timing of infection, US measurements, and US findings (and the confidence of the sonologist in the diagnosis of brain malformations) all play into the perceived benefit of MR imaging.

Similarly, questions can be asked about imaging beyond head US in the neonate. If microcephaly and calcifications are seen at US, does a CT examination need to be performed? If postnatal CT shows the intracranial calcifica-

tions in a newborn with microcephaly, are the 3D image reconstruction and 3D printing of the deformed skull going to change management? Clearly, we need a better understanding of the natural history of the disease process, and postnatal follow-up should include imaging to aid in that assessment. However, it is unlikely that additional imaging is needed in those neonates already known to have severely abnormal brains (unless clinical decompensation occurs). Thus, further research in postnatal imaging will likely be focused on those who were exposed in utero without known central nervous system findings, and those with a delayed manifestation of the disease (for example, with developmental delays or hearing or visual loss). Although most of the severe cases of microcephaly can be traced back to first trimester infection, it is unclear what the outcome will be with infection in the second trimester or third trimester, or even with neonatal infection. Longer postnatal follow-up is needed, because with other congenital infections such as CMV and toxoplasmosis, infection with associated hearing loss and cognitive deficits may not be recognized until later in life. Because migrational abnormalities and myelination abnormalities may not be recognized until after birth, there is still the question of how (and how often) potentially infected infants should be imaged after birth.

Abnormalities in the white matter, particularly in the temporal region, are known to be associated with developmental delays in infections such as CMV (12). In their review, Ribeiro et al (1) illustrate abnormal white matter in a newborn at MR imaging, with increased signal intensity on T2-weighted MR images and decreased signal intensity on diffusion-weighted MR images. It is likely that the findings of abnormal signal intensity shown by Ribeiro et al (1) will be associated with poor outcome; however, follow-up of these children is needed to assess for developmental issues, hearing deficits, or visual deficits that may not be diagnosed at birth.

Research about the prenatal imaging appearance of Zika virus infection has been hampered by limitations of serologic tests, inclusion bias in the studies that are biased toward those with the worst outcome (thus garnering clinical attention), and limitations of inadequate follow-up after diagnosis. As has been stated in multiple prior publications about congenital Zika virus infection (7,12,13), it is the infections that we know about that are being described in the imaging literature. There is likely a cohort of neonates without microcephaly at birth who were exposed to the Zika virus in pregnancy or early postnatal life, and the perinatal effect of this infection of

the brain is still unknown. Thus, work on appropriate postnatal interventions is needed, and algorithms for imaging surveillance are still being developed. Similarly, vaccines and the treatment of early infection in pregnant women in the hope of decreasing vertical transmission are important avenues to pursue to better contain the spread of this disease and the serious sequelae of congenital Zika virus infection. Finally, early intervention, with a potential for optimization of outcome in neonates after congenital infection, is also being studied. It behooves the imaging community to understand the unique features of Zika virus infection, so that when these features are recognized, prompt laboratory diagnosis and follow-up can be initiated.

**Disclosures of Conflicts of Interest.—D.L.** *Activities related to the present article:* disclosed no relevant relationships. *Activities not related to the present article:* expert witness for various lawsuits; royalties from Elsevier. *Other activities:* disclosed no relevant relationships.

## References

- Ribeiro BG, Werner H, Lopes FPPL, et al. Central nervous system effects of intrauterine Zika virus infection: a pictorial review. *RadioGraphics* 2017;37(6):1840–1850.
- Centers for Disease Control and Prevention. Zika cases in the United States: cumulative Zika virus disease case counts in the United States, 2015–2017. Centers for Disease Control and Prevention website. <https://www.cdc.gov/zika/reporting/case-counts.html>. Updated August 9, 2017. Accessed August 11, 2017.
- World Health Organization. Emergencies: Zika situation report. World Health Organization website. <http://www.who.int/emergencies/zika-virus/situation-report/10-march-2017/en/>. Published March 10, 2017. Accessed June 18, 2017.
- Bardina SV, Bunduc P, Tripathi S, et al. Enhancement of Zika virus pathogenesis by preexisting antinflavivirus immunity. *Science* 2017;356(6334):175–180.
- Centers for Disease Control and Prevention. Guidance for US laboratories testing for Zika virus infection: July 24, 2017. Centers for Disease Control and Prevention website. <https://www.cdc.gov/zika/laboratories/lab-guidance.html>. Updated July 24, 2017. Accessed August 11, 2017.
- Oliveira Melo AS, Malinger G, Ximenes R, Szejnfeld PO, Alves Sampaio S, Bispo de Filippis AM. Zika virus intrauterine infection causes fetal brain abnormality and microcephaly: tip of the iceberg? *Ultrasound Obstet Gynecol* 2016;47(1):6–7.
- Soares de Oliveira-Szejnfeld P, Levine D, Melo AS, et al. Congenital brain abnormalities and Zika virus: what the radiologist can expect to see prenatally and postnatally. *Radiology* 2016;281(1):203–218.
- de Fatima Vasco Aragao M, van der Linden V, Brainer-Lima AM, et al. Clinical features and neuroimaging (CT and MRI) findings in presumed Zika virus related congenital infection and microcephaly: retrospective case series study. *BMJ* 2016;353:i1901. <https://www.bmj.com/content/bmj/353/bmj.i1901.full.pdf>. Published online April 13, 2016.
- Schaub B, Vouga M, Najioullah F, et al. Analysis of blood from Zika virus-infected fetuses: a prospective case series. *Lancet Infect Dis* 2017;17(5):520–527.
- Centers for Disease Control and Prevention. Prenatal care: clinical management of pregnant women with possible Zika virus infection. Centers for Disease Control and Prevention website. <https://www.cdc.gov/zika/hc-providers/pregnant-women/prenatal-care.html>. Updated July 23, 2017. Accessed August 11, 2017.
- Chimelli L, Melo ASO, Avvad-Portari E, et al. The spectrum of neuropathological changes associated with congenital Zika virus infection. *Acta Neuropathol (Berl)* 2017;133(6):983–999.
- Cannie MM, Devlieger R, Leyder M, et al. Congenital cytomegalovirus infection: contribution and best timing of prenatal MR imaging. *Eur Radiol* 2016;26(10):3760–3769.
- van der Linden V, Pessoa A, Dobyms W, et al. Description of 13 infants born during October 2015–January 2016 with congenital Zika virus infection without microcephaly at birth: Brazil. *MMWR Morb Mortal Wkly Rep* 2016;65(47):1343–1348.