

# Participation of cytokines in the necrotic-inflammatory lesions in the heart and skeletal muscles of *Calomys callosus* infected with *Trypanosoma cruzi*

Isis F Magalhães-Santos, Sonia G Andrade/+

Laboratório de Chagas Experimental, Auto-imunidade e Imunologia Celular, Centro de Pesquisas Gonçalo Moniz-Fiocruz, Rua Valdemar Falcão 121, 40295-001 Salvador, BA, Brasil

*Calomys callosus*, a sylvatic reservoir of *Trypanosoma cruzi*, when infected with the Colombian strain (Biodeme Type III, *T. cruzi* I) develops necrotic-inflammatory lesions and intense early fibrogenesis in the heart and skeletal muscles, that spontaneously regress. Participation of pro-inflammatory and pro-fibrogenic cytokines, such as tumor necrosis factor-alpha (TNF- $\alpha$ ), gamma interferon (IFN- $\gamma$ ), and tumor growth factor-beta (TGF- $\beta$ ), in the pathogenesis of the lesions is herein studied. Eighty *C. callosus* weighing 20 to 30 g were used. Seventy of them were inoculated with the Colombian strain ( $10^5$  blood forms) and 10 were maintained as intact non-infected controls. After infection, *C. callosus* were sacrificed at different time-points from 15 to 70 days. The heart and skeletal muscle were processed for histopathology and cryopreserved for immunohistochemistry. Early necrotic lesions of parasitized skeletal muscle and myocardium with intense inflammatory lesions were present. Search for the *in situ* presence of TNF- $\alpha$  and IFN- $\gamma$ , was performed using rat-IgG anti-mouse antibodies against these cytokines. For the *in situ* search of TGF- $\beta$ , rabbit IgG anti-mouse antibodies were used. Immunolabeling of the cytokines in tissues of infected *C. callosus* was successful. The cytokines TNF- $\alpha$ , IFN- $\gamma$ , and TGF- $\beta$  were detected in the cytoplasm of macrophages and in the necrotic material from 15 to 45 days post-infection, decreasing their intensity until complete disappearance by the 65th day, which correlated with subsiding histopathological lesions. These findings suggest the participation of these cytokines in the control of parasite multiplication, in the development of an early fibrogenesis and in the regression of fibrotic-inflammatory lesions observed in *C. callosus*.

Key words: *Trypanosoma cruzi* - *Calomys callosus* - cytokines - tumor necrosis factor-alpha - gamma interferon - tumor growth factor-beta

The *Calomys callosus* (Rodentia cricetidae) is a sylvatic vertebrate, natural reservoir of *Trypanosoma cruzi*. Adapted to laboratory studies (Mello 1982) this animal represents a very peculiar experimental model, with the capacity of to control the infection with virulent strains of *T. cruzi* as the Y strain (Mello 1979, Borges et al. 1982, 1992). Interestingly, tissue lesions are precocious with intense inflammatory infiltrates and early fibrogenesis, with a spontaneous regression of inflammation and fibrosis (Andrade et al. 1994, Lenzi et al. 1995, Magalhães-Santos et al. 2002, 2004).

The basic mechanisms involved on the pathogenesis of the lesions and their regression are still unknown. It is probable that pro-inflammatory, fibrogenic, and regulatory cytokines play an important role. Thus, it appears important to investigate their participation in cardiac and skeletal muscles lesions in the host *C. callosus*, for the understanding of the immunological responses.

In the *C. callosus* infection it has been demonstrated that parasite strains, especially those belonging to Biodeme Type III (*T. cruzi* I), as the F strain (Andrade et

al. 1994) and the Colombian strain (Magalhães-Santos et al. 2002) are crucial for the determination of tissue lesions, since they are the most pathogenic. However differently from the mouse, the tissue lesions in *C. callosus* are progressive, going from the acute phase of infection and spontaneously subsiding by the early chronic phase (Magalhães-Santos et al. 2002).

Studies with the murine model have shown that cardiomyocytes when infected with *T. cruzi* can produce marked amounts of cytokines such as gamma interferon (IFN- $\gamma$ ), interleukin 1-beta (IL-1 $\beta$ ), tumor necrosis factor-alpha (TNF- $\alpha$ ), interleukin 10 (IL-10), and tumor growth factor-beta (TGF- $\beta$ ) that can induce or regulate the production of different chemokines that modulate cellular immune response (Teixeira et al. 2002).

In previous investigations Borges et al. (1995) have demonstrated the increase of IFN- $\gamma$  levels in the serum of *C. callosus* acutely infected with a sylvatic strain of *T. cruzi* (M226). In the infection with others strains of *T. cruzi*, the levels of serum IFN- $\gamma$  were high in the acute phase, with positive correlation with H<sub>2</sub>O<sub>2</sub> liberation by peritoneal macrophages and it was associated with the decrease of parasitemia (Borges et al. 1995). The referred authors concluded that during the acute phase of the infection, the *C. callosus* develops a T-cell dependent immune response characterized by the production of IFN- $\gamma$  with regulation of parasitemia to low levels, and controlling tissue parasitism without resulting in host-tissue aggression.

Financial support: Fapesb, process 19.571.049.3383  
Corresponding author. E-mail: sgandrade@cpqgm.fiocruz.br  
Received 1 February 2005  
Accepted 20 July 2005

Several immunological aspects, such as cytokines production in situ remain to be investigated to explain the spontaneous capacity of *C. callosus* to control the infection after significant tissue lesions caused by the presence of *T. cruzi*.

In the present study, the in situ investigation of TNF- $\alpha$ , IFN- $\gamma$ , and TGF- $\beta$  revealed their presence in the necrotic-inflammatory lesions of the myocardium and skeletal muscles. These findings suggest the participation of these cytokines in the intracellular destruction of parasites, with evident control of parasitemia. The presence of necrotic inflammatory lesions, correlate with the high expression of TNF- $\alpha$  and IFN- $\gamma$ . The presence of TGF- $\beta$  coincides with regression of inflammation and degradation of fibrosis. This seems to indicate that these several factors are combined in the evolution of infection in the *C. callosus*.

### MATERIALS AND METHODS

**Experimental animals** - Eighty *C. callosus* raised in the animal facilities of Centro de Pesquisas Gonçalo Moniz-Fiocruz, were used in this study. The experimental animals were approximately 60 day old males, weighing 20-30 g. Their maintenance complied with the guidelines for the human use of laboratory animals.

**Inoculation with *T. cruzi*** - Seventy *C. callosus* were intraperitoneally inoculated with the Colombian strain (Biodeme Type III, *T. cruzi* I). **Inoculum:**  $10^5$  blood forms obtained from infected mice, after washing with PBS, pH 7.2, by centrifugation at 1200 g. Ten non-infected *C. callosus* were used as intact controls. Parasitemia of the infected animals was evaluated by counting trypomastigotes in 50 microscopic fields (400 $\times$ ) in peripheral blood, examined under slide and coverslip, three days/week.

**Histopathology** - Five infected *C. callosus* per point were sacrificed with 15, 20, 25, 30, 35, 40, 45, 50, 55, 60, 65, and 70 days after infection. The heart and thigh-muscle fragments were collected and divided into two parts, one fixed in buffered formalin, pH 7.6 and the other cryopreserved for immunohistochemistry. For histopathology, tissues were embedded in paraffin and 5  $\mu$ m-thick sections of the heart and skeletal muscle were stained with hematoxylin eosin and Picro-Sirius red method for collagen (Junqueira et al. 1979). Normal controls were sacrificed at the end of the experiments and submitted to the same procedures

**Immunohistochemistry** - Fragments of heart and skeletal muscle were immediately embedded in tissue tek (OCT compound Miles Inc. Diagnostic Division, Elkhart, US) frozen in liquid nitrogen and cryopreserved in a freezer at 70°C until use. Sections of 5  $\mu$ m obtained in a cryostat at -10°C placed on slides previously treated with 10% Poly L-Lysin (Sigma, St. Louis, MO, US) fixed in PA acetone were treated with PBS pH 7.4, containing 0.1% saponin (Sigma) and 1% bovin serum albumin (BSA) (Sigma). For blocking non-specific bindings, sections were treated with 10% BSA for 20 min at room temperature. As primary antibodies, the following antibodies were used in three ex-

periments: (1) rat IgG antimouse TNF- $\alpha$  monoclonal antibody (MP6-XT3) (Pharmigen, San Diego, CA, US); (2) rat IgG antimouse IFN- $\gamma$  monoclonal antibody (Sigma); (3) rabbit anti-mouse TGF- $\beta$  purified polyclonal antibody (TGF- $\beta$  1, b 2, b 3, and b 5) (R&D Systems Inc. Minneapolis MN, US - Cod: DK-20-PB). Sections were incubated overnight at 4°C in an humidified chamber, with each antibody diluted in PBS pH 7.4/saponin 0.1%/BSA 1% in the dilution of 1:20 for anti-TNF- $\alpha$  and anti-IFN- $\gamma$ ; 1:50 for anti-TGF- $\beta$ . After washing with PBS and saponin, sections treated with TNF- $\alpha$  or IFN- $\gamma$  were incubated in normal rat serum in the dilution of 1:20 in PBS/BSA (5%) for 20 min, for additional blocking of nonspecific binding. For TGF- $\beta$  the additional blocking was done with normal rabbit serum, diluted 1:20 in PBS/BSA (5%), incubated during 20 min. Inhibition of the endogenous peroxidase was achieved by a 30 min incubation in 0.3% H<sub>2</sub>O<sub>2</sub> at room temperature. The slides were then incubated for 30 min at 37°C in a humidified chamber with the secondary antibody conjugated to peroxidase. For TNF- $\alpha$  and IFN- $\gamma$  detection, a sheep anti-rat IgG antibody conjugated to peroxidase (Boehringer-Mannheim Biochemica, Germany) in the dilution of 1/300 in PBS/BSA/saponin, was used. For TGF- $\beta$  a goat anti-rabbit peroxidase (Sigma) conjugate in the dilution of 1/800 in PBS/BSA/saponin was used. The colour was developed with 0.6 mg/ml 3,3' diaminobenzidine tetrahydrochloride (DAB) (Sigma) and 0.1% H<sub>2</sub>O<sub>2</sub> plus 1% dimethylsulphoxide (DMSO) (Sigma). Sections were counterstained with 1% methyl-green for 15 min, dehydrated and mounted with permount.

**Positive controls** - As control of the reaction for TNF- $\alpha$  and IFN- $\gamma$  identification cells of the macrophage lineage J-774 (Ralph & Nakoinz 1975), described as "macrophage like" were used. The cells were maintained in RPMI cell culture medium with 10% bovine foetal serum, and collected during the exponential phase growth, at a concentration of  $10^6$  cells/ml. The cells were stimulated for 24 h with 10 ng/ml with lipopolysaccharide (LPS) from the cellular membrane of *Escherichia coli* (Sigma) in a CO<sub>2</sub> chamber, at 37°C. Stimulated cells were centrifuged at 1500 rpm for 10 min. The pellet was suspended in PBS at a concentration of  $10^6$  cells/ml and re-centrifuged at 500 rpm for 5 min in a cytocentrifuge (Cytospin-3-Shandon, Life Sciences International, England) for adhesion to slides previously treated with Poly-L-lysine.

As control of the reaction for TGF- $\beta$ , L-929 fibroblasts from mouse (Willingham & Pastan 1974), were used. The cells were maintained in RPMI cell culture medium with 10% bovine foetal serum, and collected during the exponential phase growth, at a concentration of  $10^6$  cells/ml. These cells without stimulation, were collected, fixed in PBS + paraformaldehyde and processed in the same way as for the J-774 cells.

**Negative controls** - (1) for each section of heart and skeletal muscle from infected animals a correspondent section, obtained from normal intact animal was processed through all steps of immunolabelling (to discard the possibility of cross reaction with *C. callosus* tissue proteins); (2) sections of the tissues either from infected or normal controls were performed through all steps, excluding the

primary antibodies anti each cytokine and maintaining the secondary antibody (rat IgG peroxidase conjugate), to discard the possibility of unspecific reactions.

## RESULTS

**Parasitemia** - Fig. 1 shows the profile of parasitemia, with peak at the 14th day post-infection.

**Histopathology** - As previously described (Magalhães-Santos et al. 2004), histopathological lesions are prominent in the heart and skeletal muscles, in *C. callosus* infected with the Colombian strain of *T. cruzi*. Summarizing, intense inflammatory infiltration in the heart and skeletal muscles and necrotic lesions of the parasitized myocells were present from the 15th to 20th days of infection, predominantly in the myocardium. Cardiac lesions decrease in intensity from 25 to 35 days, being represented by focal necrosis of myocells and focal mononuclear infiltrations. Mild fibroblasts proliferation and interstitial matrix deposits were present. Regression of inflammatory and fibrotic lesions occurred from the 40th day of infection.

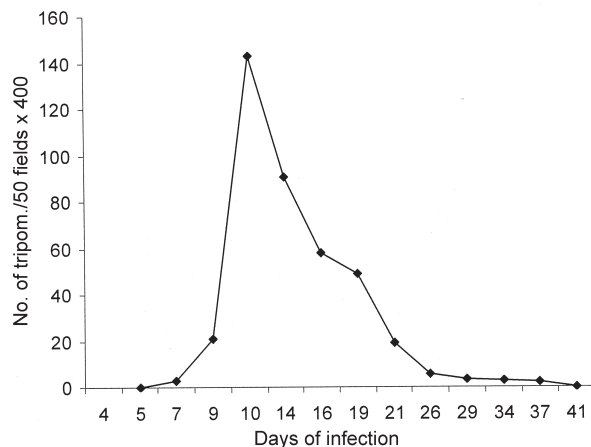


Fig. 1: parasitemic profile from *Calomys callosus* infected with the Colombian strain of *Trypanosoma cruzi*: parasitemic peak occurred at the 14th day post-infection with a rapid decrease until negativation.

Lesions of the skeletal muscle, increased in intensity from 25 to 30 days of infection, with necrosis of parasitized muscle cells, presence of disintegrated polymorphonuclear neutrophils and parasite debris, macrophages, and fibroblasts. Regressive lesions with focal mononuclear infiltration, were present from 35 to 45 days; fibroblasts proliferation and collagen deposit appeared in the interstitium as slender bundles. Parasitism was scarce or absent.

**Normal controls** - Cardiac and skeletal muscle sections showed characteristic histopathological structure.

**Immunohistochemistry** - Cross-reaction of the anti-mouse antibodies with the tissues of *C. callosus* was detected. The monoclonal antibodies anti TNF- $\alpha$ , IFN- $\gamma$ , and TGF- $\beta$  revealed specific immunolabelling of macrophages and necrotic tissues.

**Normal controls** - Sections of the heart and skeletal muscle of intact *C. callosus* treated with each monoclonal antibody through all steps of the procedures to immunolabeling of the cytokines: TNF- $\alpha$ , IFN- $\gamma$ , and TGF- $\beta$ , showed negative results.

**IFN- $\gamma$  immunolabelling** - Positive control: LPS stimulated J-774 macrophages were used to reveal the presence of IFN- $\gamma$  in the cytoplasm of macrophages, taking into account that macrophages are able to release this cytokine during mycobacterial infection (Fenton et al. 1997, Swian 2001). As such, stimulated J-774 cells presented positive immunostaining for IFN- $\gamma$  (Fig. 3G). Heart and skeletal muscle of infected *C. callosus*: from the 15th to 25th day post infection, sections of the heart showed positive immunolabelling for IFN- $\gamma$  in the cytoplasm of macrophages and in extracellular material, corresponding to the inflammatory infiltrates around necrotic myocells (Fig. 2A) and in the extensive areas of necrosis of the skeletal muscle. With 35 and 45 days, the myocardium and the skeletal muscle showed focal and interstitial infiltrates with positive deposits in the cytoplasm of the mononuclear cells and in the interstitium (Fig. 2B). By the 65th days post infection, staining was negative for IFN- $\gamma$  in the myocardium. However, the skeletal muscle showed focal inflammatory infiltrates with positive staining for IFN- $\gamma$ .

**TGF- $\beta$  immunolabeling** - Positive control: the L-929 cells immunolabeled with anti-TGF- $\beta$  antibody, showed positive results (Fig. 3H), with dilutions of 1:10, 1:20, and 1:50. Heart and skeletal muscle showed in the early (15th and 20th days) and advanced phases (35th to 45th days) of infection, TGF- $\beta$  was detected in the myocardium in the cytoplasm of macrophages and fibroblasts; positive extracellular deposits, were also present, in focal inflammatory foci around necrotic myocells (Fig. 2C). In the skeletal muscle, deposits of TGF- $\beta$  were seen as positive mild staining in the cytoplasm of macrophages and fibroblasts and in extracellular material, from the 15th to 45th day of infection (Fig. 2D). However, TGF- $\beta$  was not detected in the amorphous material of the extensive necrotic-inflammatory lesions in the skeletal muscle, present in the 25th day of infection. In the 45th days of infection, rare cells with scarce positive staining for TGF- $\beta$  were present in focal inflammatory lesions. By the 65th days, residual infiltrates were seen in the myocardium and skeletal muscle, TGF- $\beta$  being absent.

**TNF- $\alpha$  immunolabeling** - As a positive control for TNF- $\alpha$  antibody, the J-774 cells were immunolabeled with the monoclonal anti-TNF- $\alpha$  antibody with positive staining (Fig. 3I).

Sequential study from the 15 to 25 days of infection, showed the expression of TNF- $\alpha$  in small inflammatory foci in the myocardium, corresponding to areas of focal necrosis of myocells (Fig. 2E), in the cytoplasm of macrophages and in the amorphous necrotic cellular debris. Intense positive immunolabeling for TNF- $\alpha$  in the cytoplasm of macrophages and in the extracellular necrotic material was present mainly in the skeletal muscle. From the 35th to the 45th day of infection, small foci of inflammation with positive intra and extracellular deposits of

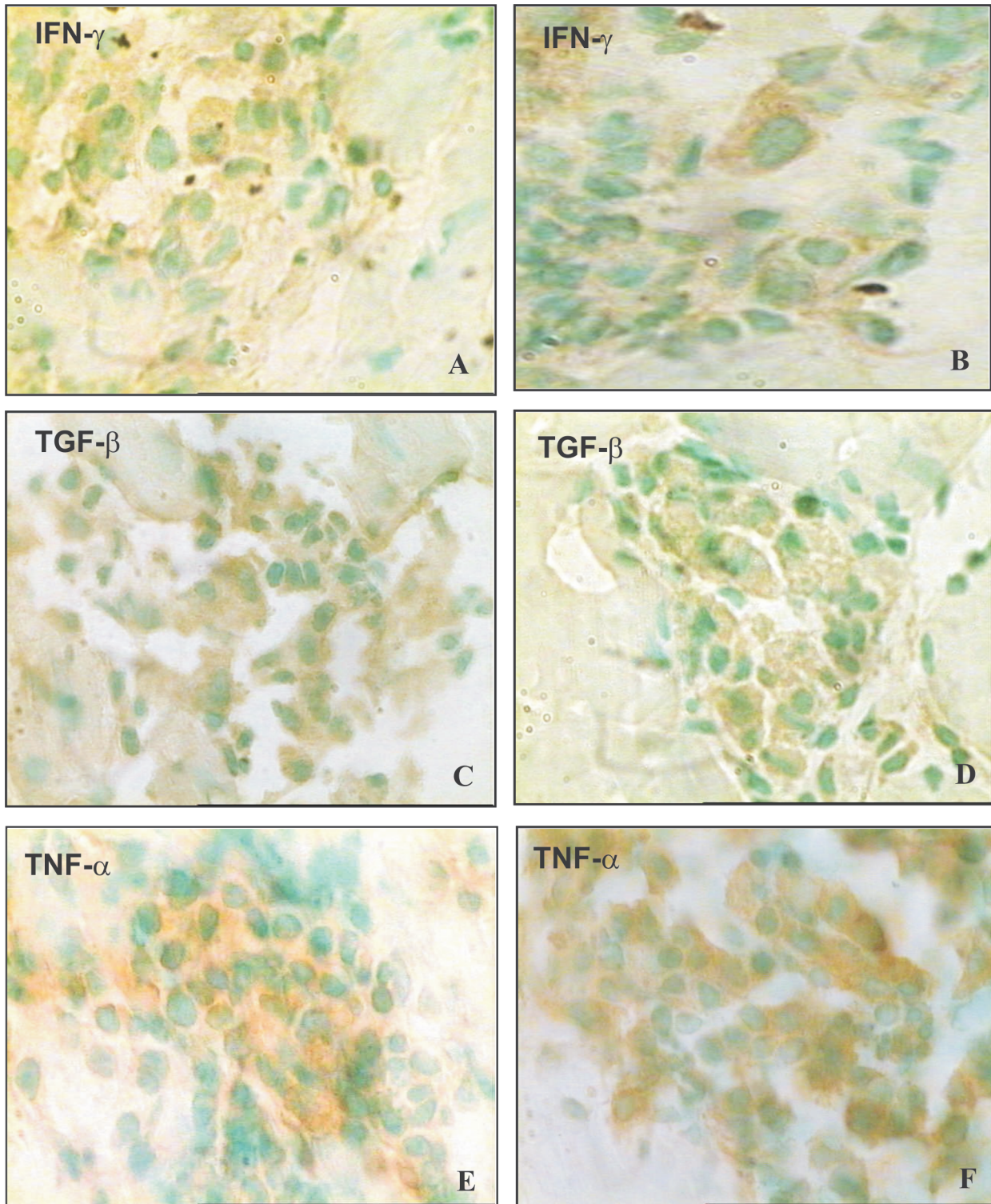


Fig. 2A, B: IFN- $\gamma$  immunostaining - Immunohistochemical identification of the IFN- $\gamma$  in the heart and skeletal muscle of *Calomys callosus* infected with *Trypanosoma cruzi*. A: inflammatory cells in the myocardium showing positive expression of IFN- $\gamma$  in the advanced (25 days) phase of infection; B: skeletal muscle (45 days post-infection), showing the expression of IFN- $\gamma$  in the macrophages present in focal areas of myocells necrosis; in mononuclear cells of interstitial infiltrates and in the extracellular deposits. 1000 $\times$ . C, D: TGF- $\beta$  immunostaining. Immunohistochemical identification of the TGF- $\beta$ , in the heart and skeletal muscle of *Calomys callosus* infected with *T. cruzi*. C: myocardium with positive staining for TGF- $\beta$  in the cytoplasm of macrophages and in the interstitium, in focal areas of inflammatory infiltration, in the early (15 days) phase of infection; D: skeletal muscle (35 days), inflammatory focus with positive staining in the cytoplasm of macrophages and in the interstitium. 1000 $\times$ . E, F: TNF- $\alpha$  immunostaining. Immunohistochemical identification of the TNF- $\alpha$  in the heart and skeletal muscle of *C. callosus* infected with *T. cruzi*; E: myocardium (20th day), necrotic area with mononuclear infiltrate showing positive staining for TNF- $\alpha$  in the cytoplasm of macrophages and in the amorphous necrotic cellular debris; F: skeletal muscle (35th day), focal area of necrosis with intra and extracellular deposits of TNF- $\alpha$ . 1000 $\times$ .

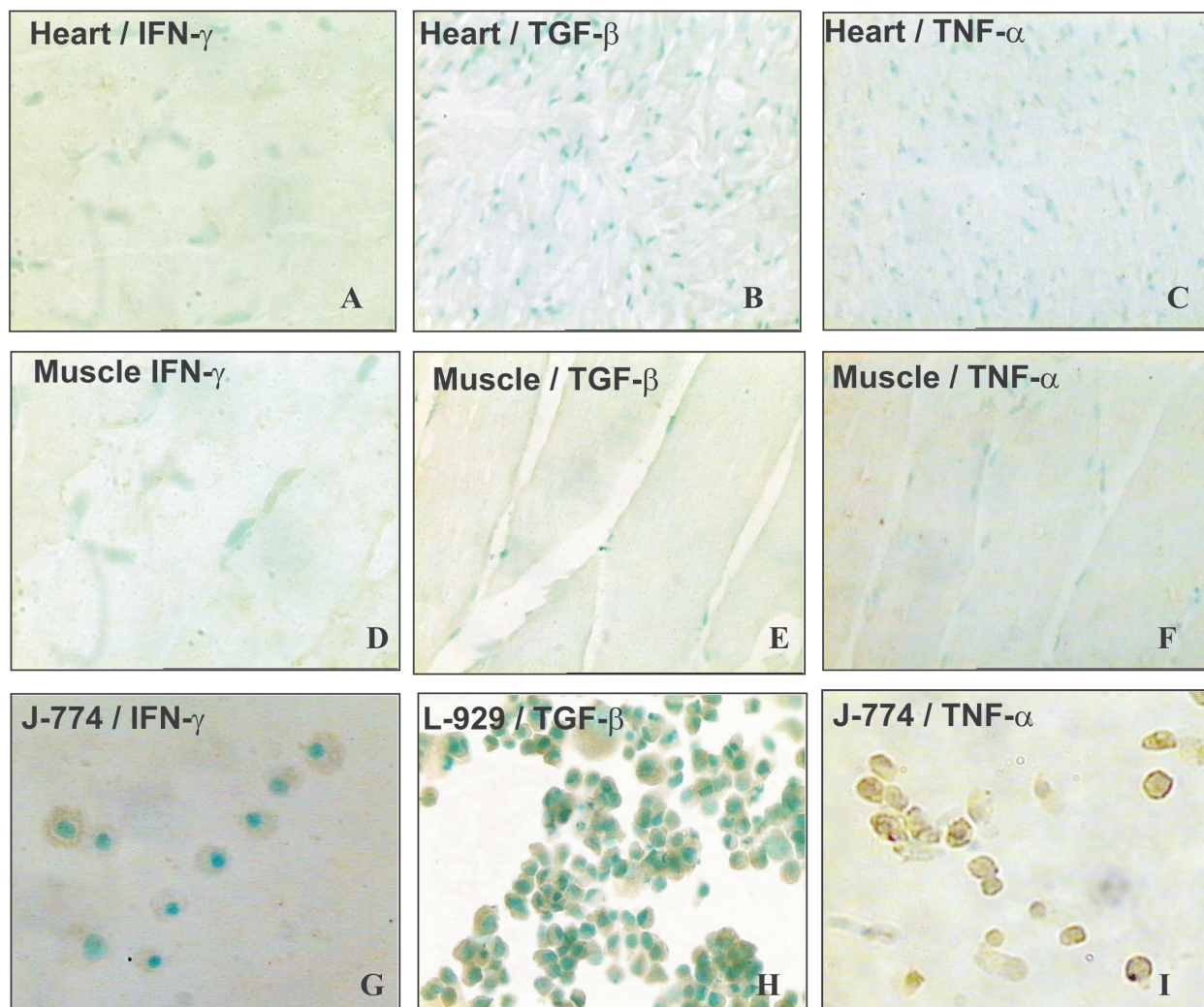


Fig. 3A, B, C: negative controls of the immunostaining - Sections of the heart obtained from normal *Calomys callosus*. A: IFN- $\gamma$  immunostaining; B: TGF- $\beta$  immunostaining; C: TNF- $\alpha$  immunostaining. Results were negative, 1000 $\times$ . D, E, F: sections of skeletal muscles from normal *C. callosus*. D: IFN- $\gamma$  immunostaining; E: TGF- $\beta$  immunostaining; F: TNF- $\alpha$  immunostaining. Results were negative 1000 $\times$ . G, H, I: positive controls. G: the J-774 cells, LPS stimulated, treated with the specific monoclonal anti-IFN- $\gamma$ , showed positive immunolabeling for this cytokine; H: positive control - The L-929 cells immunolabeled with anti-TGF- $\beta$  antibody, showed positive results, with dilutions of 1:10, 1:20, and 1:50; I: positive control - J-774 cells immunolabeled with the monoclonal anti-TNF- $\alpha$  antibody. 1000 $\times$ .

TNF- $\alpha$ , were seen in the myocardium and skeletal muscle (Fig. 2 F). At 65th days of infection, residual infiltrates were seen in the myocardium and skeletal muscle, but these deposits does not present positivity for TNF- $\alpha$ .

#### DISCUSSION

*T. cruzi* infection determines parasitism of the myocardium, with intense myocarditis due to an immunological response at cellular and humoral levels, with production of a panel of inflammatory and regulatory cytokines (Gazzinelli & Brener 1991, Morgan et al. 1996) as seen in human patients from endemic areas, during acute infection.

Experimental investigations of immunologic responses during acute infection have preferentially been developed in the mice model (Silva et al. 1991, Abrahamssohn 1998)

which contributes to clarify the pathogenesis of lesions. In the murine model, infection with *T. cruzi* is followed by activation of macrophages as an initial innate response, mediated by IFN- $\gamma$  produced by natural killer cells (Cardillo et al. 1996). Macrophages are then primed for further production of cytokines as TNF- $\alpha$ , TGF- $\beta$ , and others, and to produce microbicidal agents such as N and O metabolites: nitric oxide (NO) and H<sub>2</sub>O<sub>2</sub> (Gazzinelli et al. 1992, Silva et al. 1995, Dos Reis 1997).

In the model of *C. callosus*, the investigation on the participation of the different cytokines in the progressive lesions has been restricted by the absence of available specie-specific monoclonal antibodies. In previous studies (Borges et al. 1995), evaluation of IFN- $\gamma$  levels in *C. callosus* infected with *T. cruzi*, was performed by titration of antiviral activity on L-929 cells, by using a stan-

dard encephalomyocarditis virus cytopathic-effect-inhibitor. To characterize the antiviral activity, serial dilutions of serum samples were incubated with anti-murine IFN- $\gamma$  monoclonal antibody. The antiviral activity has been tested both in *C. callosus* and mouse sera and was abolished 100% by the monoclonal antibody. The neutralization effect implies in a cross-reactivity between IFN- $\gamma$  of mice and that of *C. callosus*. Cross-reactive antibodies to mouse cytokines have been used in the present study, for the demonstration of the cytokines involved in the different phases of infection.

In situ demonstration, of the cytokines involved in the response to infection with *T. cruzi*, has been done by Zhang and Tarleton (1996), in the spleen of infected mice. Pro-inflammatory cytokines as TNF- $\alpha$  and IFN- $\gamma$ , as well as the regulatory cytokine TGF- $\beta$  were identified during the course of infection in this study, and persisted until an advanced phase (70 days) (Zhang & Tarleton 1996). It has been demonstrated histochemically (Lima et al. 2001), in highly susceptible inbred mice (C3H/He), infected with a macrophagotropic strain (Biodeme Type I), the participation of TNF- $\alpha$  in the massive parasite destruction and spleen necrosis. In mice model it has been demonstrated that macrophages of susceptible inbred mice produce higher levels of TNF- $\alpha$  than the most resistant strains (Russo et al. 1989).

Differing from the murine model, the evolution of the lesions in *C. callosus* infected with the Colombian strain was very rapid, corresponding to an early elevation of parasitemic levels, with peak at the 14th day, followed by a drop in crisis. This means that the *C. callosus* is highly susceptible to *T. cruzi* infection but controls the parasite multiplication. These observations were associated with in situ expression of TNF- $\alpha$  and IFN- $\gamma$ . Probably the TNF- $\alpha$  and IFN- $\gamma$  are mediating parasite disintegration by macrophage activation, with release of O metabolites such as H<sub>2</sub>O<sub>2</sub>, as demonstrated by Borges et al. (1995). In the present study it has been demonstrated that IFN- $\gamma$  persists in *C. callosus* tissues for a prolonged time (65 days) as compared with the other cytokines that were absent in the heart and skeletal muscle at this phase. Serum levels of IFN- $\gamma$  were evaluated in *C. callosus* and Swiss mice, infected with different strains of *T. cruzi* (Borges et al. 1995), in an attempt to correlate this cytokine with the control of infection in vivo. The highest IFN- $\gamma$  serum levels in *C. callosus*, were obtained with strain F (Biodeme Type III, *T. cruzi* I), with peak at 7-day and with titers maintaining a plateau until day 28 and dropping after that to baseline levels. Differing from *C. callosus*, in the infection of mice with the F strain (Borges et al. 1995), IFN- $\gamma$  peaks occur lately, between days 21 and 28 after infection, with a retarded drop. According to Silva et al. (1991) the regulation of IFN- $\gamma$  mediated killing of the intracellular *T. cruzi* amastigotes in mice, is mediated by TGF- $\beta$  produced during acute infection. In vivo studies (Silva et al. 1991) have shown that the administration of TGF- $\beta$  on *T. cruzi* infected resistant mice led to significantly increased parasitemias and mortalities. It is also a potent regulator of inflammation, being pro-inflammatory at low concentrations and anti-inflammatory at high concentrations (Omer et al. 2000). According to these authors *T. cruzi* is

unable to invade cells lacking TGF- $\beta$  receptors I or II. In the *C. callosus* model, the presence of TGF- $\beta$  in the lesions of myocardium and skeletal muscle was detected since the early phase. This is consistent with the participation of TGF- $\beta$  in the modulation of the other cytokines and in the early fibrogenesis, which follows the repair of lesions. The exsudative lesions characteristic of the intracellular parasites disintegration are replaced by macrophages collections and epithelioid cells, forming granulomatous lesions and proliferation of fibroblasts, characteristics of the delayed cellular immune response. Stimulation of fibrogenesis became clear, coincident with the presence of TGF- $\beta$ , a pro-fibrogenic and regulatory cytokine in the cytoplasm of the macrophages and fibroblasts (Varga et al. 1987, Branton & Kopp 1999). The decrease and disappearance of the tissue cytokines, from 35 to 45 days of infection coincided with the regression of the inflammatory and fibrotic lesions, although with persistence of IFN- $\gamma$  until later on (65th day).

The results of the present study suggests that the *in situ* expression of cytokines such as IFN- $\gamma$ , TNF- $\alpha$ , and TGF- $\beta$ , is associated with the controlling of the parasite multiplication and precocious modulation of tissue lesions in *C. callosus* infected with *T. cruzi*. These findings demonstrated that this sylvatic animal is highly susceptible to the infection with the Colombian strain (Biodeme Type III, *T. cruzi* I). However it has the capacity of controlling the parasitic proliferation, without dying, a very convenient arrangement for a natural reservoir of parasites.

#### ACKNOWLEDGMENTS

To Dr José Mengel, who provided the anti-TGF- $\beta$  purified polyclonal antibody. To Dr Fabiola Cardillo for reading the text and valuable suggestions. To Biologist Ariane R Pimentel to her assistance in the development of the immunohistochemical techniques.

#### REFERENCES

- Abrahamsohn IA 1998. Cytokines in innate and acquired immunity to *Trypanosoma cruzi* infection. *Braz J Med Biol Res* 31: 117-121.
- Andrade SG, Kloetzel JK, Borges MM, Ferrans VJ 1994. Morphological aspects of the myocarditis and myositis in *Calomys callosus* experimentally infected with *Trypanosoma cruzi*: fibrogenesis and spontaneous regression of fibrosis. *Mem Inst Oswaldo Cruz* 89: 379-393.
- Andrade SG, Magalhães JB 1997. Biodemes and zimodemes of *Trypanosoma cruzi* strains: correlations with clinical data and experimental pathology. *Rev Soc Bras Med Trop* 30: 27-35.
- Borges MM, Andrade SG, Pilatti CG, Prado-Jr JC, Kloetzel JK 1992. Macrophage activation and histopathological findings in *Calomys callosus* and Swiss mice infected with several strains of *Trypanosoma cruzi*. *Mem Inst Oswaldo Cruz* 87: 493-502.
- Borges MM, Mello, DA, Teixeira ML 1982. Infecção experimental de *Calomys callosus* (Rodentia - Cricetidae) com *Trypanosoma cruzi*. *Rev Saúde Publ São Paulo* 16: 233-242.
- Borges MM, VassaoR, Andrade SG, Pereira CA, Kloetzel JK 1995. Interferon-gamma levels during the course of *Trypa-*

- nosoma cruzi* infection of *Calomys callosus* (Rodentia-Cricetidae) and swiss mice. *Parasitol Res* 81: 498-504.
- Branton MH, Kopp JB 1999. TGF- $\beta$  and fibrosis. *Microbes Infect* 1: 1349-1365.
- Cardillo F, Voltarelli JC, Reed SG, Silva JS 1996. Regulation of *Trypanosoma cruzi* infection in mice by gamma interferon and interleukin 10: role of NK cells. *Infect Immun* 64: 128-134.
- Dos Reis G 1997. Cell-mediated immunity in experimental *Trypanosoma cruzi* infection. *Parasitol Today* 13: 335-342.
- Fenton MJ, Vermeulen MW, Kim S, Burdick M, Strieter RM, Kornfeld H 1997. Induction of gamma interferon production in human alveolar macrophages by *Mycobacterium tuberculosis*. *Infect Immun* 65: 5149-5156.
- Gazzinelli G, Brener Z 1991. Immunological aspects of the morbidity of human Chagas' disease. *Res Immunol* 142: 167-169.
- Gazzinelli RT, Oswaldo IP, Hieny S, James SL, Sher 1992. The microbicidal activity of IFN $\gamma$  treated macrophage against *Trypanosoma cruzi* involves an L-arginine-dependent, nitrogen oxide-mediated mechanism inhibitable by IL-10 and TGF- $\beta$ . *Eur J Immunol* 22: 2501-2506.
- Junqueira LCU, Bignolas G, Brentani RR 1979. Picosirius staining plus polarization microscopy, a specific method for collagen detection in tissue sections. *Histochem J* 11: 447-455.
- Lenzi JÁ, Mota EM, Pelajo-Machado M, Paiva RAN, Lenzi HL 1995. *Calomys callosus*: an alternative model to study fibrosis in schistosomiasis mansoni. The pathology of the acute phase. *Mem Inst Oswaldo Cruz* 90: 311-318.
- Lima ES, Andrade ZA, Andrade SG 2001. TNF- $\alpha$  is expressed at sites of parasite and tissue destruction in the spleen of mice acutely infected with *Trypanosoma cruzi*. *Int J Exp Pathol* 82: 327-336.
- Magalhães-Santos IF, Lima ES, Andrade SG 2002. Fibrogenesis and collagen resorption in the heart and skeletal muscle of *Calomys callosus* experimentally infected with *Trypanosoma cruzi*: immunohistochemical identification of extracellular matrix components. *Mem Inst Oswaldo Cruz* 97: 703-710.
- Magalhães-Santos IF, Souza MM, Costa-Lima CS, Andrade SG 2004. Infection of *Calomys callosus* (Rodentia cricetidae) with strains of different *Trypanosoma cruzi* biotopes: pathogenicity, histotropism, and fibrosis induction. *Mem Inst Oswaldo Cruz* 99: 407-413.
- Mello DA 1979. Infecção experimental de *Calomys callosus* (Renger 1830) (Cricetidae - Rodentia) a quatro espécies de parasitos. *Rev Soc Bras Med Trop* 13: 101-105.
- Mello DA 1982. Roedores marsupiais e triatomíneos silvestres capturados no município de Mambá-Goiás. Infecção natural pelo *Trypanosoma cruzi*. *Rev Saúde Públ S Paulo* 16: 282-291.
- Morgan J, Dias JC, Gontijo ED, Bahia-Oliveira L, Correa-Oliveira R, Colley DG, Powell MR 1996. Anti-*Trypanosoma cruzi* antibody isotype profiles in patients with different clinical manifestations of Chagas' disease. *Am J Trop Med Hyg* 55: 355-359.
- Omer F, Kurtzhals J, Riley E 2000. Maintaining the immunological balance in parasitic infections a role of TGF $\beta$ ? *Parasitol Today* 16: 18-23.
- Ralph P, Nakoinz I 1975. Phagocytosis and cytolysis by a macrophage tumour and its cloned cell line. *Nature* 257: 393-394.
- Russo M, Starobinas N, Ribeiro SR, Minoprio P, Eisen H, Hontebeyrie JM 1989. Susceptible mice present higher macrophage activation than resistant mice during infections with myotropic strains of *Trypanosoma cruzi*. *Parasite Immunol* 11: 385-395.
- Silva JS, Twardzik DR, Reed SG 1991. Regulation of *Trypanosoma cruzi* infections *in vitro* and *in vivo* by transforming growth factor  $\beta$  (TGF- $\beta$ ). *J Exp Med* 174: 539-545.
- Silva JS, Vespa GN, Cardoso MA, Aliberti JC, Cunha FQ 1995. Tumor necrosis factor alpha mediates resistance to *Trypanosoma cruzi* infection in mice by inducing nitric oxide production in infected gamma interferon-activated macrophages. *Infect Immun* 63: 4862-4867.
- Swian SL 2001. Interleukin 18: tipping the balance towards a T helper cell 1 response. *J Exp Med* 194: 11-14.
- Teixeira MM, Gazzinelli RT, Silva JS 2002. Chemokines inflammation and *Trypanosoma cruzi* infection. *Trends Parasitol* 18: 262-265.
- Varga J, Rosenbloom J, Jimenez SA 1987. Transforming growth factor beta (TGF- $\beta$ ) causes a persistent increase in steady-state amounts of type I and type III collagen and fibronectin mRNAs in normal human fibroblasts. *Biochem J* 247: 597-604.
- Willingham MC, Pastan I 1974. Cyclic AMP mediates the concanavalin A agglutinability of mouse fibroblasts. *J Cell Biol* 63: 288-294.
- Zhang L, Tarleton RL 1996. Characterization of cytokine production in murine *T. cruzi* infection by *in situ* immunohistochemistry: lack of association between susceptibility and T helper type 2 cytokine production. *European J Immunol* 26: 102-109.