

Viral encephalitis

Encefalites virais

Marcus Tullius T Silva

ABSTRACT

While systemic viral infections are exceptionally common, symptomatic viral infections of the brain parenchyma itself are very rare, but a serious neurologic condition. It is estimated that viral encephalitis occurs at a rate of 1.4 cases per 100.000 inhabitants. Geography is a major determinant of encephalitis caused by vector-borne pathogens. A diagnosis of viral encephalitis could be a challenge to the clinician, since almost 70% of viral encephalitis cases are left without an etiologic agent identified. In this review, the most common viral encephalitis will be discussed, with focus on ecology, diagnosis, and clinical management.

Keywords: viral encephalitis, herpes virus, dengue virus, Influenzae, West Nile virus.

RESUMO

Embora as infecções virais sistêmicas sejam muito comuns, as infecções virais sintomáticas do parênquima cerebral são raras, mas potencialmente graves. Estima-se que a encefalite viral ocorra em 1,4 casos por 100.000 habitantes anualmente. A localização geográfica é um fator determinante a ser levado em consideração frente aos patógenos transmitidos por vetores. O diagnóstico clínico das encefalites virais pode ser um desafio para o clínico, visto que quase 70% dos casos de encefalite viral ficam sem a identificação do agente viral. Nesta revisão, as encefalites virais mais comuns serão discutidas, com interesse especial sobre os aspectos da ecologia, do diagnóstico e do seu manejo clínico.

Palavras-Chave: encefalites virais, herpes vírus, vírus da dengue, Influenzae, vírus do oeste do Nilo.

VIRAL ENCEPHALITIS

The term encephalitis corresponds to an inflammation of the brain parenchyma caused by both infectious and non-infectious diseases. Viruses are the most common infectious agents associated with acute encephalitis. The cardinal symptoms and signs of acute viral encephalitis are fever, altered level of consciousness, headache, focal neurological deficits, and seizure.

The most common viruses that cause encephalitis are listed in Table 1. Noteworthy, about 70% of viral encephalitis cases remain of unknown origin, even with modern laboratorial techniques¹. It is of primordial importance a detailed epidemiological history about recent travels or animal contacts, since some viruses are common in some regions and not seen in others.

The most important agents worldwide are the herpes viruses and the arboviruses. In developed countries, HSV-1 is the leading cause of sporadic encephalitis in adults, while the varicella zoster virus (VZV) is responsible to up to 22% of

pediatric cases. However, numerically Japanese encephalitis is the most common encephalitis worldwide, while the West Nile virus is the most widespread virus and can be encountered in parts of Europe, Russia, Africa, the Middle East, India, Indonesia, and North America. Noteworthy, it is estimated that even in the Occident, the larger, undiagnosed proportion of encephalitis cases are caused by one of the arboviruses.

Differential diagnosis of viral encephalitis is wide and includes other infections of the central nervous system (CNS), autoimmune diseases such as ADEM, limbic encephalitis, Rasmussen's syndrome, and metabolic diseases. This paper will focus on some specific viral encephalitis.

1. Herpes viruses

Herpes simplex virus type 1 and 2 (HSV-1, HSV-2)

HSV-1 is by far the most common etiologic agent of acute sporadic encephalitis in the world, ranging from 10% to 20% of all annual cases of encephalitis in the US. The incidence is estimated in 2.2 cases per 1.000.000 inhabitants, and majority

MD, PhD, Neurologist, Associated Researcher, Clinical Research Laboratory on Neuroinfection Diseases, National Institute of Infectious Diseases – Fundação Oswaldo Cruz, FIOCRUZ, Rio de Janeiro RJ, Brasil.

Correspondence: Marcus Tullius T Silva; Laboratório de Pesquisa Clínica em Neuroinfecção; Instituto Nacional de Doenças Infecciosas - FIOCRUZ; Avenida Brasil 4365; 21040-360 Rio de Janeiro RJ - Brasil; E-mail: marcustullius@ipecc.fiocruz.br; Tel: +55 21 3865-9595

Financial support: Conselho Nacional de Desenvolvimento Científico e Tecnológico (CNPq)

Table 1. Primary viral causes of viral encephalitis.

Agent	
Nonpolio enteroviruses	
Arboviruses	
	Togaviruses Flaviviruses Alphaviruses
	WNV* EEE
	SLE WEE
	Powassan VEE
	Dengue virus*
	Yellow fever*
	Reoviruses Colorado tick fever
	Bunyaviruses La Crosse virus
	Jamestown Canyon virus
Herpes viruses	HSV-1*
	HSV-2
	VZV*
	CMV*
	EBV*
	HHV-6*
	HHV-8
	Herpes B virus
Arenavirus	LCMV*
Mumps virus*	
Measles virus*	
Rubella virus*	
Influenza virus*	
Rabies virus*	

WNV: West Nile virus; SLE: St. Louis encephalitis virus; EEE: Eastern equine encephalitis; WEE: Western equine encephalitis; VEE: Venezuelan equine encephalitis; HSV: Herpes virus; VZV: Varicella Zoster virus; EBV: Epstein-Barr virus; HHV: Human herpes virus; LCMV: Lymphocytic choriomeningitis virus; *: correspond to viruses discussed in this paper.

of cases are seen in adults². Almost 90% of all adult cases of HSV encephalitis are caused by HSV-1; HSV-2 is associated with recurrent meningitis in adults and congenitally acquired neonatal HSV-2 meningoencephalitis.

HSV-1 gain access in CNS by one of the following routes: invasion via trigeminal nerve or olfactory tract after primary infection in the oropharynxes; CNS penetration after recurrent viral infection, that is, viral reactivation followed by viral spread; and CNS invasion after viral reactivation of a latent HSV in the brain³. After CNS invasion, a focal inflammatory and necrotizing lesion is observed specially in the temporal lobes, orbital frontal cortex, and limbic structures.

Generally, neurological findings are acute, with less than one week in duration. These include altered level of consciousness, behavioral disturbances, and focal neurological deficits (including aphasia/dysphasia). Majority of patients will present fever and headache besides one of the above symptoms. Meningeal sings are uncommon. Immunosuppressed patients may exhibit a more indolent clinical course (see Figure 1).

EEG shows unilateral or bilateral periodic lateralized epileptiform discharges, while brain MRI discloses

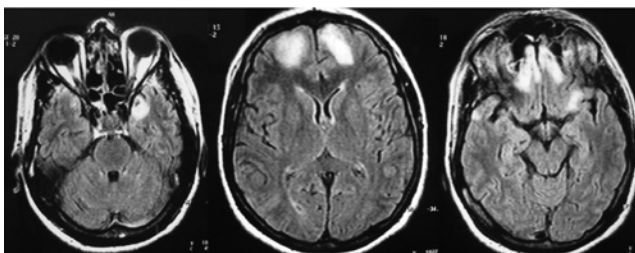


Figure 1. A 36-year old HIV-infected man presented in May 2010 with anxious disorders, psychomotor agitation, discrete memory impairment, and visual hallucination started 2 weeks before admission. A brain CT performed in the emergency sector of a peripheral hospital was normal. He was discharged of this hospital with 2 mg daily of risperidone and with a psychiatric consultation scheduled within 6 weeks. In the end of June 2010, he was admitted at FIOCRUZ after a generalized seizure. He had a severe memory impairment, but no focal neurologic deficit was present. CD4 counts were 108 cells/mm³. A brain MRI (FLAIR sequence) disclosed a hyperintense signal in right temporal lobe and orbitofrontal regions, bilaterally. A lumbar puncture was performed, showing a discrete lymphocytic pleocytosis and protein elevation. IV acyclovir was started immediately. PCR HSV-1 was positive and the therapy was maintained for 21 days. A new PCR test was done before patient's discharge and was negative. He was left with a mild memory deficit only.

hyperintensity in fluid-attenuated inversion recovery (FLAIR) and T2-weighted images in one or both of the temporal and orbitofrontal lobes, often extending to the insular and cingulate gyri. Although initial CSF analysis may be normal, typically a HSV-1 encephalitis patient will have a mononuclear cell pleocytosis around 40 WBCs/mm³ and a discrete elevation on protein content (median of 70 mg/dL)⁴. Pleocytosis diminishes with antiviral therapy, but can persist at a low level for weeks or even months. Glucose levels are normal in majority of cases, but hypoglycorrhachia has been reported in neonatal cases of HSV-2 encephalitis. The presence of red blood cells is neither sensitive nor specific for HSV encephalitis.

CSF PCR is nowadays the mainstay in the diagnosis of HSV-1 encephalitis, with sensibility and specificity exceeding 95%. After antiviral therapy, the rate of positive HSV-1 PCR decrease over time, usually beginning after a full week of therapy⁵. A second lumbar puncture with PCR analysis after 2 weeks of treatment is suggested by some; if positive, continuing therapy is recommended.

Immediate infusion of acyclovir is the mainstay of treatment and can reduce mortality by more than 70%. Favorable prognosis is seen in patients who are treated early, who are younger than 30 years of age, have short duration of illness, a Glasgow Coma Scale score of more than 6, and who have a low viral load on CSF². However, even with early treatment, mortality may reach 20% of total cases; less than 10% of survivors are left without neurological or cognitive deficits.

Varicella-Zoster Virus (VZV)

Actually, most cases of CNS diseases in the course of VZV infection are secondary to inflammation on cerebrovascular endothelial vessels and/or infection of choroidal cells⁶. Thus, the term VZV cerebral vasculopathy is preferred instead of VZV encephalitis.

Both primary infection and VZV reactivation may produce CNS disease in immunocompromised patients. VZV cerebral vasculopathy may also be seen in immunocompetent patients. VZV vasculopathy presents with acute focal neurological deficits due to involvement of large cerebral arteries following trigeminal distribution of zoster by weeks to months. In immunocompromised patients, VZV vasculopathy presents as a multifocal vasculopathy involving small and medium-size arteries, resulting in mental status changes, focal deficits, and mononuclear pleocytosis in the CSF. Mixed ischemic and hemorrhagic infarcts in subcortical gray and white matter and demyelinate lesions are noted both in brain MRI and pathological studies. Noteworthy, typical rash of zoster may be absent in these patients⁶.

CSF shows a mild lymphocytic pleocytosis, ranging from 7 to 260 WBCs/mm³, and normal or discreetly elevated total protein levels (maximum 76mg/dL). The glucose level is normal in the majority of cases. Oligoclonal bands can be documented in 30% of cases a week or more after the onset of symptoms⁷. Intrathecal antibodies directed against viral antigens can be used to confirm a diagnosis of VZV CNS disease, even when the CSF PCR assay is negative. The presence of anti-VZV IgG antibodies is said to be more sensitive than PCR in the diagnosis of Zoster cerebral vasculopathy⁸.

No controlled randomized clinical trials have been conducted of antiviral therapy for CNS VZV infection. VZV vasculopathy should be treated with a combination of acyclovir and a pulse of corticosteroid.

Cytomegalovirus (CMV)

Beyond the neonatal period, CMV encephalitis is extremely uncommon in immunocompetent patients. However, immunosuppressed patients may develop CMV encephalitis, especially AIDS and bone marrow transplanted patients. CMV encephalitis during AIDS occurs in at least 6% of untreated patients with advanced HIV disease; the incidence is much lower in patients under antiretroviral therapy⁹.

CMV encephalitis is characterized by nonspecific febrile encephalopathy, with or without focal features. It can present acutely - *microglial nodular encephalitis* - with delirium and confusion, or subacutely - *ventriculoencephalitis* - characterized by confusion and cranial nerves dysfunction. One quarter of patients have brainstem involvement with vertical or horizontal gaze-evoked nystagmus, internuclear ophthalmoplegia, and cranial neuropathies¹⁰. CMV encephalitis is a consequence of reactivation of previously latent virus infection. The virus has a predilection for ependymal cells of

the lateral ventricles and may be suspected when brain MRI shows contrast-enhancing lesions as streaks surrounding the lateral ventricles in a patient with clinical encephalitis. Usually, CMV encephalitis is encountered in the context of CMV retinitis, characterized by large yellow or white exudates, or CMV gastrointestinal disease. Characteristically, CSF analysis discloses a polymorphonuclear pleocytosis, depressed glucose, and raised protein levels. A PCR test positive for CMV in the CSF has a reported sensitivity of 82% and specificity of 99% in AIDS patients¹⁰. Recommended treatment is IV ganciclovir for 3 weeks followed by a maintenance dosing with either IV ganciclovir or oral valganciclovir.

Epstein-Barr virus (EBV)

Classical manifestation of primary EBV infection is the infectious mononucleosis syndrome, a systemic disease characterized by cervical lymphadenopathy, pharyngitis, and splenomegaly. EBV-associated CNS diseases may occur in less than 1% of mononucleosis patients and can present as meningitis (the most common), encephalitis, cerebellitis, transverse myelitis, optical neuritis, cranial neuropathy, Guillain-Barré syndrome, and small-fiber sensory or autonomic neuropathy syndrome¹¹.

EBV encephalitis may present with frank encephalopathy with altered consciousness, coma, seizures, and focal neurological deficits. It can occur before, during, or after infectious mononucleosis or even in its absence. Some patients may exhibit an encephalomyeloradiculitis and some cases may mimic HSV-1 encephalitis. In the Collaborative Antiviral Study Group trial, EBV encephalitis accounted for about 8% of the HSV-1-negative cases of focal encephalitis¹².

Specific diagnosis requires EBV DNA amplification from CSF or serological studies indicative of acute infection. In serum, the presence of EBV viral capsid antigen (VCA) IgM antibody is indicative of recently acquired and active EBV infection, but do not establishes CNS disease. None of the currently available antiviral agents have activity against EBV *in vitro*, but there are some reports of ganciclovir treatment in EBV meningoencephalitis after bone marrow transplantation.

Human herpes virus type 6 (HHV-6)

HHV-6 is a T lymphotropic virus that causes a spectrum of diseases like *exanthema subitum*, lymphadenopathy syndromes, and meningoencephalitis. A retrospective analysis of non-HSV encephalitis cases showed that 6% of cases were due to HHV-6 infection¹³. The virus has also a controversial role in other neurologic conditions, such as febrile seizures in infants, subsequent temporal lobe epilepsy, and cranial nerve palsies. However, it is recognized as an agent in some cases of limbic encephalitis in bone marrow transplant recipients¹⁴. Clinical and radiological picture is similar to paraneoplastic and anti-voltage-gated potassium channel limbic encephalitis. Patients present generally with behavioral disturbances,

severe memory impairment, and agitation. The prognosis is better than in herpetic encephalitis and treatment is generally done with ganciclovir and foscarnet.

2. Nonpolio enteroviruses (EV)

Enteroviruses (EV) pertain to Picornaviridae family and comprise over 70 different serotypes. They are the most common cause of viral meningitis worldwide, and it is estimated that 3% of these patients develop encephalitis during the infection. Furthermore, isolated EV encephalitis occurs in 2% to 25% of confirmed viral encephalitis cases, especially in immunodeficient patients with hypogammaglobulinemia and in neonates^{4,15}.

EV are transmitted via a fecal-oral route and certain serotypes predominate in a particular geographical area, causing cyclical outbreaks when there are sufficient non-immunized individuals present, mainly young children. The EV-71 serotype has been associated with a higher rate of encephalitis, specifically with a focal brainstem dysfunction. Affected patients are usually young children that present fever, myoclonus, ataxia, nystagmus, and cranial nerve palsies. Most patients recover, but around 20% are left with some neurological sequelae. Sometimes, a rapidly progressive neurogenic pulmonary edema is observed, carrying a mortality rate of 80%. CSF analysis in EV encephalitis usually reveals a lymphocytic pleocytosis (median 100 WBC/mm³), slightly elevated protein level (median 54 mg/dL), and normal glucose. PCR is more sensitive than viral cultures for diagnosis, but most of the studies were conducted in patients with EV meningitis¹⁶. There is no specific treatment, but pleconaril and intravenous immunoglobulin have been tried.

3. Arboviruses

Arbovirus is the acronym for *arthropod-borne virus*, a vast group of viruses that are transmitted to humans by mosquito and tick vectors. Arbovirus are grouped in three families; togaviruses (flaviviruses and alphaviruses), reoviruses, and bunyaviruses. Considered together, arboviruses represent the leading cause of encephalitis worldwide.

West Nile virus (WNV)

WNV is transmitted from infected birds to humans by *Culex* or *Aedes* mosquitos. Human outbreaks became more frequent and reported nowadays. In 2009, almost 30000 cases of WNV-associated human disease were reported to CDC. Neurological manifestations of WNV include meningitis, encephalitis, myelitis, and polio-like illness. These manifestations are expected in 1 out of 150 infected persons¹⁷. After infection, symptoms and signs of a systemic viral disease appear 2 to 14 days after, and in about half of the patients a rash maculopapular is observed.

Pathologically, WNV causes an encephalomyelitis and leptomeningitis, characterized by microglial nodules with

neuronal loss in the gray and white matter of the cerebrum, hippocampus, thalamus, medulla, and anterior horn cells, which explain the neurological manifestations observed in these patients. WNV encephalitis is the most common neurological manifestation of neuroinvasive WNV disease. An abruptly onset of fever and altered mental status is observed in majority of patients. Other clinical manifestations are diffuse proximal muscular weakness, respiratory paralysis, tremor, myoclonus, and Parkinsonism features (as seen in Japanese encephalitis). The overall mortality from WNV infection is around 6%, although mortality rates were twice as high in those who were hospitalized¹⁸. Patients over 65 years of age and those with flaccid paralysis are at greater risk of death.

Brain MRI shows bilateral, focal T2 hyperintense lesions in the thalamus, basal ganglia, and pons in severely ill patients. Electromyography examination may show axonal neuropathy, probably reflecting anterior horn cell involvement, although in some patients a demyelinating neuropathy is seen as well. The largest review on CSF findings among WNV encephalitis was published by Tyler et al, in 2006. Among 76 WNM encephalitis patients, 60.5% had between 51 to 500 WBC/mm³ (CSF was normal in 5.3% of patients). More than a half of patients had a polymorphonuclear predominance at presentation and 47.4% had a protein level greater than 100 mg/dL. No patient had hypoglycorrhachia¹⁷. WNV infection can be confirmed by detecting WNV-specific IgM in serum or CSF using IgM antibody captures ELISA (MAC-ELISA). MAC-ELISA is more sensitive than RT-PCR in diagnosing neuroinvasive disease.

Dengue virus

Dengue fever is caused by 1 of 4 related RNA virus (Dengue virus serotypes 1 to 4). Dengue is endemic to South and Central America, Southeast Asia, sub-Saharan Africa, Indonesia, Florida, and Texas-Mexico border. The virus is transmitted mainly by *Aedes aegypti* from an infected to uninfected person. Infection with one serotype does not confer immunity to the other virus serotypes.

Dengue fever begins after an incubation period of 2 to 7 days, characterized by fever, headache, myalgia, arthralgia, prostration, abdominal discomfort, and rash. Dengue hemorrhagic fever is the severe form of disease, mainly occurring in persons previously sensitized by infection with a heterologous dengue serotype. Children at are great risk to severe form of disease.

Neurological manifestations can be observed during or after dengue fever and include encephalopathy, encephalitis, mononeuritis multiplex, and Guillain-Barré syndrome. In a recent review, among 47 cases of meningitis and encephalitis in adults and adolescents living in endemic areas, Dengue was the main cause of encephalitis (47%), surpassing HSV-1 (17.6%)¹⁹. Majority of these patients had a normal CSF study.

Dengue diagnosis depends on virus isolation from blood in the early stages or serological tests.

Yellow fever virus

Yellow fever occurs in tropical South America and sub-Saharan Africa. Like dengue, the vector is *A. aegypti* mosquito. Vaccination with yellow fever vaccine has been associated with rare cases of encephalitis in infants within 30 days after immunization. Thus, the vaccine is contra-indicated in infants younger than 4 months of age.

4. Measles

Four CNS syndromes are associated with measles: acute encephalitis, postviral encephalomyelitis, measles inclusion body encephalitis, and subacute sclerosing panencephalitis (SSPE). *Acute encephalitis* is characterized by fever, maculopapular rash, cough, coryza, and Koplik spots. CSF pleocytosis and EEG slowing may be documented. A *postviral encephalomyelitis* may be observed within 2 weeks of the cutaneous rash and present as typical acute encephalitis with altered mental status, seizures, and focal neurological deficits. *Measles inclusion body encephalitis* is a rapidly progressive dementia illness, with behavior changes, myoclonus, focal or generalized seizures, delirium, and coma developing 1 to 6 months after measles exposure in individuals with deficiency in cell-mediated immunity. Patients are afebrile and CSF is mostly normal. The disease progresses to coma and in most cases to death within a few weeks of onset. A small percentage of patients have survived but with severe neurological deficits. *SSPE* is a rare late complication of measles caused by persistent, nonproductive measles virus infection of neurons and glia. The pathogenesis is related to defective measles virus maturation in neural cells. Annual incidence is about 0.1 cases to 5 or 6 per million in nonimmunized populations. Children infected in the first 2 years of life are at greater risk and boys are more affected than girls. Median interval between acute measles infection and SSPE is 8 years, ranging from 2 to 12 years. Early stage is marked by behavioral or personality changes and declining school performance. Myoclonus, seizures, spasticity, choreoathetoid or ballistic movements, ataxia, and chorioretinitis follow in the second stage. Optic atrophy, quadriparesis, autonomic instability, akinetic mutism, and coma are seen in the final stage. Majority of patients follow a progressive course until death in a matter of few years. Nevertheless, long-term survivors with spontaneous stabilization have been described²⁰.

CSF analysis may reveal signs of inflammation and protein increase, but a normal cell count and glucose level may be observed. In SSPE, a marked increase in CSF IgG and high measles virus antibody titers in both serum and CSF can be detected. Earliest MRI findings on SSPE are high-signal intensity on T2-weighted images of gray and subcortical white matter in frontal, parietal, occipital, and temporal lobes and

in periventricular regions. Also, varying degrees of cerebral atrophy and basal ganglia hyperintensity can be seen in some cases. During the second stage of disease, the EEG shows a pattern of generalized slow-wave complexes with a regular periodicity.

It is essential to prevent the disease by massive vaccination. Otherwise, management of patients is based on supportive and symptomatic measures. Some authors have reported successful use of ribavirin to treat subacute measles inclusion body encephalitis. Disease-modifying therapies, such as Isoprinosine, IV immunoglobulin, oral prednisolone, levamisole, amantadine, and methylprednisolone have been used for treatment of SSPE. The immunomodulator isosiplex is one of the few drugs partially effective in SSPE.

5. Rubella

Rubella virus infection is generally a mild illness. Uncommon, late-onset rubella encephalitis may follow congenital rubella or natural childhood rubella. There is a prolonged asymptomatic period followed by the onset of neurological deterioration during the second decade of life. Symptoms include behavioral changes, intellectual decline, ataxia, spasticity, and seizures. Patients with progressive rubella tend to be older than patient with SSPE, have a more protracted clinical course, and lack generalized myoclonus or periodic EEG discharges patterns. Typical course is one of progressive neurological decline, leading to death within 8 years. CSF from affected children contains anti-rubella IgG antibodies. Diffuse brain atrophy may be found in MRI. After widespread use of anti-rubella vaccine, incidence of rubella and rubella-associated acute disseminated encephalomyelitis has declined.

6. Mumps

In unimmunized populations, mumps is a common cause of aseptic meningitis and encephalitis. Around 1% to 5% of patients with parotitis will develop meningitis; the incidence of encephalitis is believed to be smaller²¹. Normally, mumps encephalitis develops 5 days after the onset of parotitis. Postinfectious encephalomyelitis follows an estimated 1 in 6000 cases and develops 7 to 15 days after parotitis. Seizures occur in 30% of patients with CNS involvement. There is a pleocytosis of 25 to 500 WBC/mm³, with lymphocytic predominance. Protein level is normal or moderately elevated. Glucose level is depressed in about 20% to 30% of cases. Most patients will have evidence of virus-specific IgM and IgG antibodies in the serum, with many also having evidence of intratechal antibody synthesis. The treatment is supportive.

7. Arenaviruses

Lymphocytic choriomeningitis virus (LCMV)

LCMV is an arenavirus spread to humans from rodents via contact with urine, feces, or saliva of infected animals.

LCMV usually cause aseptic meningitis, but encephalitis may be diagnosed in about 5% to 34% of serologically confirmed LCMV cases²². Other neurological complications reported are ascending paralysis, bulbar syndromes, Parkinsonism features, and sensorineural hearing loss. CSF cells counts in excess of the 10 to 500 WBC/mm³ is seen. CSF protein is usually elevated and in some cases can be greater than 200 mg/dL. Diagnosis is based on serologic testing of serum samples via immunofixation assays. IgM antibody to LCMV is present in serum, CSF or both during neurological disease.

8. Influenza

Neurologic complications due to influenza are rare but well known among neurologists. Both seasonal and pandemic influenza may complicate with neurologic disease ranging in severity. After influenza pandemic of 1918, a sort of reports ranging from mild fatigue to coma and death and postencephalitic Parkinsonism were published. Nowadays, seizures are the most common neurologic complication, occurring as febrile seizures in children, as exacerbations in epileptic patients, or as a result of other influenza-induced neurologic disease.

Acute encephalitis/encephalopathy is a condition characterized by altered mental status, somnolence, behavioral changes, and coma in some situations²³. CSF may show elevated protein levels or mild pleocytosis, but in majority of case the study is normal. MRI studies show nonspecific T2 signal abnormalities in the splenium, focal or generalized cerebral edema, posterior reversible encephalopathy, and ADEM. Acute necrotizing encephalopathy is a more specific type of severe encephalopathy associated with influenza, first described in Japanese children²⁴. Clinical condition deteriorates rapidly and brain MRI shows bilateral necrosis of thalami and other regions, including the cerebral white matter, cerebellum, and brainstem. It is a severe and sometimes fatal disease. Encephalopathy has also been reported in cases of novel H1N1 influenza pandemic²⁵. Also, influenza infection

may complicate with postinfluenzal encephalitis, occurring 2 to 3 weeks after recovery.

9. Rabies

Rabies is a zoonotic disease with almost 100% of mortality. Reservoirs of infection are bats, wild carnivorous, and nonimmunized dogs. The incubation period is about 1 to 2 months, but may vary from 1 week to several years. There are two major clinical presentations for human rabies, the encephalitic form and the paralytic form²⁶. Rabies should figure in the differential diagnostic list of any encephalitis progressing rapidly to coma, particularly in endemic regions.

Prodromal symptoms of headache, fever, paresthesias, and pain at site of inoculation are followed by acute neurological dysfunction and then coma and death. Cases in which hyperactivity dominates have also been called furious rabies (*encephalitic form*). Negri bodies and inflammatory changes are maximal in the brainstem and limbic system. Up to 80% of these patients exhibit hydrophobia or aerophobia: spasms of pharyngeal and nuchal muscles lasting from 1 to 5 minutes, triggered by swallow attempts or tactile, auditory, visual, and olfactory stimuli²⁶. Agitation, hallucination, autonomic hyperactivity, and seizures occur in posterior phase. Body temperature may reach 40° C. The *paralytic form* accounts for 20% of patients. It is characterized by paresthesias, weakness, and flaccid paralysis in the bitten extremity progressing to quadriplegia. This form of human rabies may be confounded with Guillain-Barré syndrome.

CSF analysis can range from completely normal to mild pleocytosis with modestly elevated protein content. A definitive diagnosis prior to autopsy can be difficult, but is based on finding viral antigens. An ELISA to detect rabies antigen in the CSF has a documented sensitivity and specificity of 76% and 100%, respectively²⁷. Today, there is no treatment for human rabies, but recovery has been reported in only a few patients who were infected with bat rabies virus variants.

References

1. Steiner I, Budka H, Chaudhuri A, et al. Viral encephalitis: a review of diagnostic methods and guidelines for management. *Eur J Neurol* 2005;12:331-343.
2. Whithley RJ. Herpes virus encephalitis: adolescents and adults. *Antiviral Res* 2006;71:141-148.
3. Roos K. Viral encephalitis. In: Roos K (Ed). *Principles of neurologic infectious diseases*. New York, NY: McGraw-Hill;2005:65-76.
4. Glaser CA, Honarmand S, Anderson LJ, et al. Beyond viruses: clinical profiles and etiologies associated with encephalitis. *Clin Infect Dis* 2006;43:1565-1577.
5. Lakeman FD, Whitley, RJ. Diagnosis of herpes simplex encephalitis: application of PCR to CSF from brain-biopsied patients and correlation with disease. *J Infect Dis* 1995;171:857-863.
6. Gilden DH, Kleinschmidt-DeMasters BK, Laguardia JJ, et al. Neurologic complications of the reactivation of varicella-zoster virus. *N Engl J Med* 2000;343:632-645.
7. Burgoon MP, Hammack BN, Owens, GP, et al. Oligoclonal immunoglobulins in CSF during varicella-zoster virus (VZV) vasculopathy are directed against VZV. *Ann Neurol* 2003;54:459-463.
8. Nagel MA, Forghani B, Mahalingam R, et al. The value of detecting anti-VZV IgG antibody in CSF to diagnose VZV vasculopathy. *Neurology* 2007;68:1069-1073.
9. Mamidi A, DeSimone JA, Pomerantz RJ. Central nervous system infections in individuals with HIV-1 infection. *J Neurovirol*, 2002;8:158-164.

10. Griffiths P. CMV infections of the central nervous system. *Herpes* 2004;11(Suppl 2):S95-S104.
11. Doja A, Bitnum A, Jones EL, et al. Pediatric EBV-associated encephalitis: 10-year review. *J Child Neurol* 2006;21:385-391.
12. Whitley RJ, Chien LT, Dolin R, et al. Adenine arabinoside therapy of herpes zoster in the immunosuppressed. NIAID collaborative antiviral study. *N Engl J Med* 1976;294:1193-1199.
13. McCullers JA, Lakeman FD, Whitley RJ. Human herpesvirus 6 is associated with focal encephalitis. *Clin Infect Dis* 1995;21:571-576.
14. Seeley WW, Marty FM, Holmes TM, et al. Post-transplant acute limbic encephalitis. Clinical features and relationship to HHV-6. *Neurology* 2007;69:156-160.
15. Koskiemi M, Rantalaiho T, Piiparinen H, et al. Infectious of the central nervous system of suspected viral origin: a collaborative study from Finland. *J Neurovirol* 2001;7:400-408.
16. Wang SM, Lei HY, Su LY, et al. CSF cytokines in enterovirus 71 brain stem encephalitis and echovirus meningitis infections of varying severity. *Clin Microbiol Infect* 2007;13:677-682.
17. Tyler KL, Pape J, Goody RJ, et al. CSF findings in 250 patients with serologically confirmed West Nile virus meningitis and encephalitis. *Neurology* 2006;66:361-365.
18. Davis LE, DeBiasi R, Goade DE, et al. West Nile virus neuroinvasive disease. *Ann Neurol* 2006;60:286-300.
19. Soares CN, Cabral-Castro MJ, Peralta JM, et al. Review of the etiologies of viral meningitis and encephalitis in a dengue endemic region. *J Neurol Sci* 2011;303:75-79.
20. Buchanan R, Bonthius DJ. Measles virus and associated central nervous system sequelae. *Semin Pediatr Neurol* 2012;19:107-114.
21. Nagai T, Okafuji T, Miyazaki C, et al. A comparative study of the incidence of aseptic meningitis in symptomatic natural mumps patients and monovalent mumps vaccine recipients in Japan. *Vaccine* 2007;25:2742-2747.
22. Barton LL, Hyndman NJ. Lymphocytic choriomeningitis virus: reemerging central nervous system pathogen. *Pediatrics* 2000;105:35.
23. Ekstrand JJ. Neurologic complications of influenza. *Semin Pediatr Neurol* 2012;19:96-100.
24. Yoshikawa H, Yamazaki S, Watanabe T, et al. Study of influenza-associated encephalitis/encephalopathy in children during the 1997 to 2001 influenza seasons. *J Child Neurol* 2001;16:885-890.
25. Yildizdas D, Kendirli T, Arslanköylü AE, et al. Neurological complications of pandemic influenza (H1N1) in children. *Eur J Pediatr* 2011;170:779-788.
26. Hemachudha T, Ugolini G, Wacharapluesadee S, et al. Human rabies: neuropathogenesis, diagnosis, and management. *Lancet Neurol* 2013;12:498-513.
27. Vasanth JP, Madhusudana SA, Abhilash KV, et al. Development and evaluation of a ELISA for rapid diagnosis of rabies in humans and animals. *Indian J Pathol Microbiol* 2004;47:574-578.