

EARLY DIAGNOSIS OF RELAPSE IN BORDERLINE LEPROSY: TWO CASE REPORTS

Maria Luiza Figueiredo Braga BRANDÃO(1), Cíntia Maria Oliveira LIMA(1), Juan PIÑEIRO-MACEIRA(1), Alice MIRANDA(2) & M.Leide W. de OLIVEIRA(1)

SUMMARY

Two cases of relapse in borderline leprosy were reported. Despite the late-reversal, reaction-like feature, the suspicion of relapse in both was based on persistent and slow-developing skin lesions and an absence of acute neuritis or reaction during one year of follow-up. The authors have considered this possible occurrence in lepromatous borderline-treated patients after their immune cellular restoration and defend that not all Type 1 reactions would be an inflammatory answer to persistent *Mycobacterium leprae*, but that they could be. Therefore, a relapse diagnosis could be applied and it is more advisable, as one year of Multi-Drug Therapy (MDT) is less dangerous and more efficient for these cases than one year of corticosteroids.

KEYWORDS: Leprosy; Relapse; Borderline leprosy.

INTRODUCTION

The proven efficiency of WHO Multi-drug therapy has been given low importance in recent decades due to low relapse². The diagnosis of late multibacillary leprosy (LL, BL) is not difficult, neither clinically or in the laboratory, due to the presence of acid fast bacilli⁶. However, the diagnosis of leprosy relapses on the borderline spectrum (BT, BB) in field conditions is complex and has taught leprologists many lessons, as many of these cases may present features similar to reversal reaction at the onset. For an illness like leprosy, with multiple clinical presentations without definitive knowledge of its immunopathologic aspects, nothing is more concrete for learning opportunities than the clinical disease manifestation in man as illustrated in the following cases.

CASE REPORTS

Two cases of borderline lepromatous leprosy were diagnosed, treated and followed up after being released by cure in the University Hospital of the Federal University of Rio de Janeiro (UFRJ). Both had clinical and histopathological confirmation and received MDT for MB leprosy. Case 1 returned only once during the 5-year period after having been released and case 2 was under surveillance while presenting a Type 1 Reversal Reaction (RR) during seven years.

Case 1: 31-year-old male, diagnosed with BL leprosy in 1998 and treated regularly with 12 doses of MDT and released without clinical lesions and grade 0 physical disability in 1999. Returned once with one episode of RR, two years after being released, without recurrence.

In 2006, returned with macular lesions diagnosed as macular RR. As the lesion became infiltrated without any other symptoms and signs of reaction, there was a suspicion of relapse (Fig. 1). Serology and slit skin smears were negative, but biopsy revealed a slight infiltration of lymphocytes and histiocytes around blood vessels, and fragmented acid fast bacilli inside nerves (Fig. 2). Despite doubts concerning the diagnosis of RR or relapse, the decision was to re-treat this patient since no clinical sign of reaction was observed. After 12 doses of MDT all lesions disappeared and the patient has not shown any reaction since his release in the beginning of 2007.

Case 2: 66-year-old male, diagnosed with BL leprosy in 2001, regularly treated with 12 doses of MDT and released presenting RR and grade 1 physical disability. Many courses of steroids were prescribed during seven years, always initiating with 1 mg/kg. The persistence of RR lesions and worsening of paresthesia in the ulnar nerve prompted the relapse investigation, with skin smears showing negative results and histopathology showing one acid-fast bacillus and without any granulomatous process, anti-PGL1 serology 2+/4. The decision was to maintain close observation of the patient, without corticosteroid, during the full year of 2009. After 10 months the lesions became more infiltrated (Fig. 3-4), the paresthesia symptoms increased, serology also increased to 3+++/4; PCR sequencing of *ML* was +, but skin smears were continuously negative. The histopathological examination showed perineural epithelioid granulomas (Fig. 5). The patient was diagnosed with early borderline relapse, and a new MDT/MB regimen was then started (Fig. 6).

(1) University Hospital/UFRJ, Dermatology and Anatomopathology Services. Rio de Janeiro, RJ, Brazil.

(2) Lab. Hansen's Disease, FIOCRUZ. Av. Brasil 4365. Mangueiras, 21040-360 Rio de Janeiro, RJ, Brazil.

Correspondence to: Maria Luiza Figueiredo Braga Brandão. Serviço de Dermatologia. Rua Prof. Rodolpho Paulo Rocco 255/5 andar, Ilha do Fundão, 21941-913 Rio de Janeiro, RJ, Brasil.
E-mail: malu_braga@yahoo.com.br

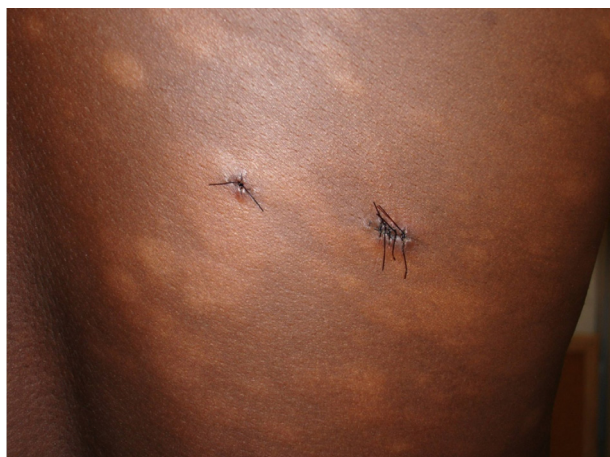

Fig. 1 - Disseminated patches and paresthesia.

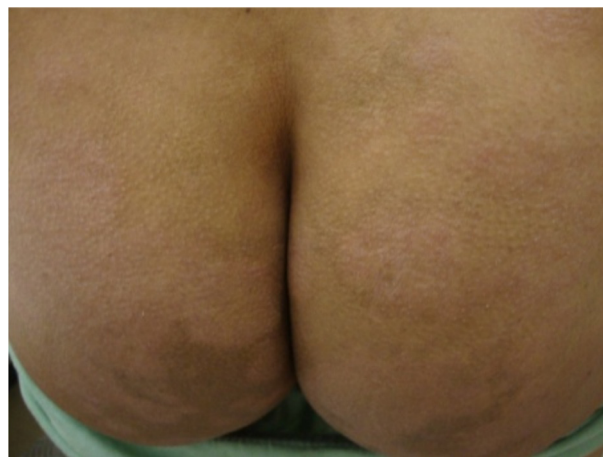

Fig. 4 - Patches and paresthesia in the buttocks.

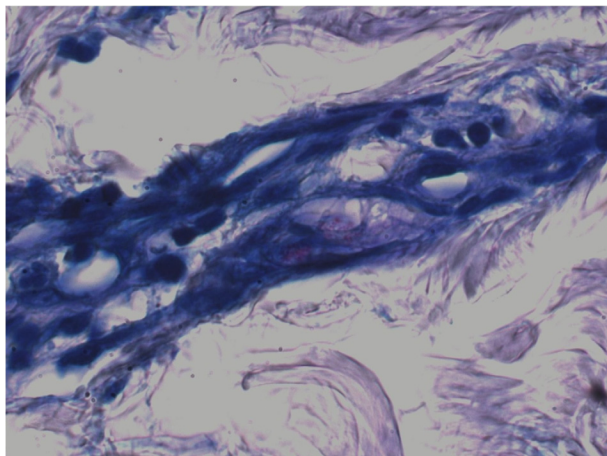


Fig. 2 - Wade X1000-AFB fragmented within nerve bundles.

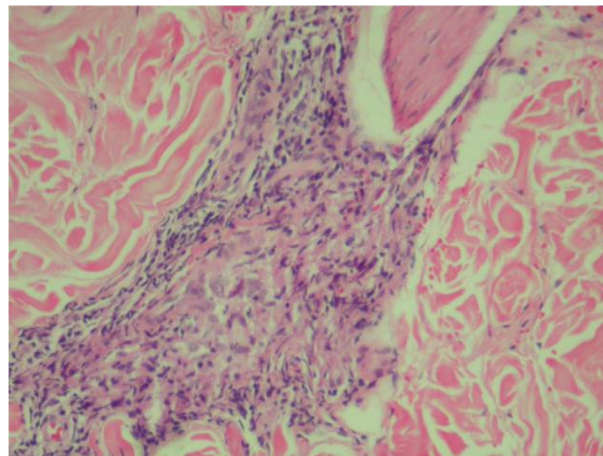


Fig. 5 - HEX 400X - Periadnexal granulomatous infiltrate.

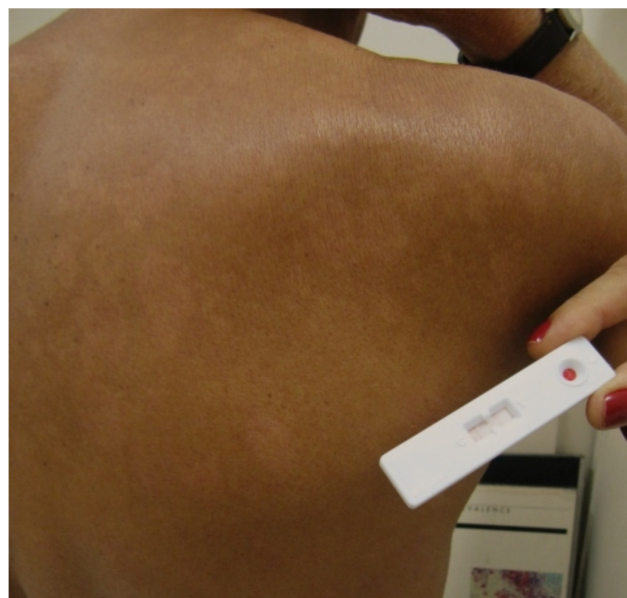

Fig. 3 - Patches and paresthesia in the trunk and positive serology test (AntiPGL-1) in 2009.

DISCUSSION

The clinical cure of leprosy has been defined as the normalization which considers that six fixed doses cure paucibacillary cases and 12 doses cure multibacillary cases. These criteria were based on the distinction between the infectious disease due to *M. leprae* and the secondary inflammatory disease caused by host response to intracellular parasitism. The current treatment regimes are strong enough to kill *M. leprae* and stop disease transmission. However, signs and symptoms persist in approximately 30% of cases for an indeterminate period⁴. It is well known that in treated leprosy patients, some persistent mycobacteria remain in latent form^{1,5,8,10}. Whether this fact can be related to late reactions is still a controversial issue³.

According to OPROMOLLA, 2001⁷, Type 1 reaction is related to persistent *Mycobacterium leprae* multiplication "it is not logical that similar clinical manifestations known to have happened before, during or after treatment should be considered so differently". WATERS, 2001, also considers this possibility, especially in BL-treated patients after immune cellular restoration^{9,10}.

The authors of this report state that not all Type 1 reactions are an

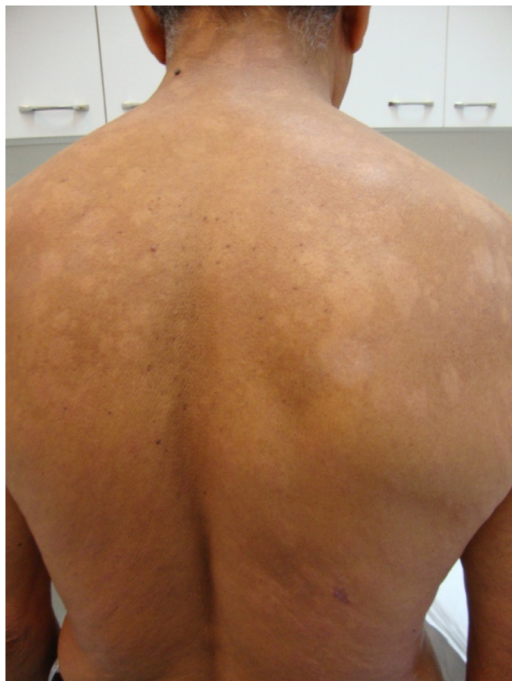

Fig. 6 - Skin lesion improvement seven months after the MDT-Biopsy .

inflammatory answer to persistent *Mycobacterium leprae*, but that they could be.

The two cases presented here had BL leprosy in common, and also the reappearance of BT leprosy after different evolutions: case one was cured and went five years without skin and nerve lesions while case 2 maintained skin lesions for the whole surveillance period. After the suspicion of relapse, both showed persistent and slow-developing skin lesions and an absence of acute neuritis or any acute reaction during one year of follow-up.

The careful histopathologic examination found one AFB in case 1 (Fig. 2). How can we explain multiple fragmented bacillus after such a long period since being cured of borderline leprosy?

In case 2, the strong Anti-PGL1 serology also could not be explained seven years after treatment and a solid AFB was found in an histopathological exam. Three experienced pathologists examined these samples.

Neither patient had had a second leprosy case in the family, despite the fact that both patients live in a region endemic for leprosy. Furthermore, in both patients the second course of MDT/MB was successful, which reinforces that in some late RR-like episodes with slow evolution, a leprosy relapse diagnosis could be applied. This is even more advisable because one year of MDT could be less dangerous and more efficient than one year of corticosteroids.

RESUMO

Diagnóstico precoce de recidiva em hanseníase dimorfa: apresentação de dois casos

São apresentados dois casos de recidiva de hanseníase *borderline*. Apesar das características de reação reversa tardia, a suspeita de recidiva foi baseada no desenvolvimento insidioso e persistente de lesões cutâneas sem reação e neurite agudas, durante um ano de seguimento. Os autores consideram a possibilidade de recidiva em pacientes *borderline* virchowinano tratados, pela restauração da imunidade celular e postulam que embora nem toda reação tipo 1 seja devida a presença de *M. leprae* persistentes, isso também pode ocorrer. Assim, o diagnóstico de recidiva foi considerado ressaltando-se que um ano de poliquimioterapia oferece menos danos e pode ser mais eficiente nesses casos, que um ano de corticosteróides.

REFERENCES

1. Balagon MF, Cellona RV, Cruz E, Burgos JA, Abalos RM, Walsh GP, *et al*. Long-term relapse risk of multibacillary leprosy after completion of 2 years of multiple drug therapy (WHO-MDT) in Cebu, Philippines. *Am J Trop Med Hyg.* 2009;81:895-9.
2. Diniz LM, Moreira MV, Puppim MA, de Oliveira ML. Estudo retrospectivo de recidiva da hanseníase no Estado do Espírito Santo. *Rev Soc Bras Med Trop.* 2009;42:420-4.
3. Gondim FA, Thomas FP, Oliveira GR, Pimentel LH, Bastos BP, Costa CM. On the spectrum of leprosy neuropathies: multifocal inflammatory neuropathy heralding leprosy relapse. *Neuromuscul Disord.* 2009;19:711-3.
4. Grossi MAF, Leboeuf MAA, Reyna MGB, Magalhães ESB, Lana FCF, Bloch KV. Caracterização da demanda pós-alta de hanseníase em serviços de saúde de Minas Gerais, Brasil: contribuição para a sistematização da assistência. *Cad Saúde Colet.* 2009;17:13-24
5. Jing Z, Zhang R, Zhou D, Chen J. Twenty five years follow up of MB leprosy patients retreated with a modified MDT regimen after a full course of dapsone mono-therapy. *Lepr Rev.* 2009;80:170-6.
6. Kaimal S, Thappa DM. Relapse in leprosy. *Indian J Dermatol Venereol Leprol.* 2009;75:126-35.
7. Opromolla DVA. As reações tipo I. *Hansenol Int.* 2001;26:89-90.
8. Pattyn S, Grillone S. Relapse rates and a 10-year follow-up of a 6-week quadruple drug regimen for multibacillary leprosy. *Lepr Rev.* 2002;73:245-7.
9. Waters MFR. Distinguishing between relapse and late reversal reaction in multidrug (MDT)-treated BT leprosy. *Lepr Rev.* 2001;72:250-3.
10. Waters MFR. Relapse following various types of multidrug therapy in multibacillary leprosy. *Lepr Rev.* 1995;66:1-9.

Received: 10 August 2011

Accepted: 20 September 2011